

Ocular Inflammatory Diseases

Mycotic Uveitis Organisms

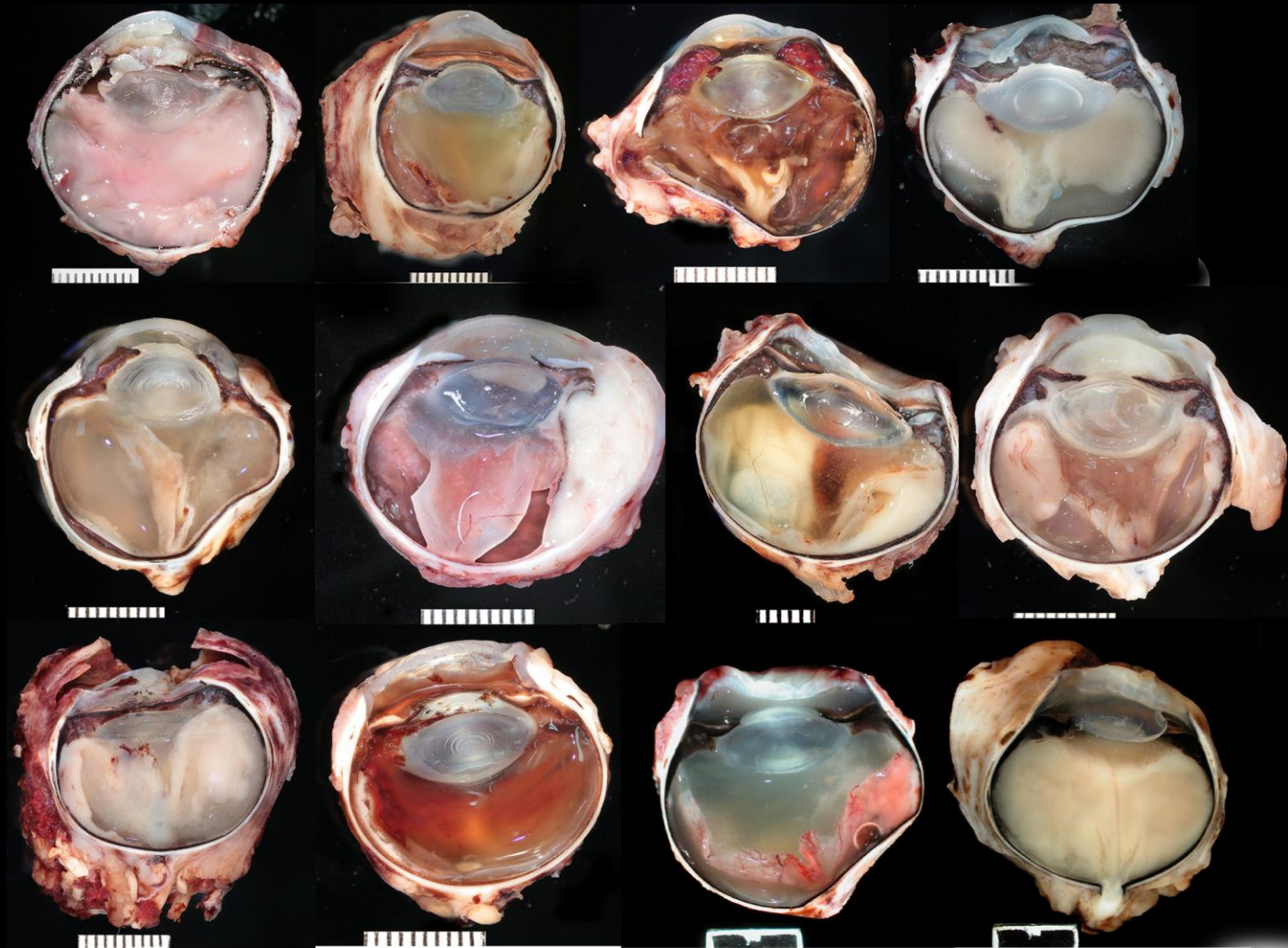
- **Blastomycosis**
- Cryptococcosis
- Coccidioidomycosis
- Histoplasmosis
- Protothecosis
- Aspergillosis

Blastomycosis

273 cases in dogs, 15 cases in cats

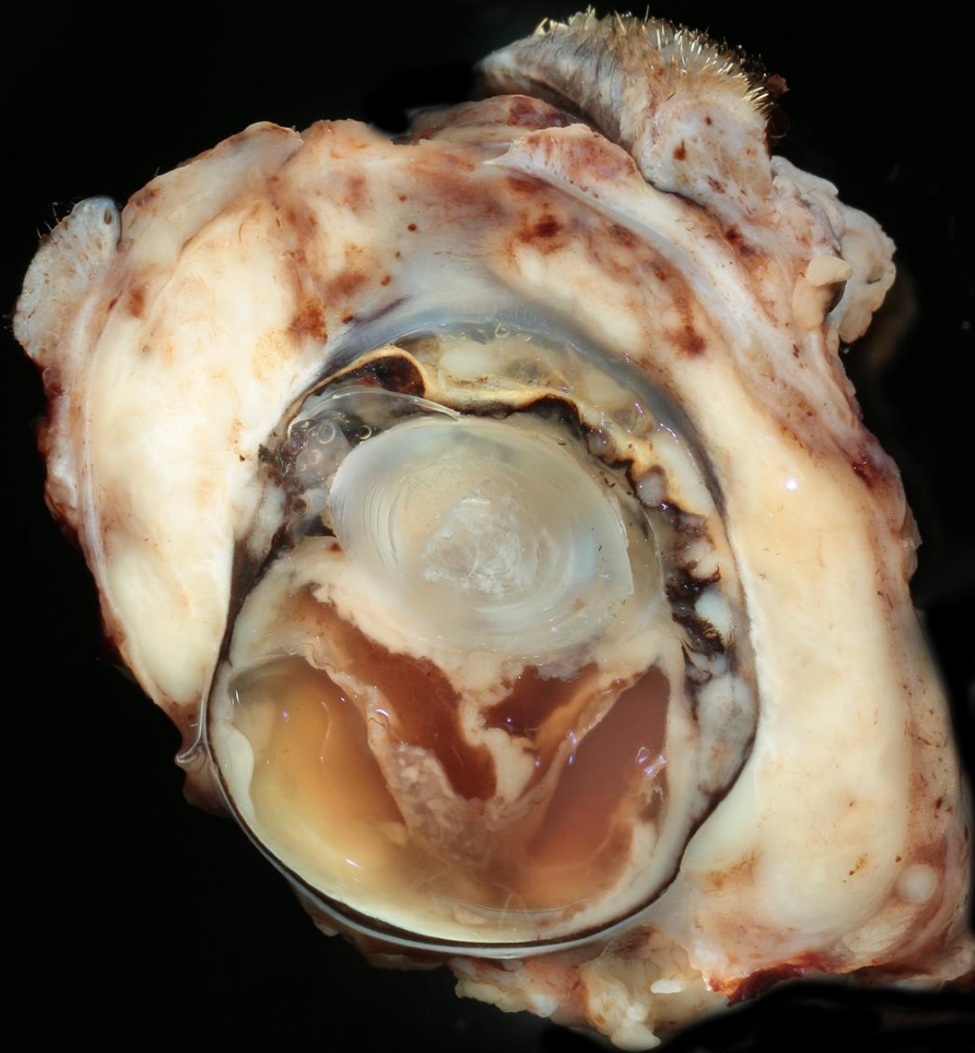
- *Blastomyces dermatitidis*
- Dogs more than cats
- Goldens: 15% (6.8%) / Labs: 15% (9.8%) / Border Collies: 10% (0.8%)
- 51% male and 41% Female
- Average age = 3yo
- Mississippi River valley
 - Cincinnati – 10%
 - Wheeling – 7.5 %
 - Nashville – 5%
- Very local hotbeds
- Soil fungus spread through inhalation from the soil
- Encapsulated with broad-based budding

Blastomycosis



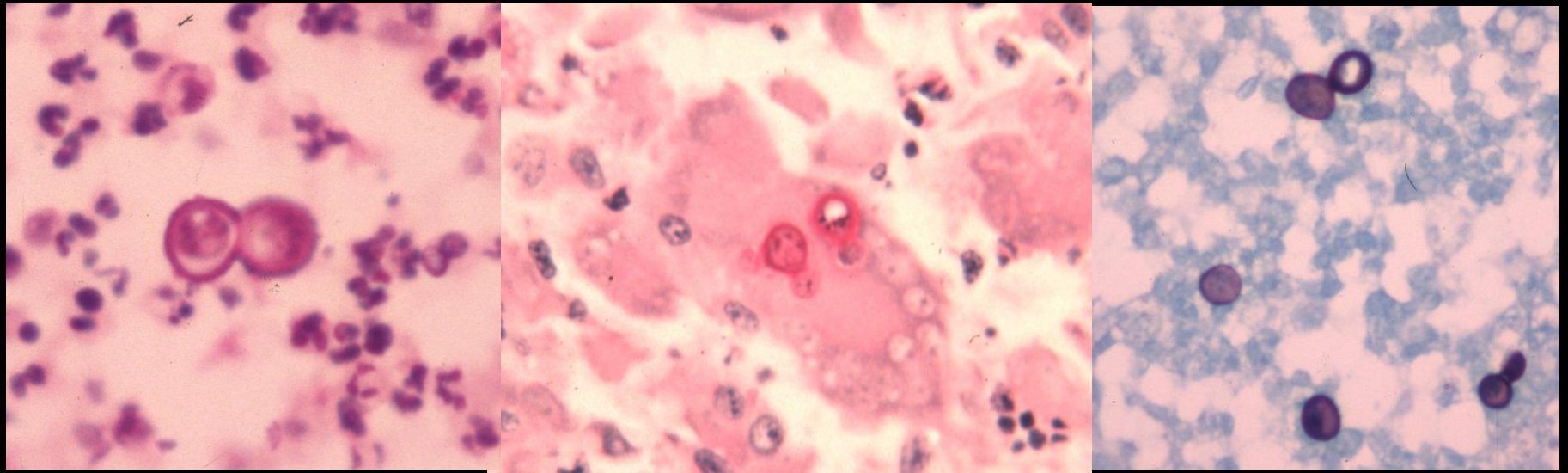
Canine Blastomycosis

Feline Blastomycosis



Feline





Blastomycosis

Mycotic Uveitis Organisms

- Blastomycosis
- **Cryptococcosis**
- Coccidioidomycosis
- Histoplasmosis
- Protothecosis
- Aspergillosis

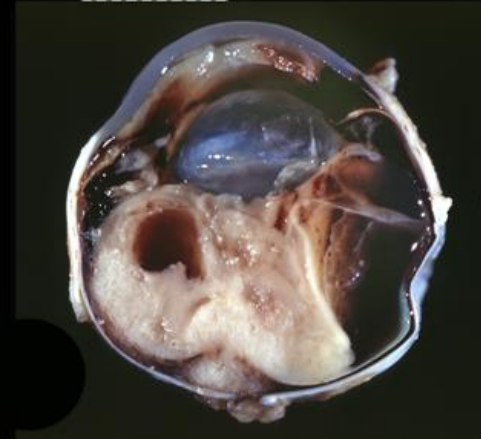
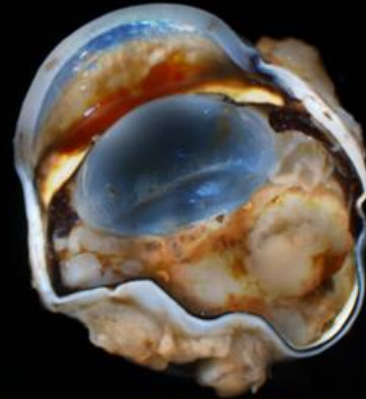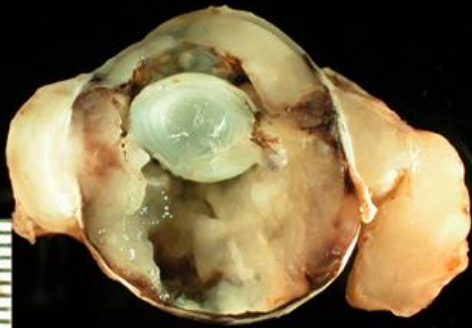
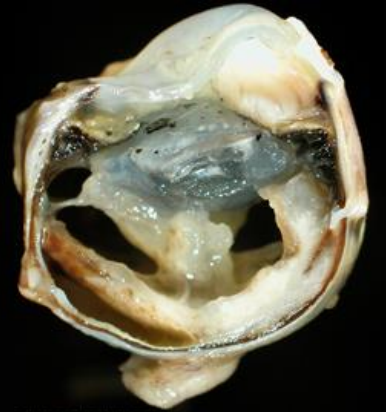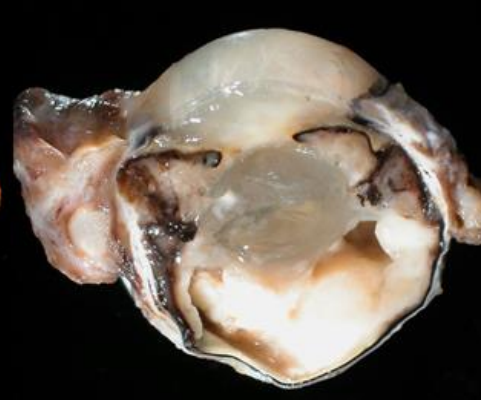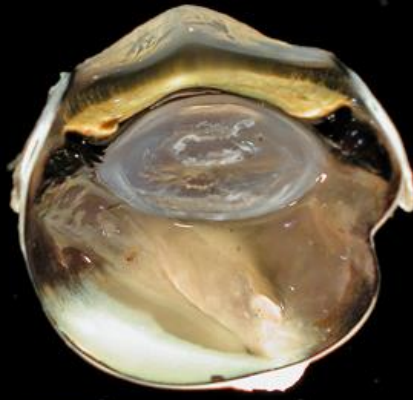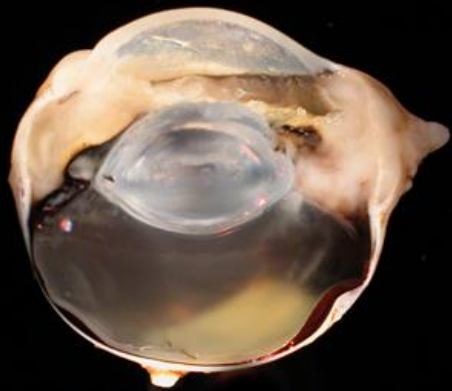Cryptococcosis

13 cases in dogs (3 Cocker Spanials)

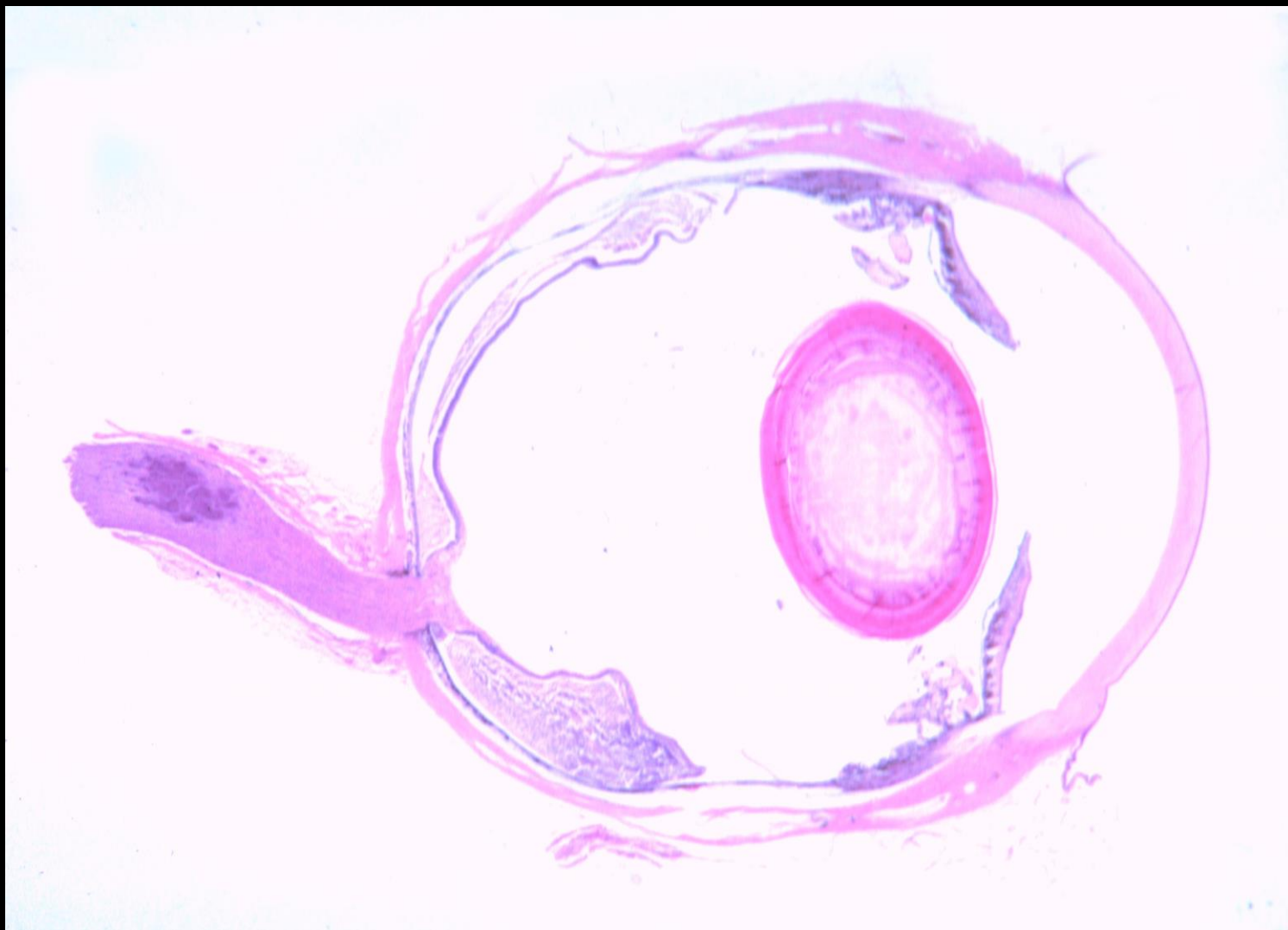
29 cases in cats

- *Cryptococcus neoformans*
- Spread from soil rich with pigeon droppings
- Cats more than dogs
- 7 to 10 micron poorly staining cell body surrounded by mucinous capsule

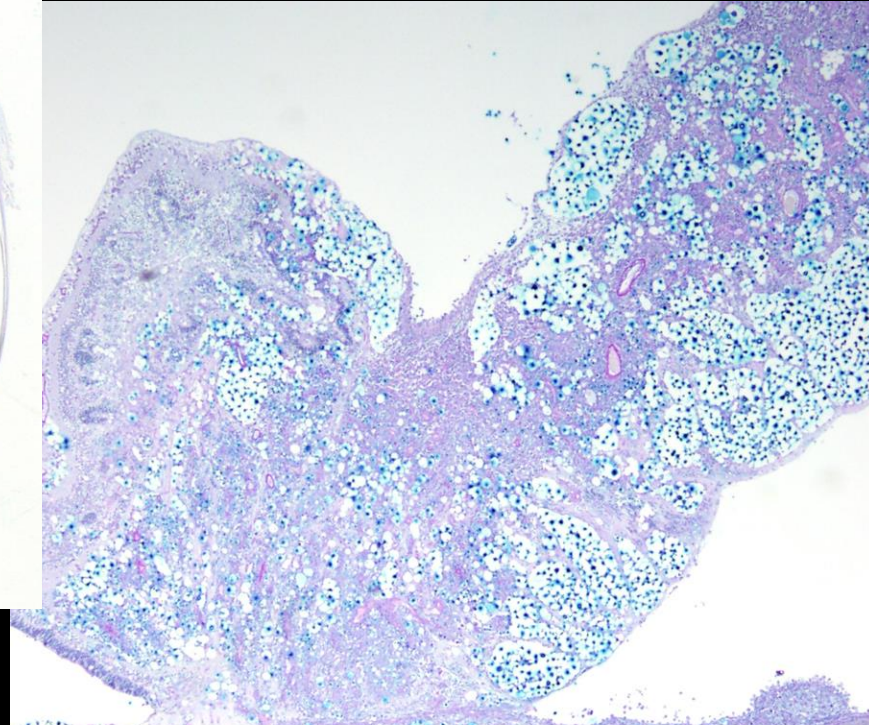
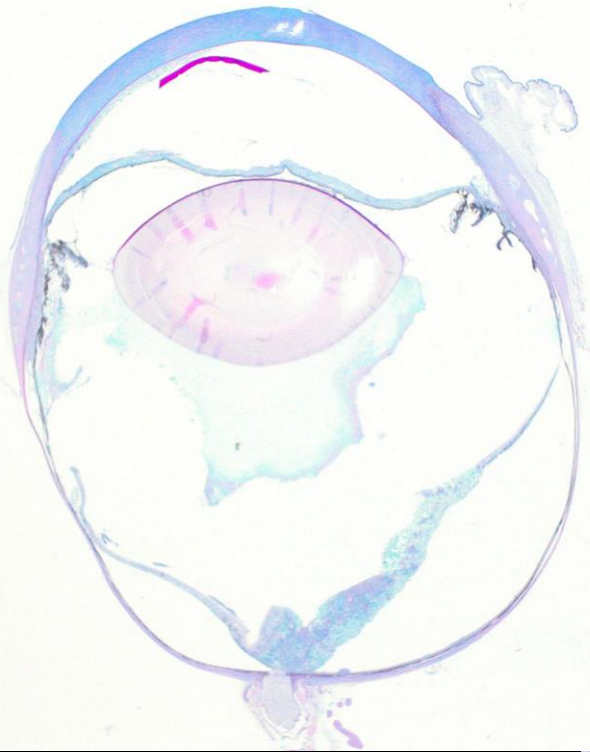
Feline Cryptococcosis



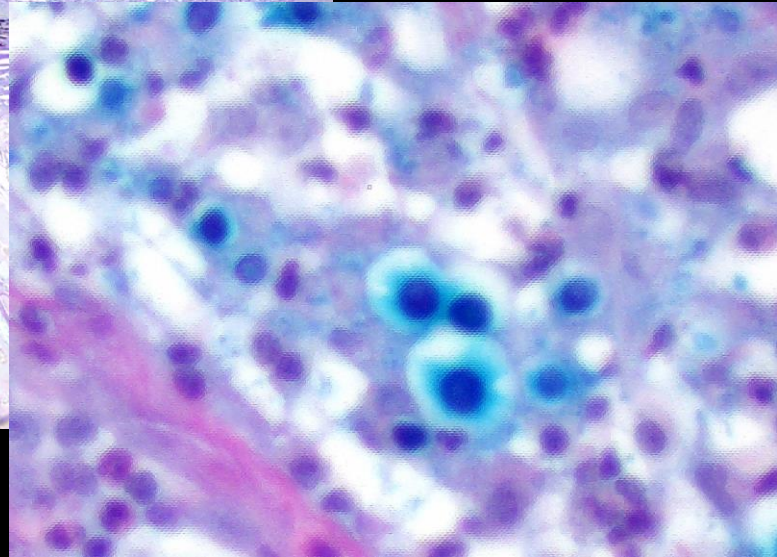
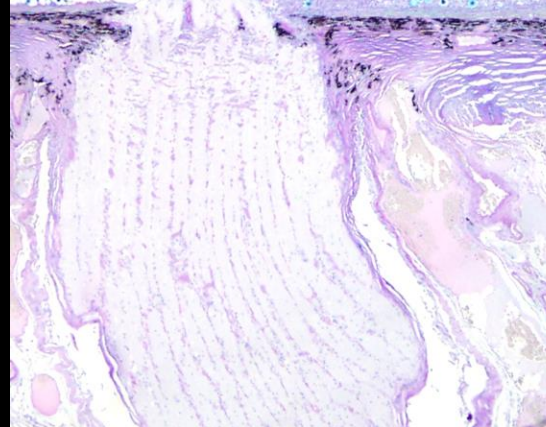
Feline Cryptococcosis



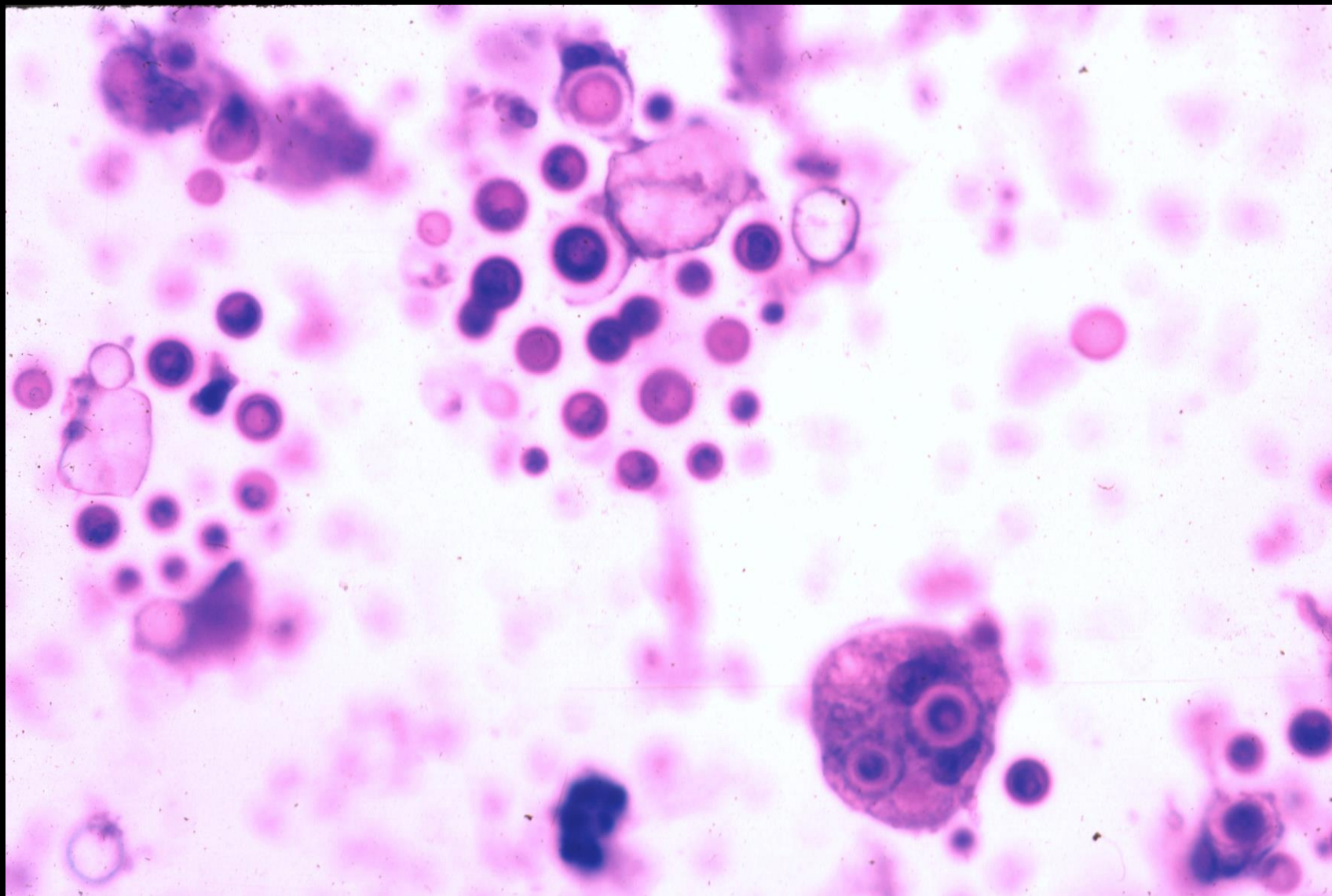
Cryptococcosis



Alcian Blue PAS

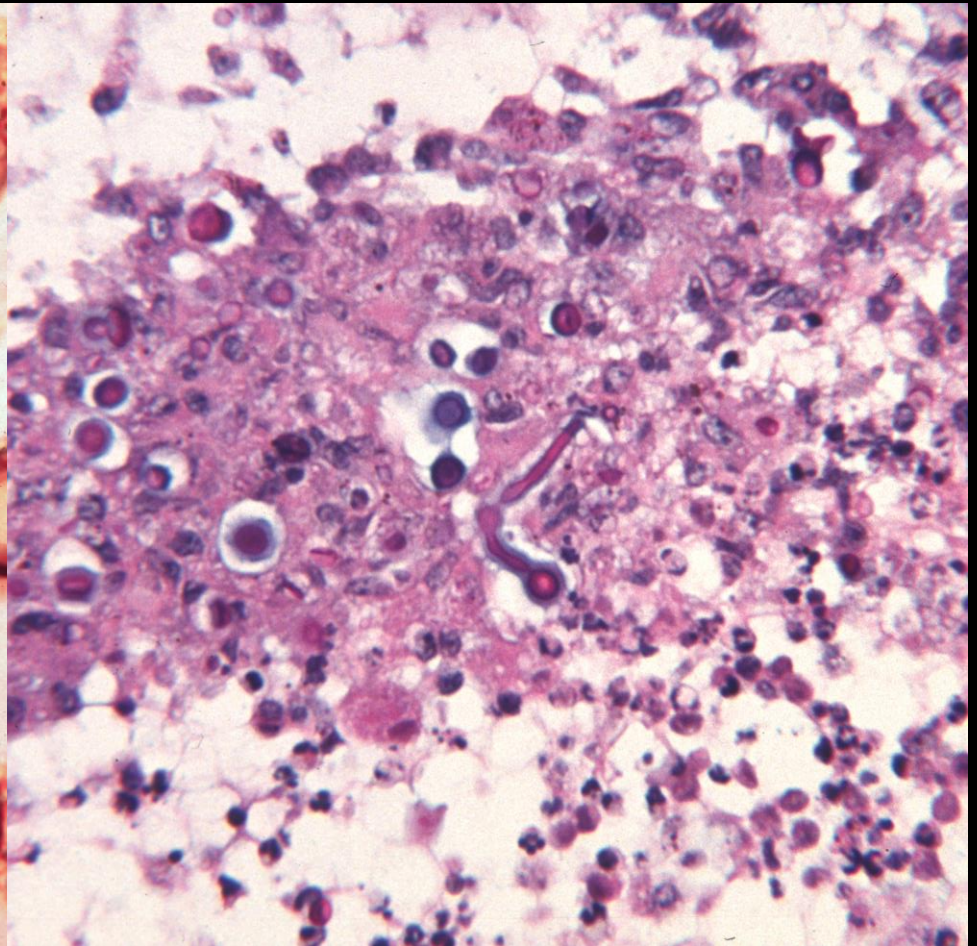
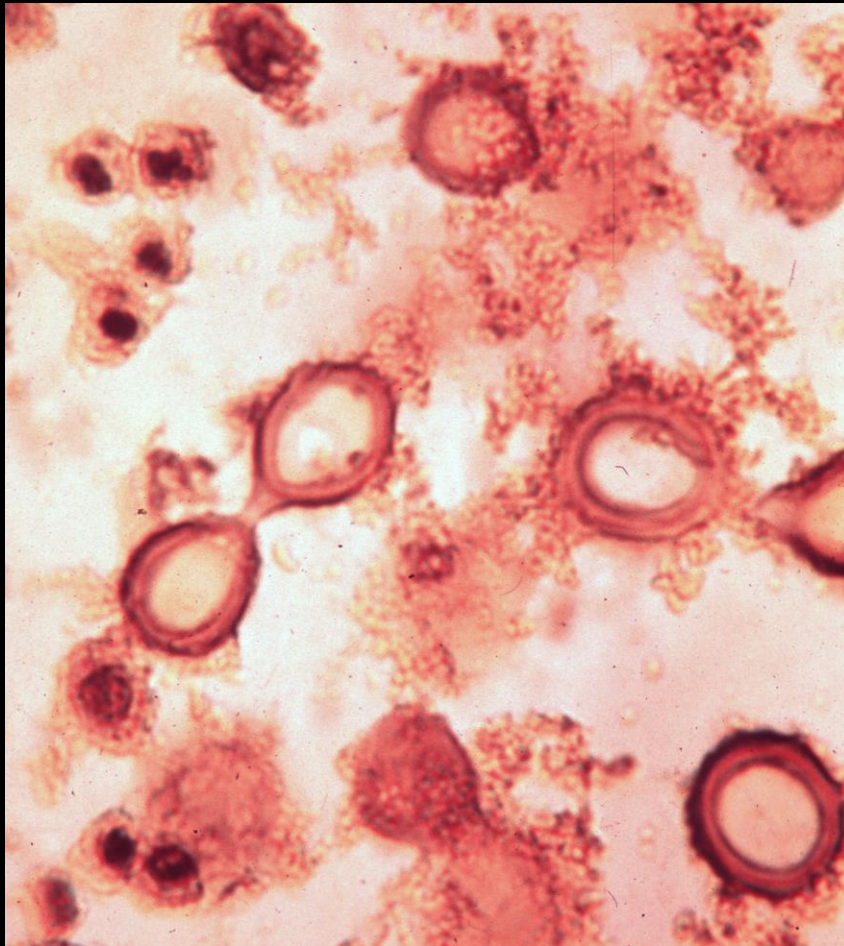


Feline Cryptococcosis



Cryptococcosis

Canine



Mycotic Uveitis Organisms

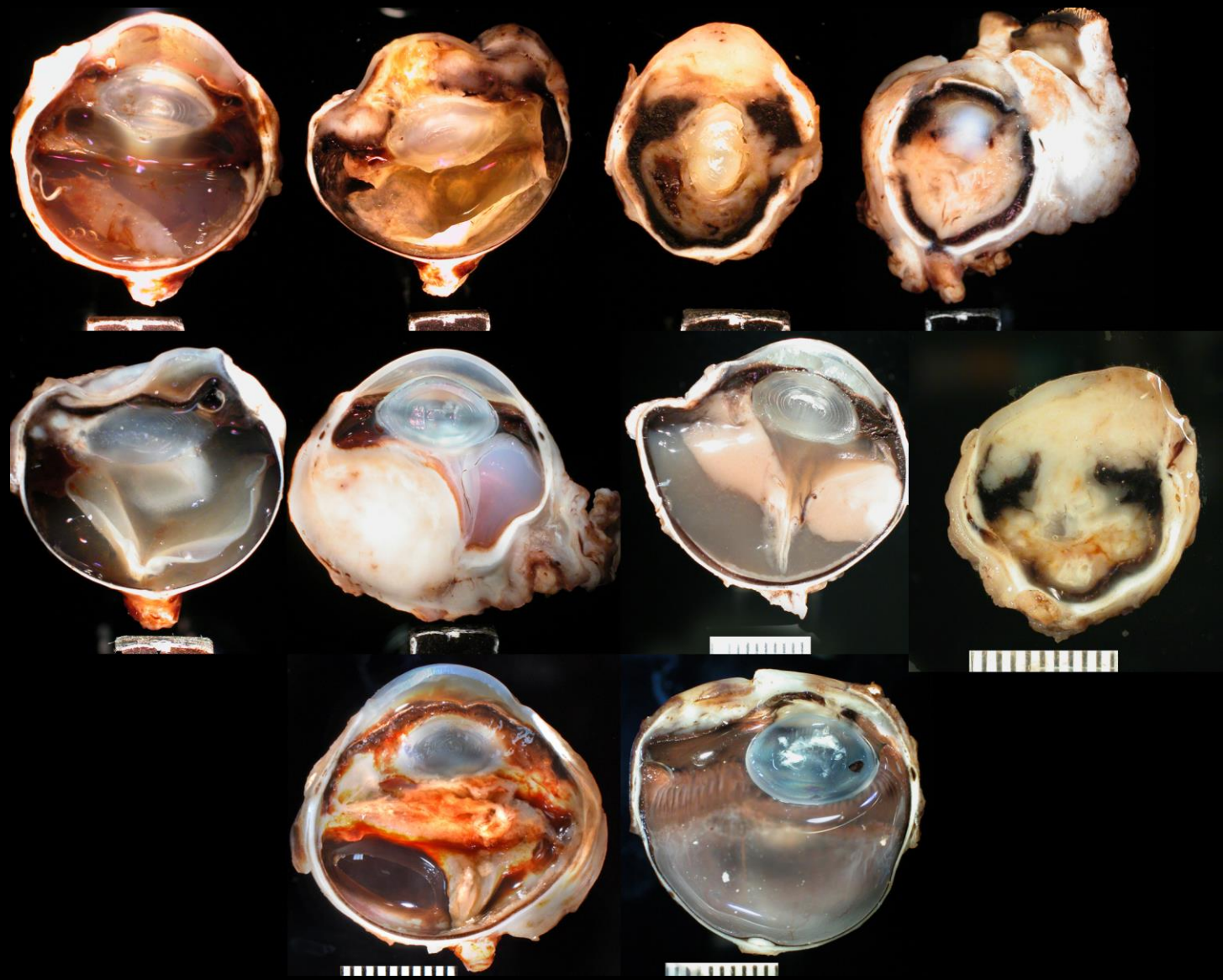
- Blastomycosis
- Cryptococcosis
- **Coccidioidomycosis**
- Histoplasmosis
- Protothecosis
- Aspergillosis

Coccidioidomycosis

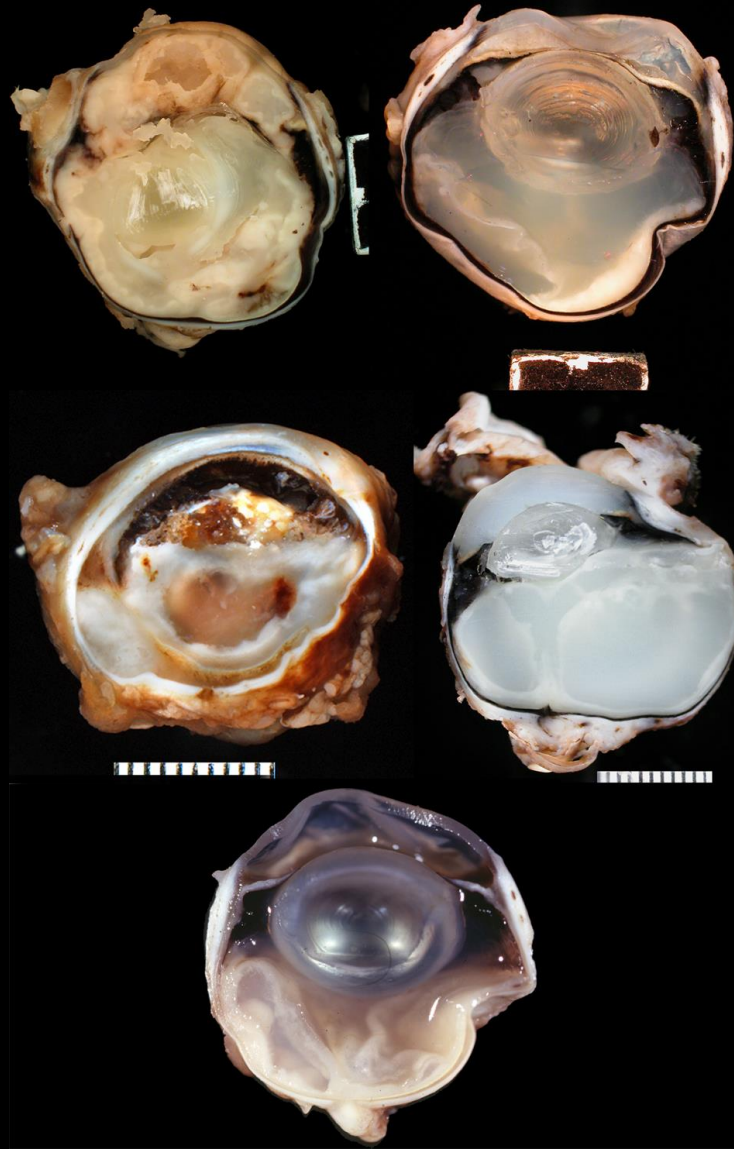
44 cases in dogs (no particular breed)

11 cases in cats

- *Coccidioides immitis*
- Soil organism from Southwestern desert
- Infects many species
- Organism easier to find in cats than dogs
- 20 to 40 micron spherule with enclosed endospores
- Does not have a budding form

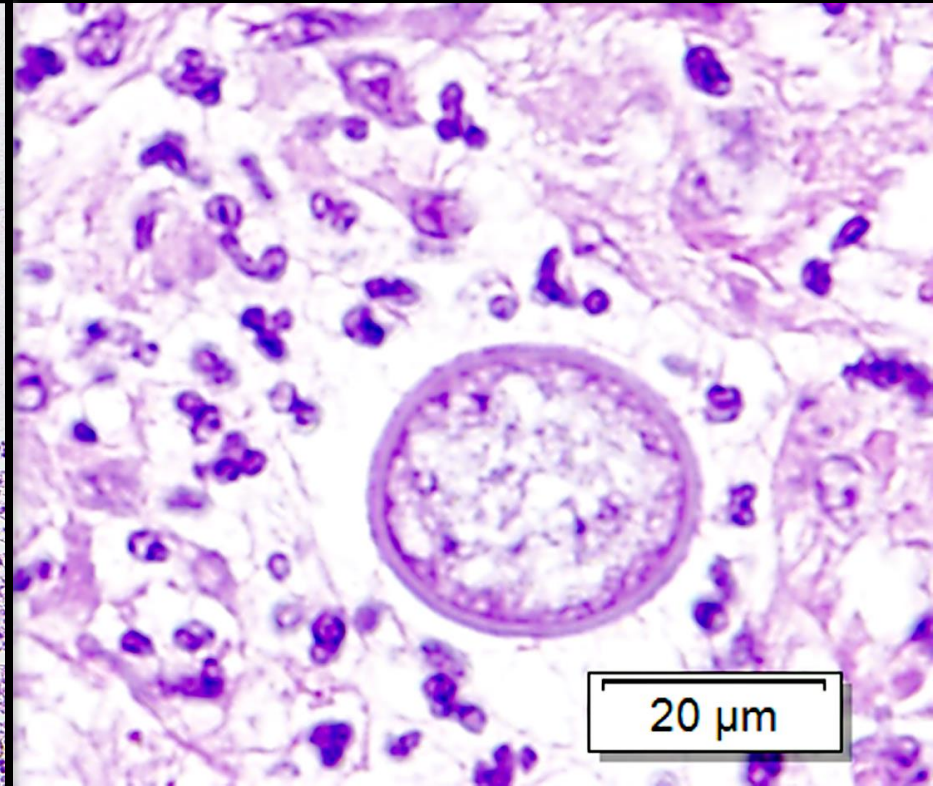
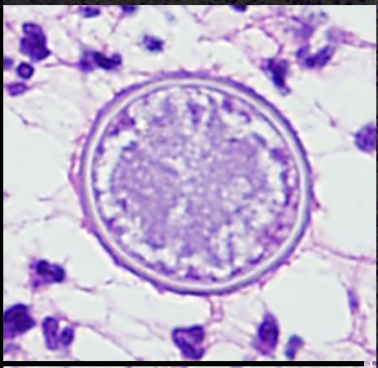
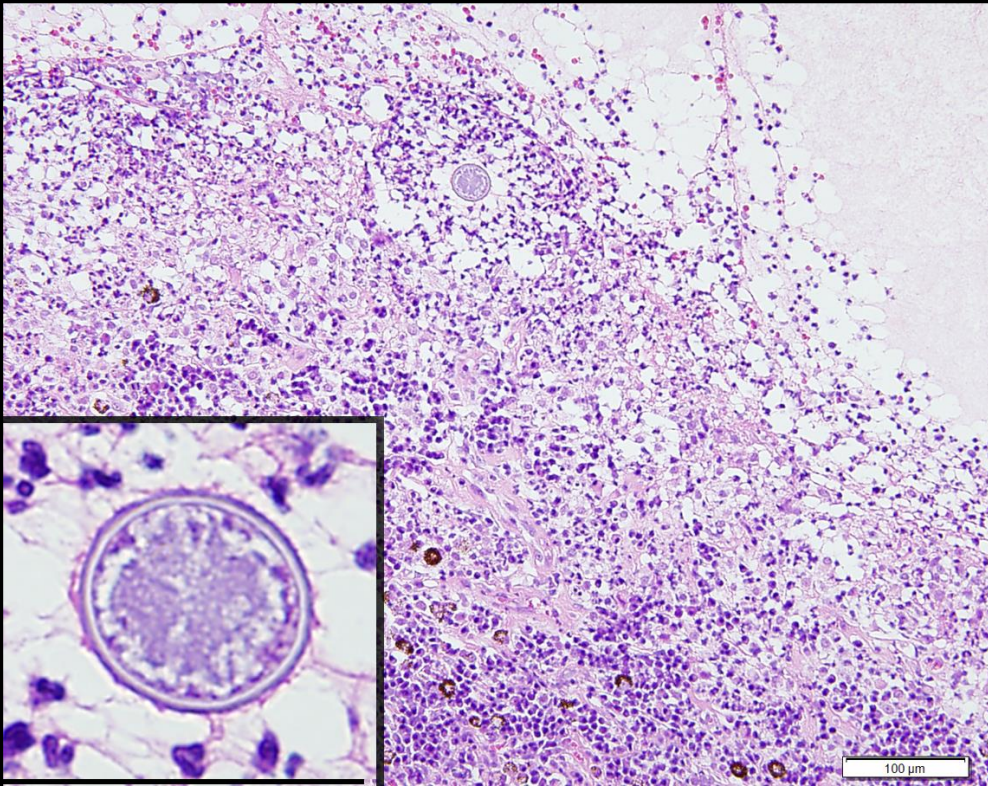


Canine Coccidioidomycosis



Feline Coccidioidomycosis

Coccidioidomycosis



Mycotic Uveitis Organisms

- Blastomycosis
- Cryptococcosis
- Coccidioidomycosis
- **Histoplasmosis**
- Protothecosis
- Aspergillosis

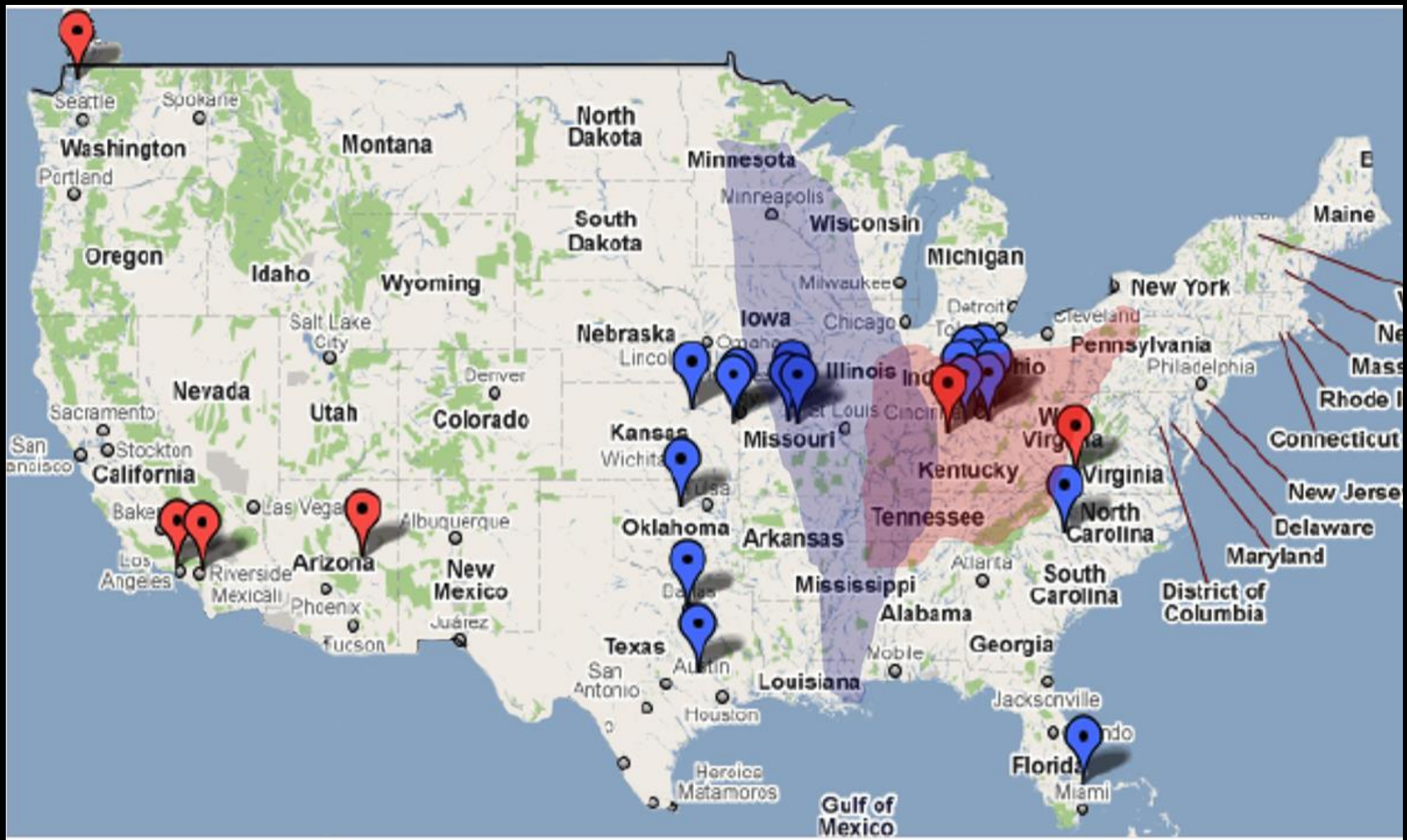Histoplasmosis

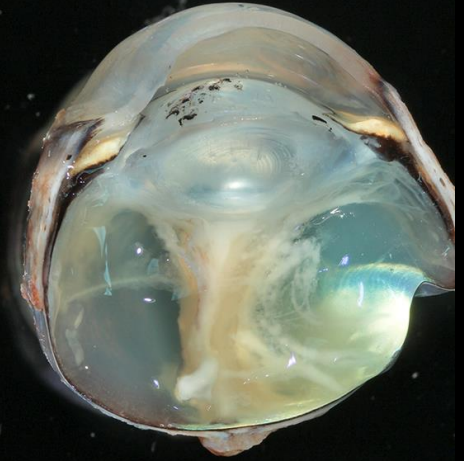
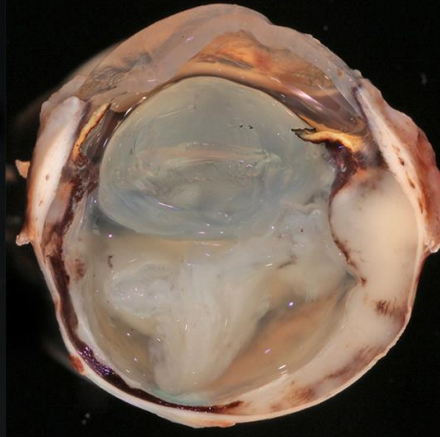
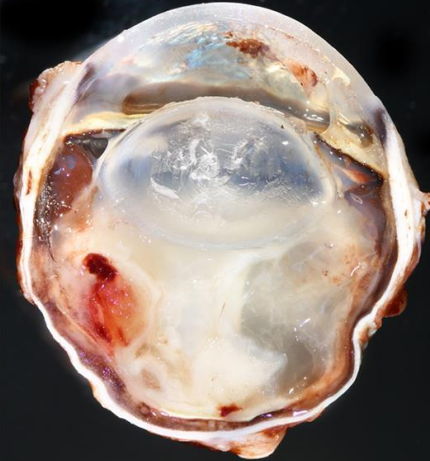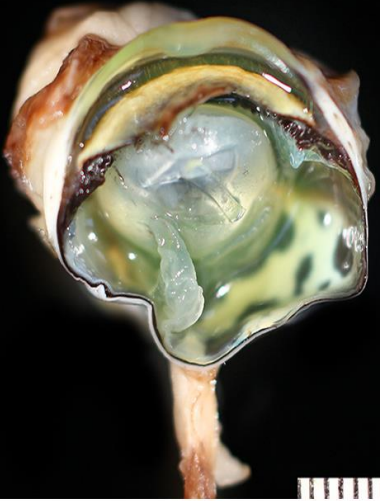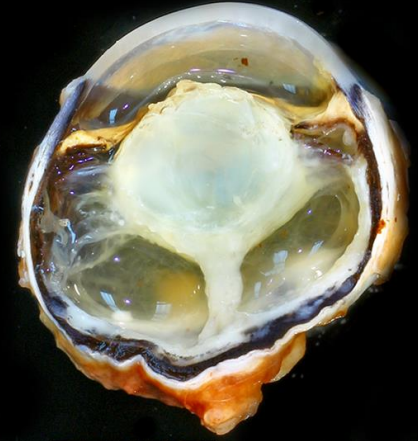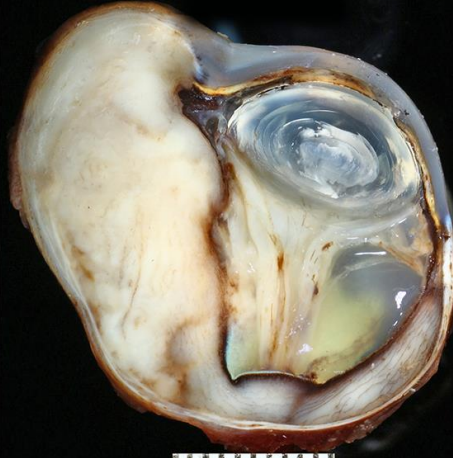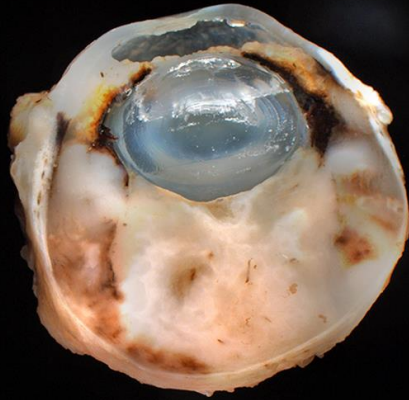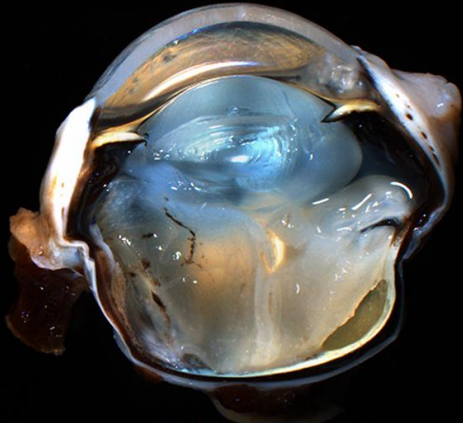
3 cases in dogs

42 cases in cats

- *Histoplasma capsulatum*
- Found in soil contaminated with bird droppings
- Affects many tissues
- Ohio River valley
- 4 micron intracellular organism

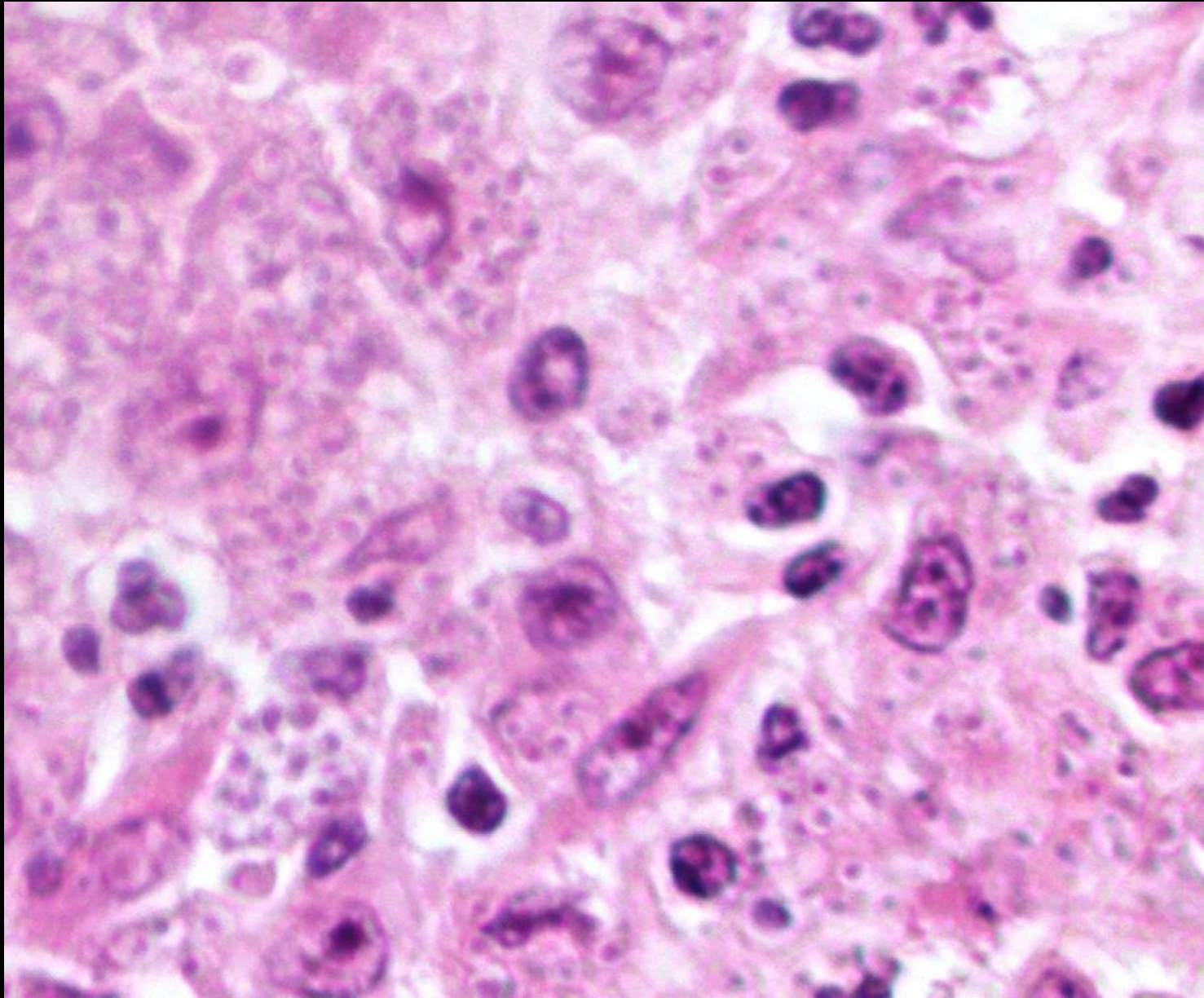
Histoplasmosis



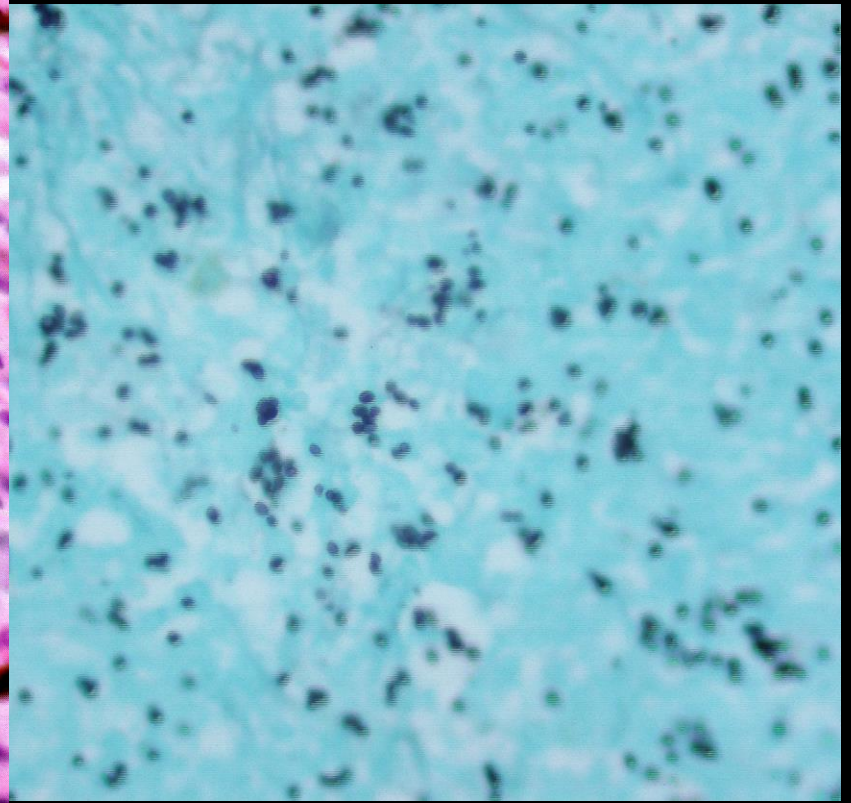
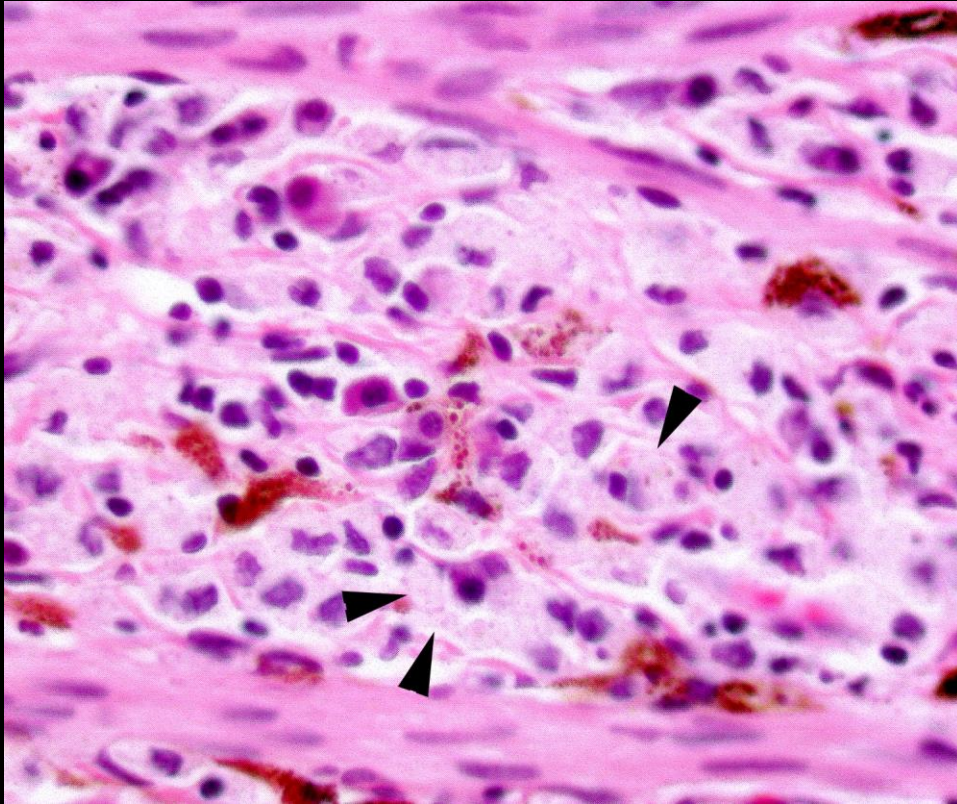


Feline Histoplasmosis

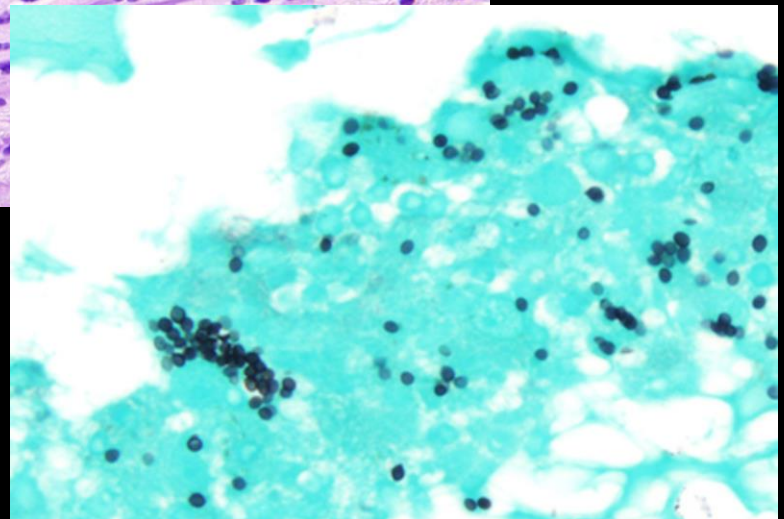
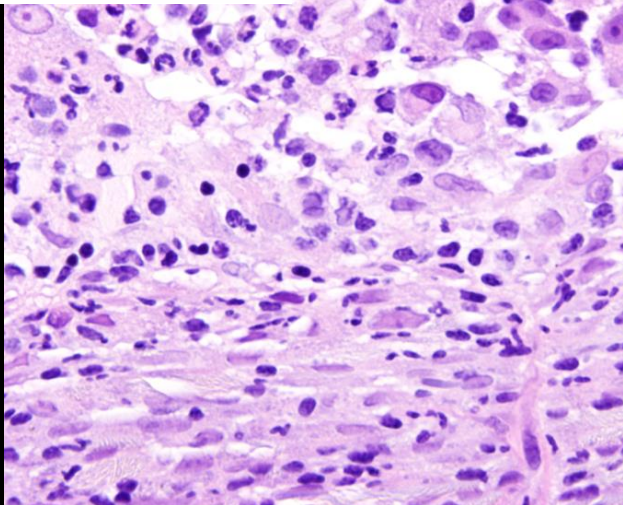
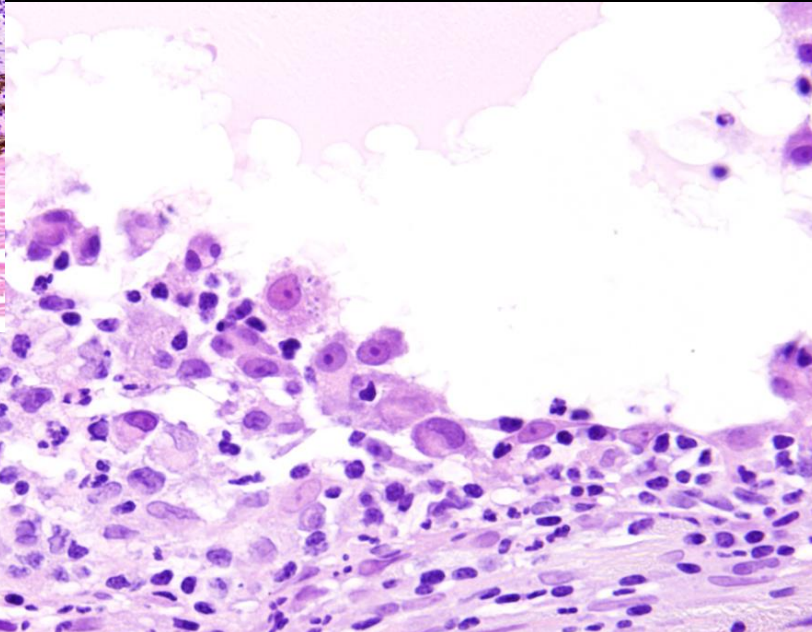
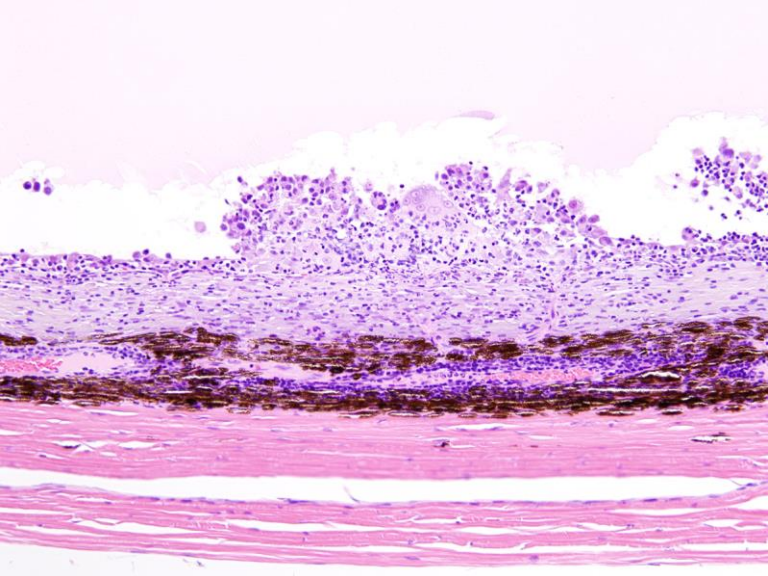
Histoplasmosis



Histoplasmosis



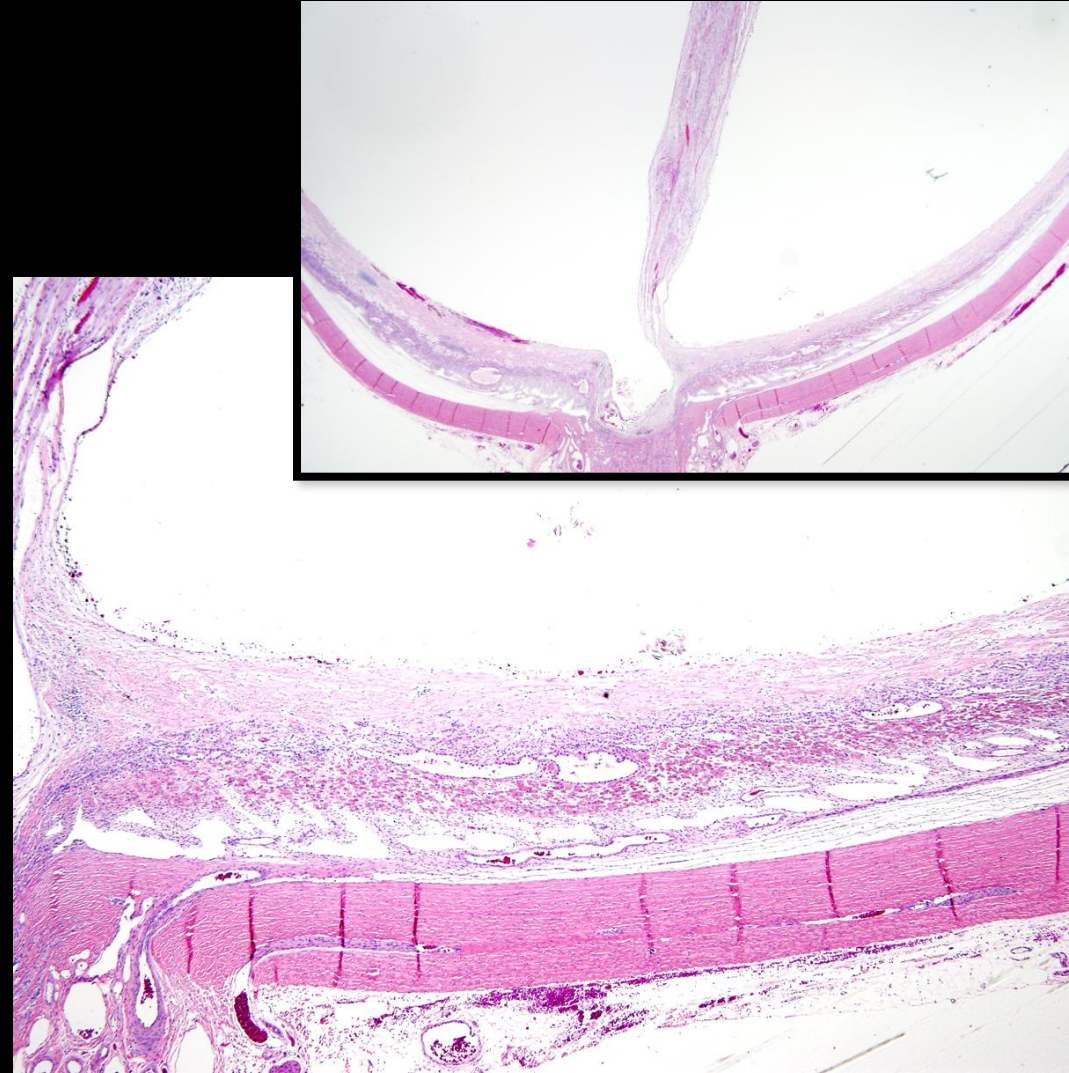
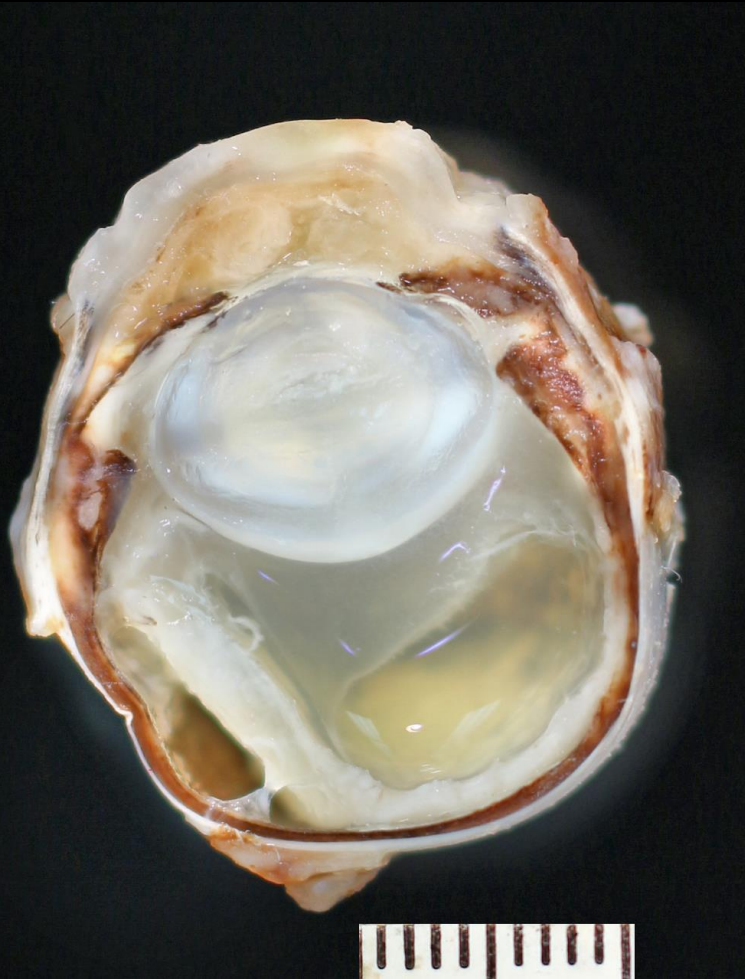
Histoplasmosis



Inner choroidal fibrosis and pyogranulomatous inflammation remaniscant of human “presumed histoplasmosis syndrome”

Histoplasmosis with Rare Organisms and
Inner Choroidal fibrosing Proliferative Reaction

Mimicking Human "Presumed Histoplasmosis"



Algal Uveitis Organisms

- Blastomycosis
- Cryptococcosis
- Coccidioidomycosis
- Histoplasmosis
- **Protothecosis**
- Aspergillosis

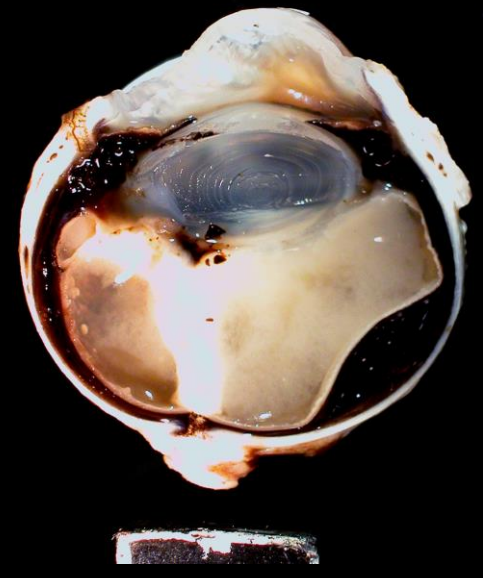
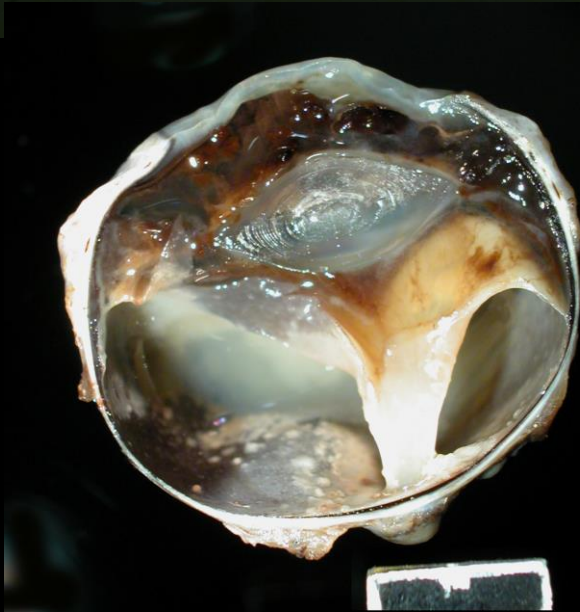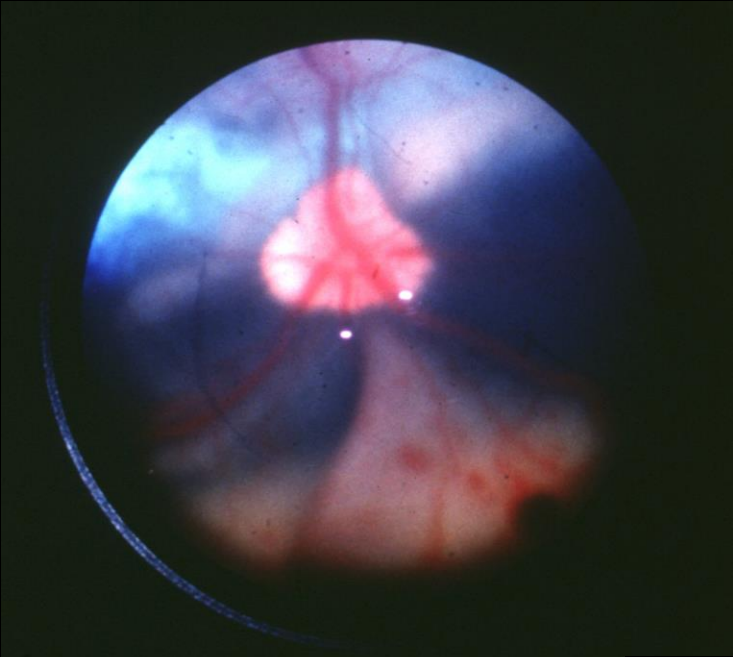
Protothecosis

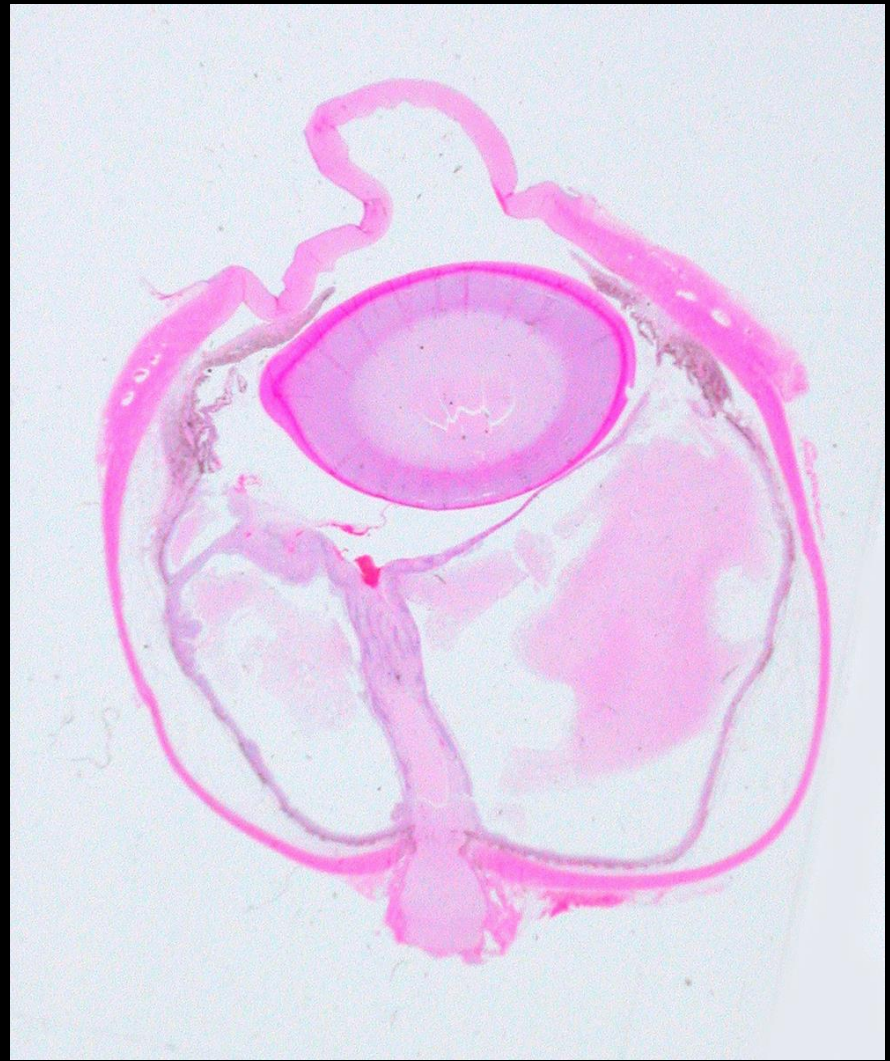20 cases in dogs, 0 in cats

- *Prototheca zopfii*, *Prototheca wickerhamii*
- Saprophytic achlorophyllous algae
- Worldwide distribution infecting several species
- Associated with contaminated water and susceptible host

Protothecosis

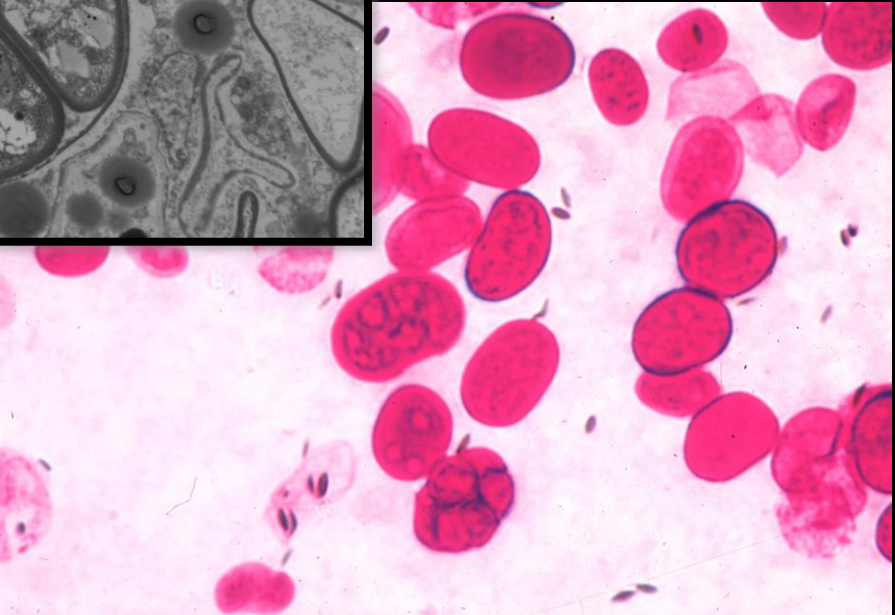
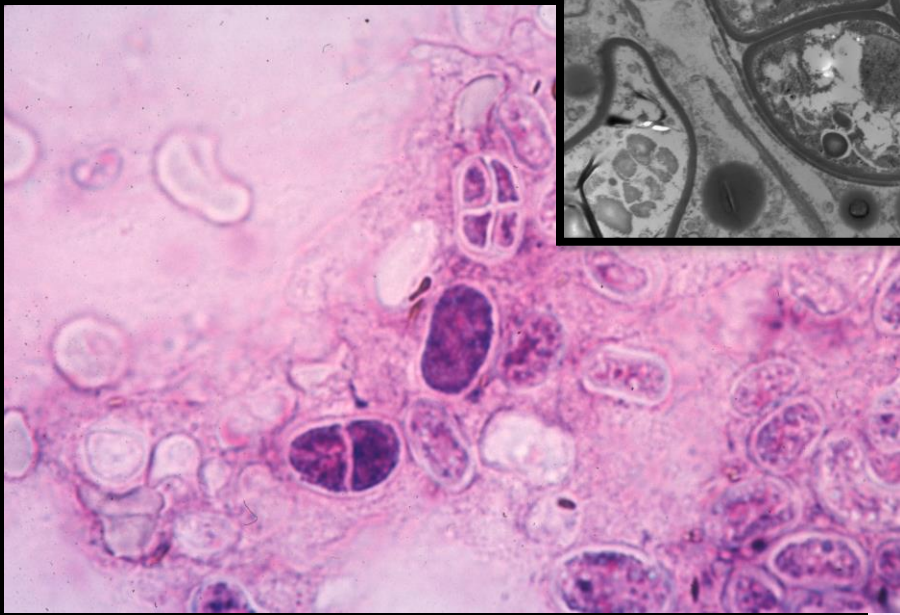
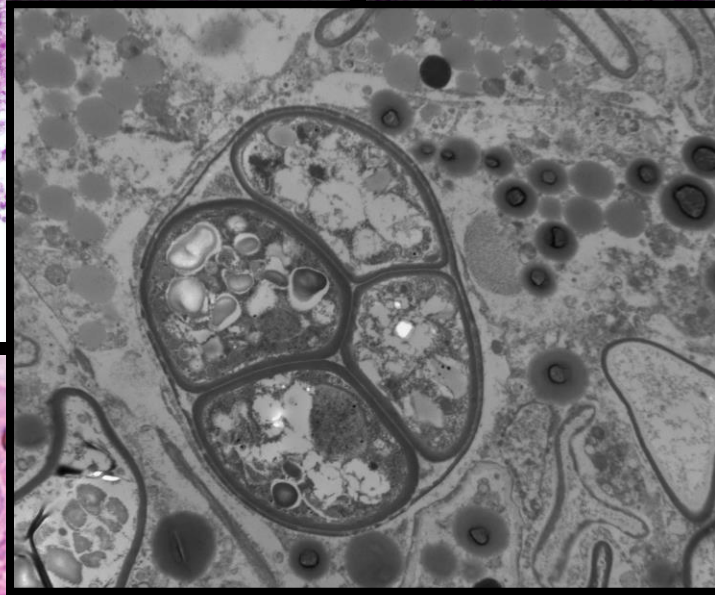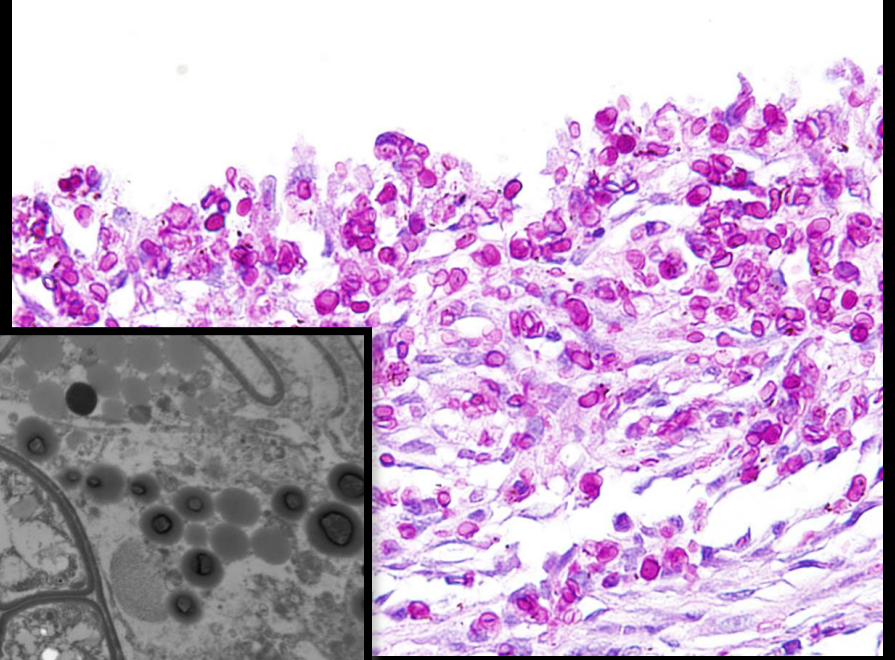
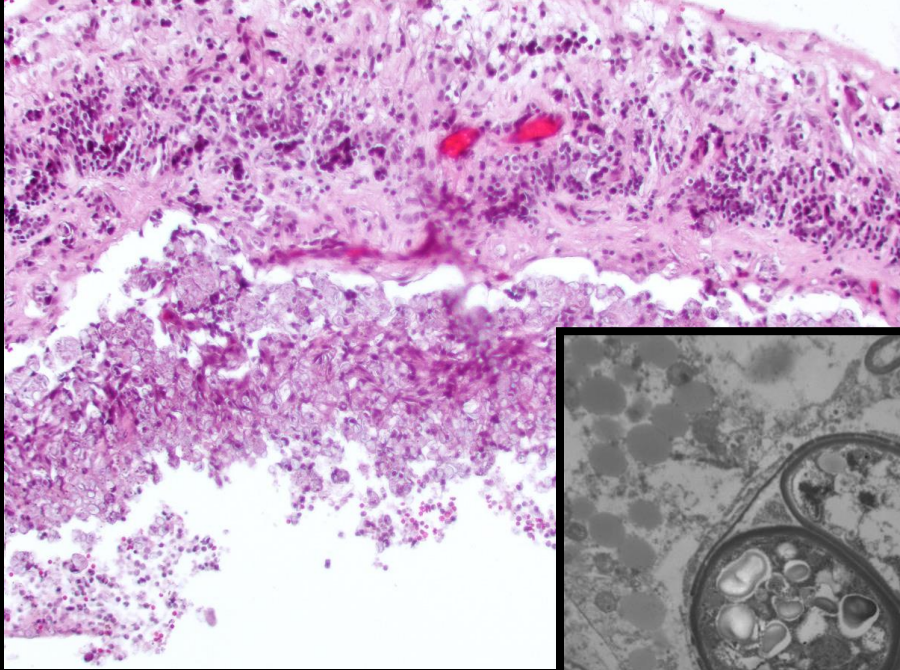
Characterized by a bland histiocytic chorioretinitis with complete retinal detachment and huge numbers of PAS+ organisms





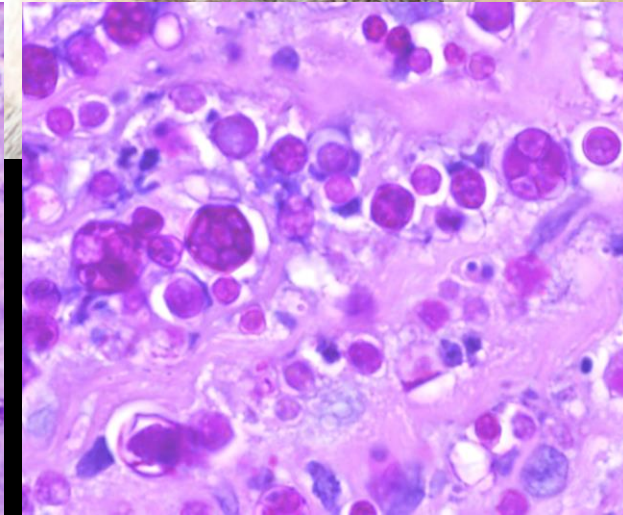
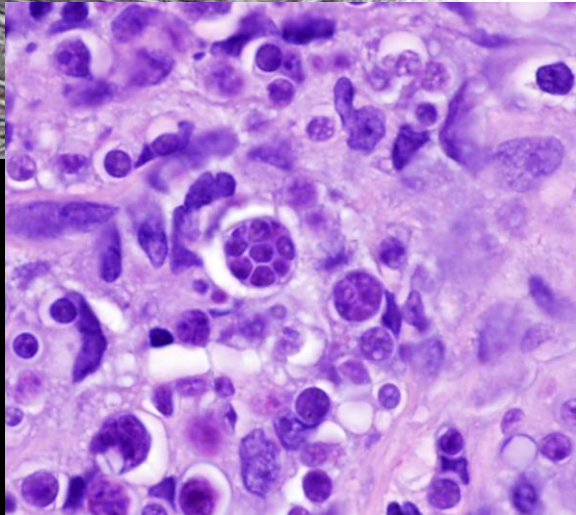
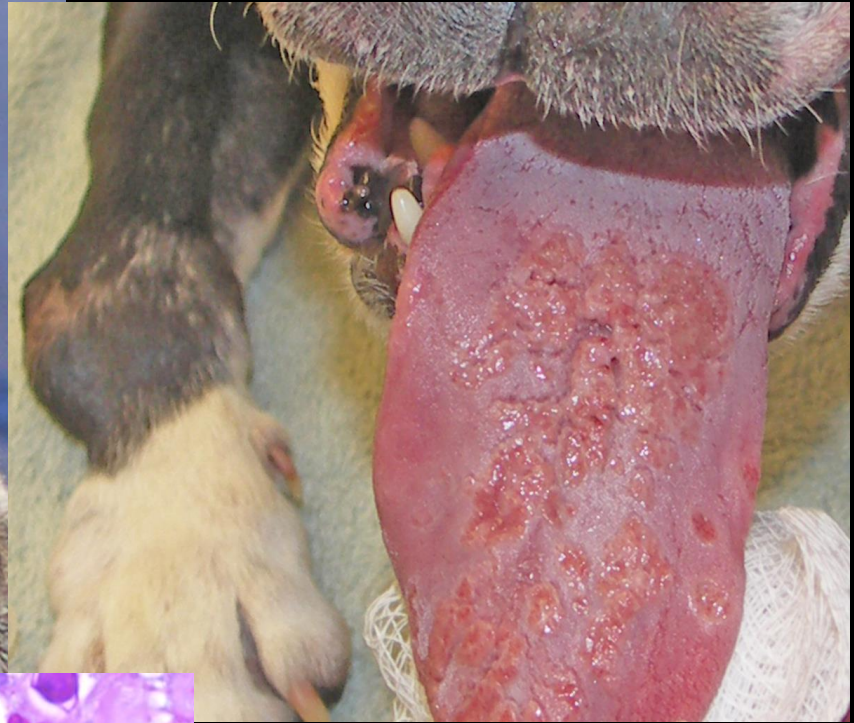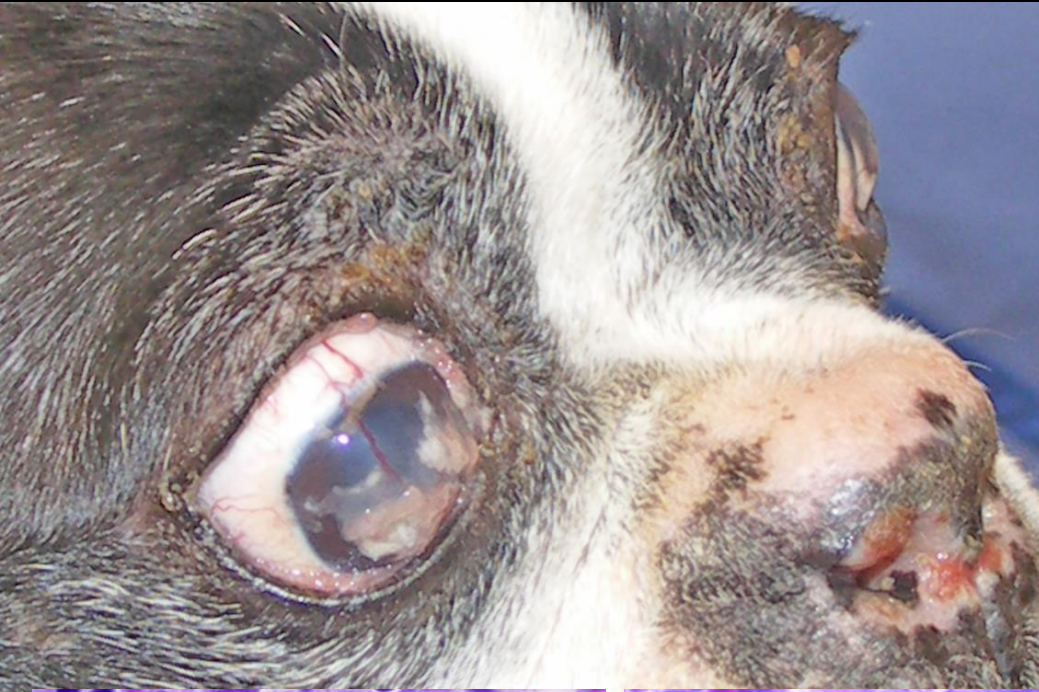Protothecosis

Protothecosis



Cutaneous Protothecosis

Mis-diagnosed as Blastomycosis



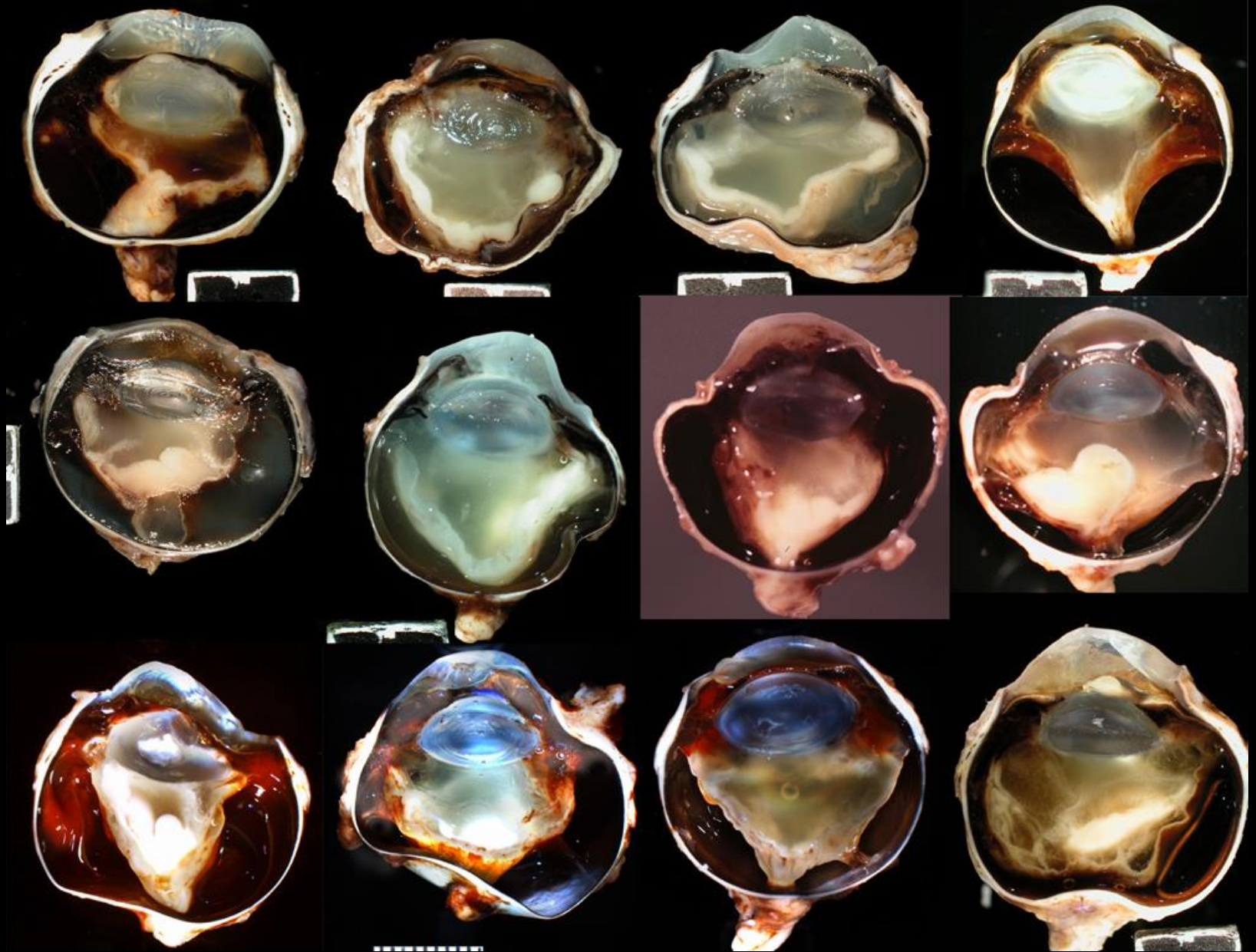
Mycotic Uveitis Organisms

- Blastomycosis
- Cryptococcosis
- Coccidioidomycosis
- Histoplasmosis
- Protothecosis
- Aspergillosis

Canine Systemic Aspergillosis

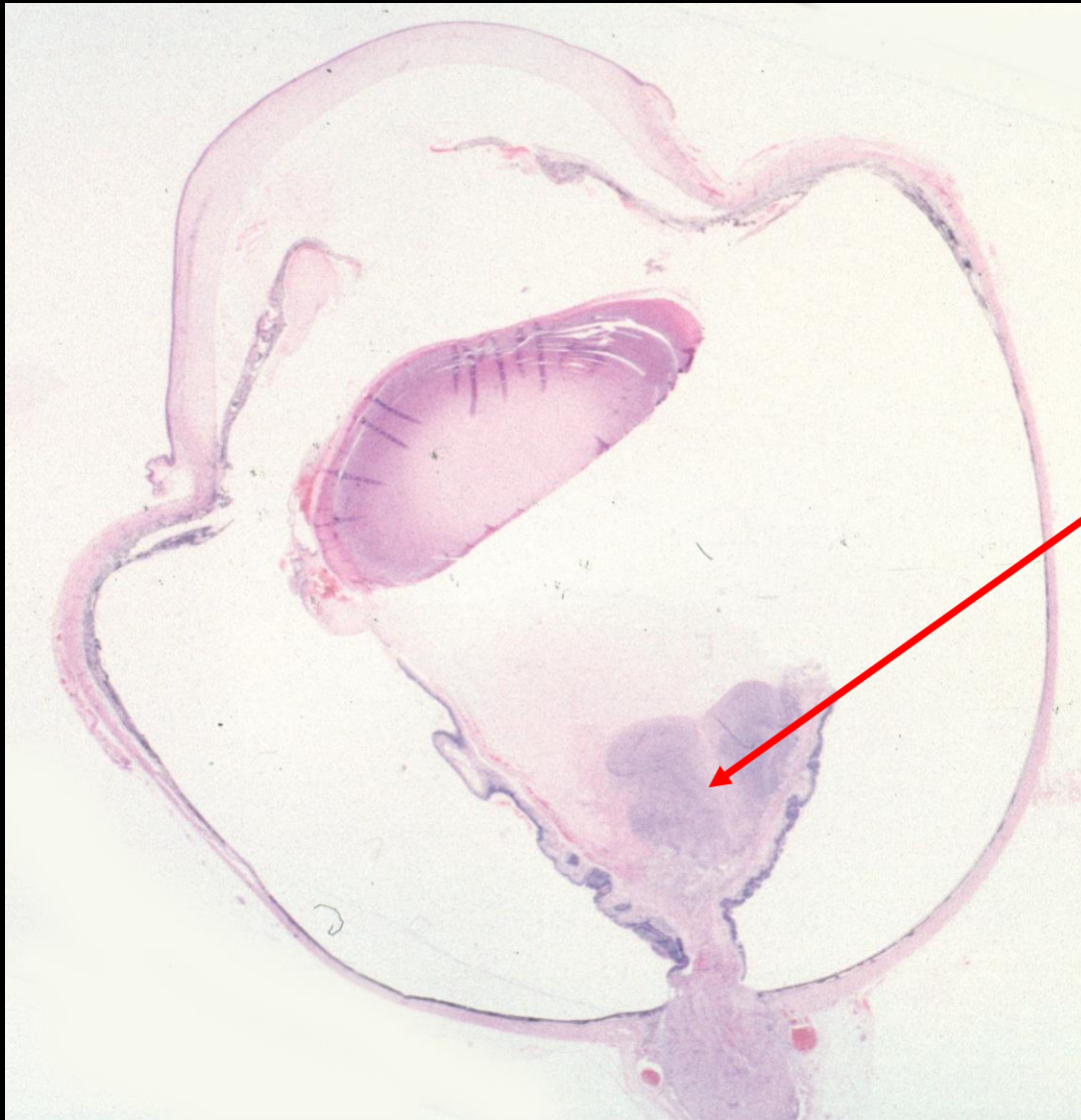44 Cases

- Worldwide distribution
- German Shepherd breed at risk (24/44 cases)
- No more of 2 from any other breed except 5 mixed breed
- Systemic disease with vasculitis
- Characterized by suppurative vitritis
- Poor prognosis



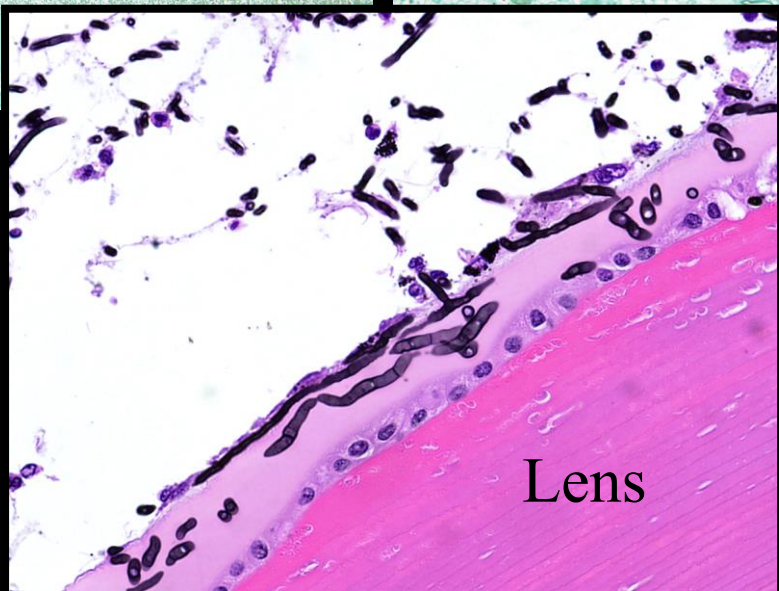
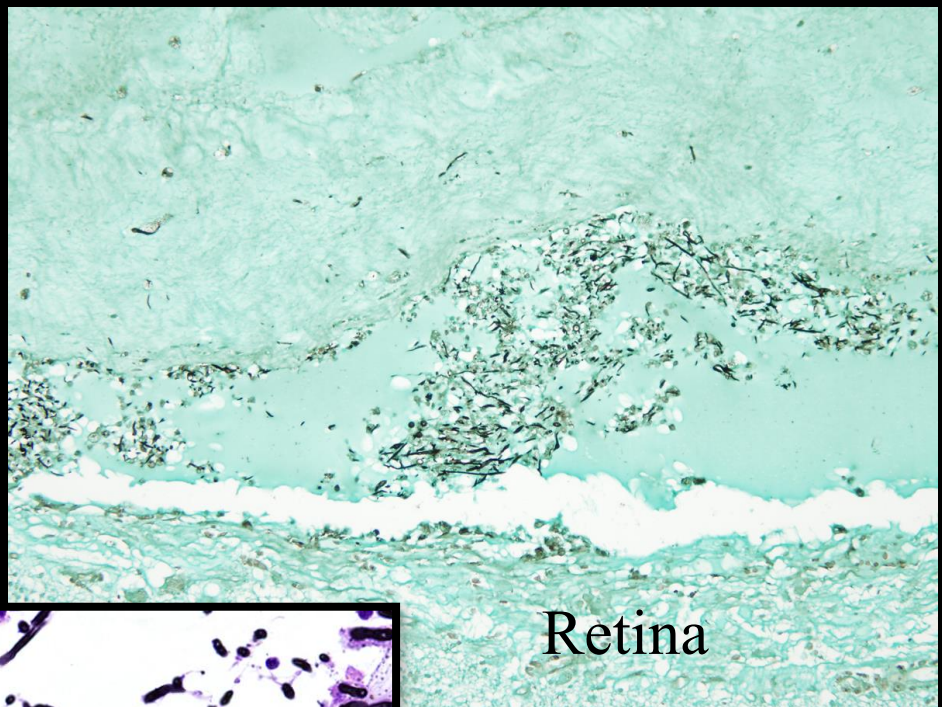
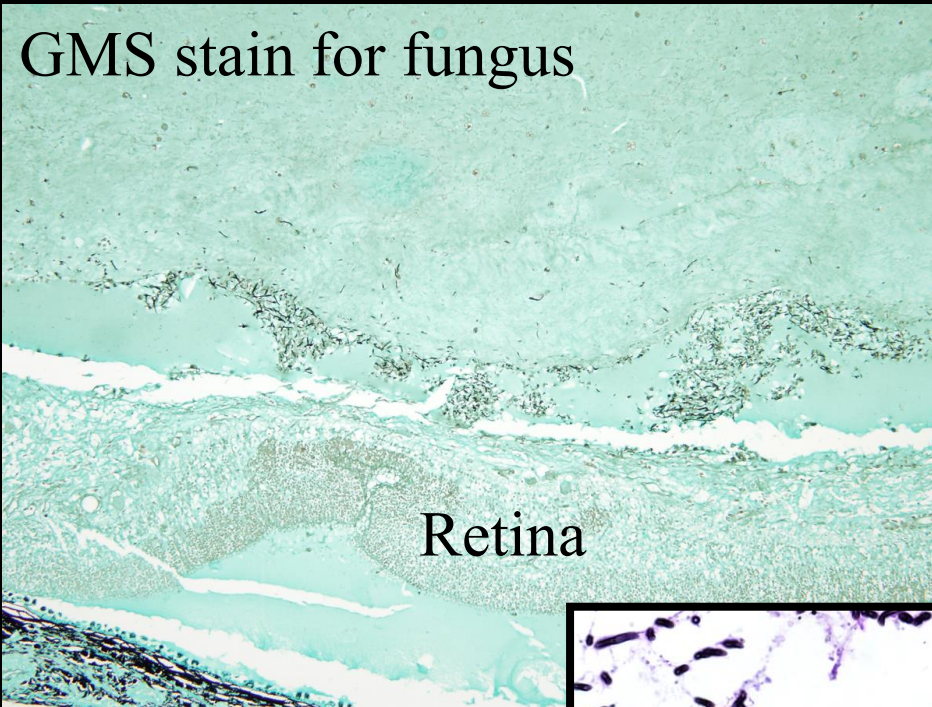
Systemic Aspergillosis

Canine Systemic Aspergillosis



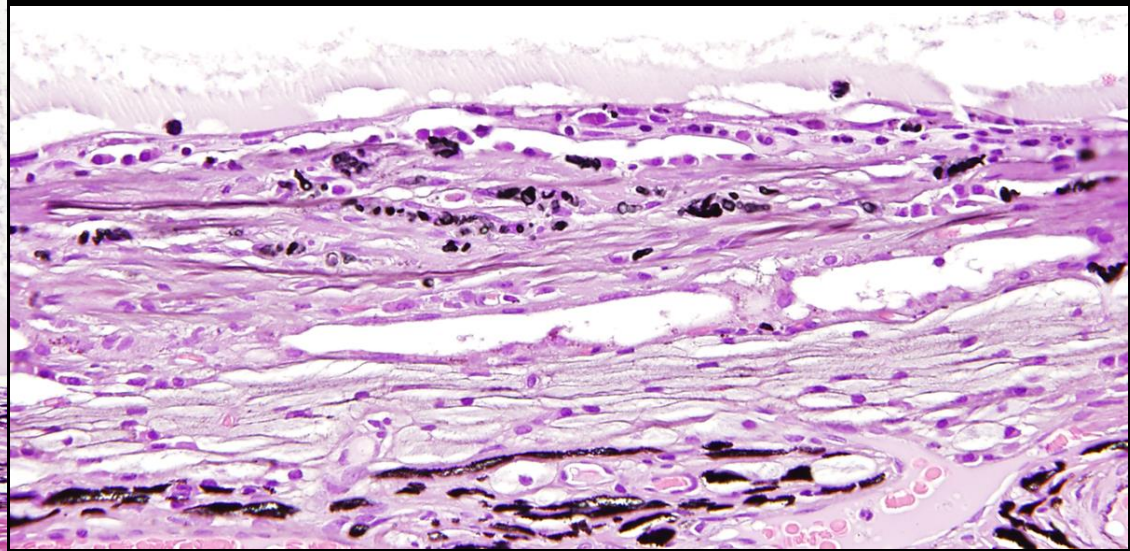
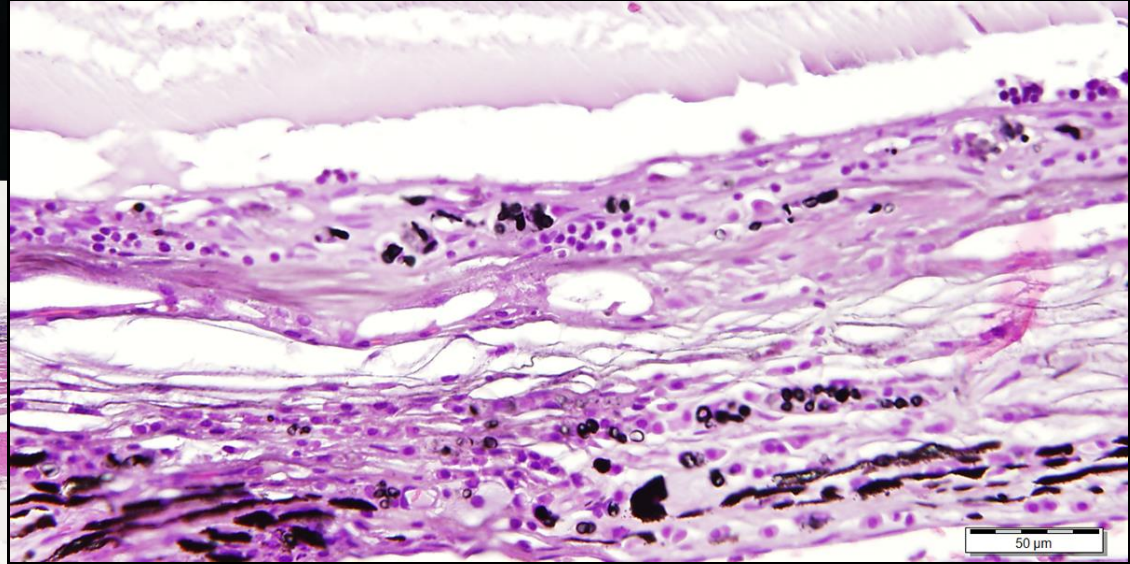
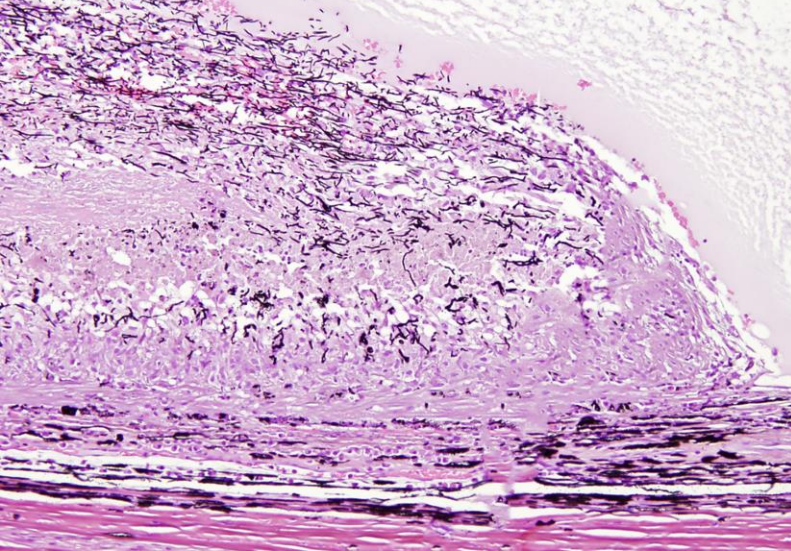
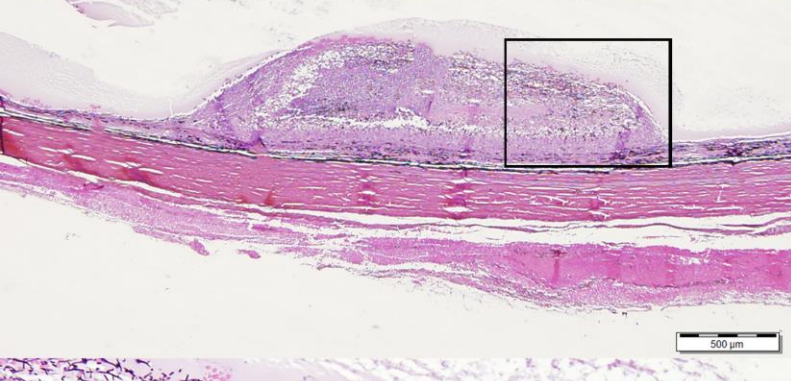
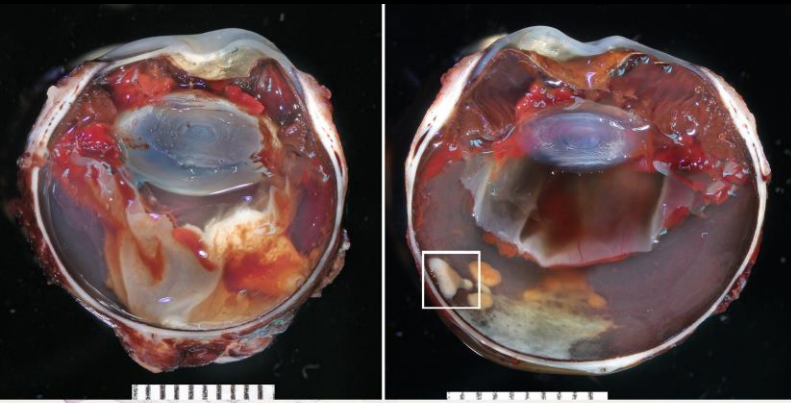
Characteristic vitritis

Canine Systemic Aspergillosis



Occasional cases
have lens capsule
involvement

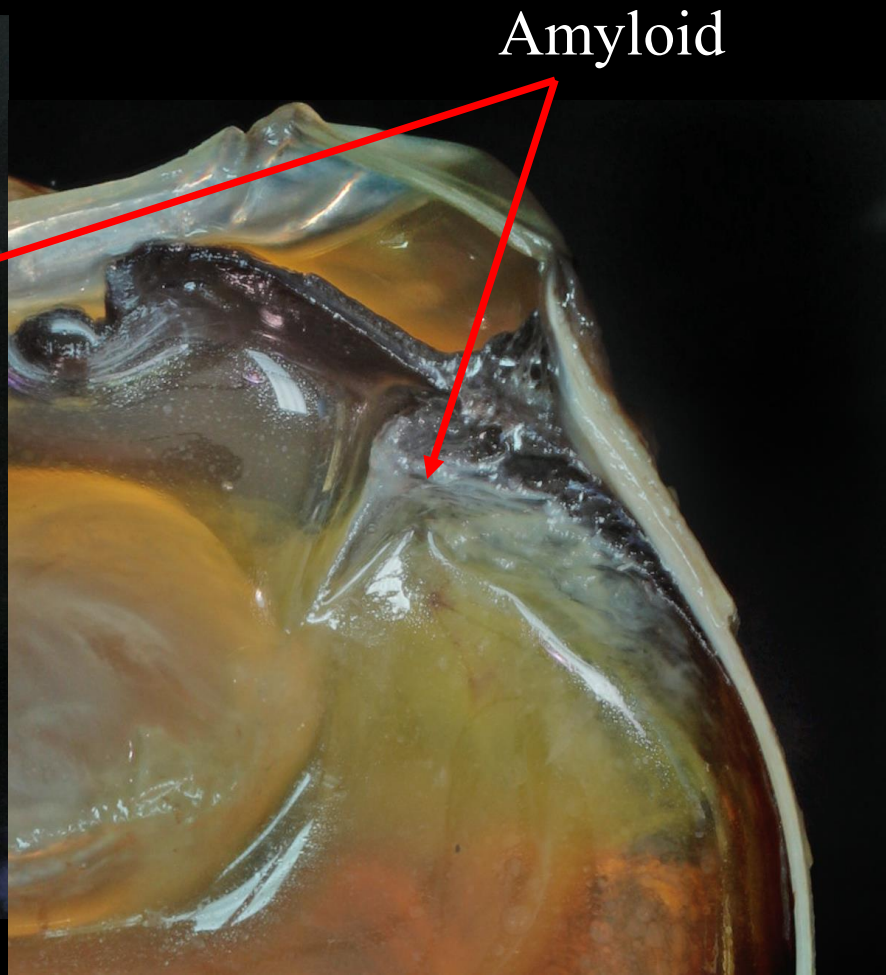
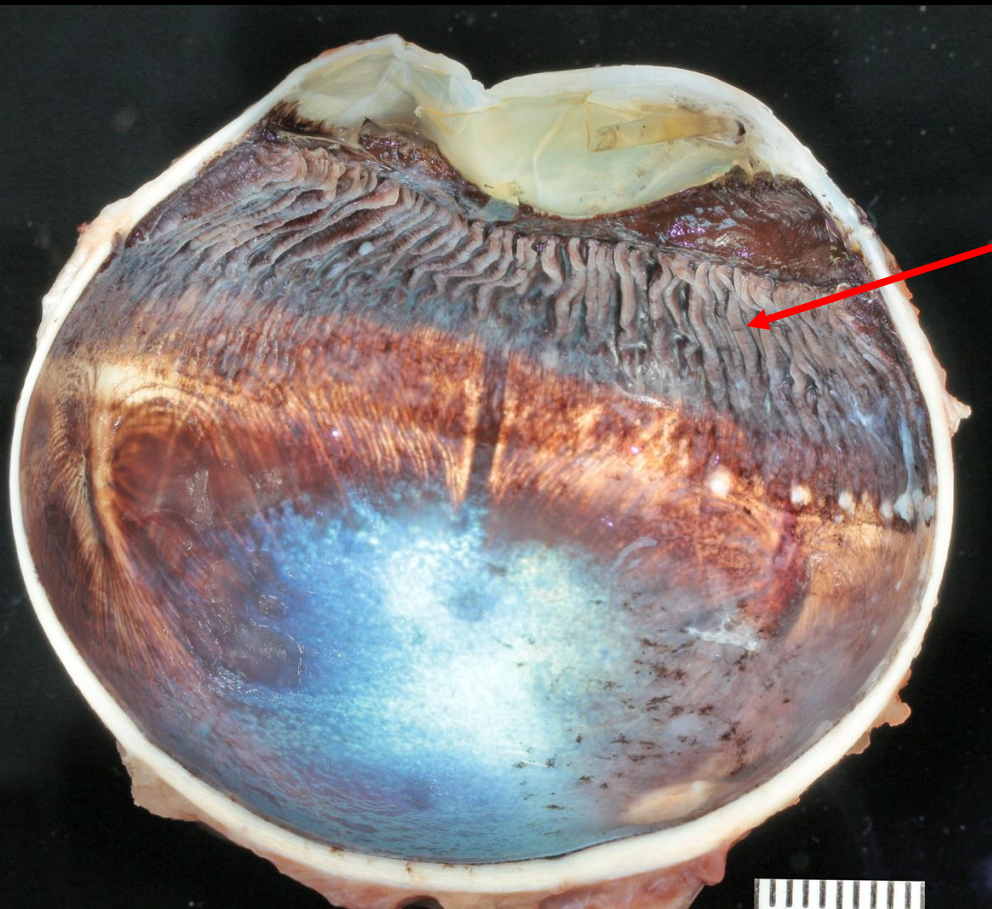
Canine Systemic Aspergillosis



Equine Recurrent Uveitis (ERU)

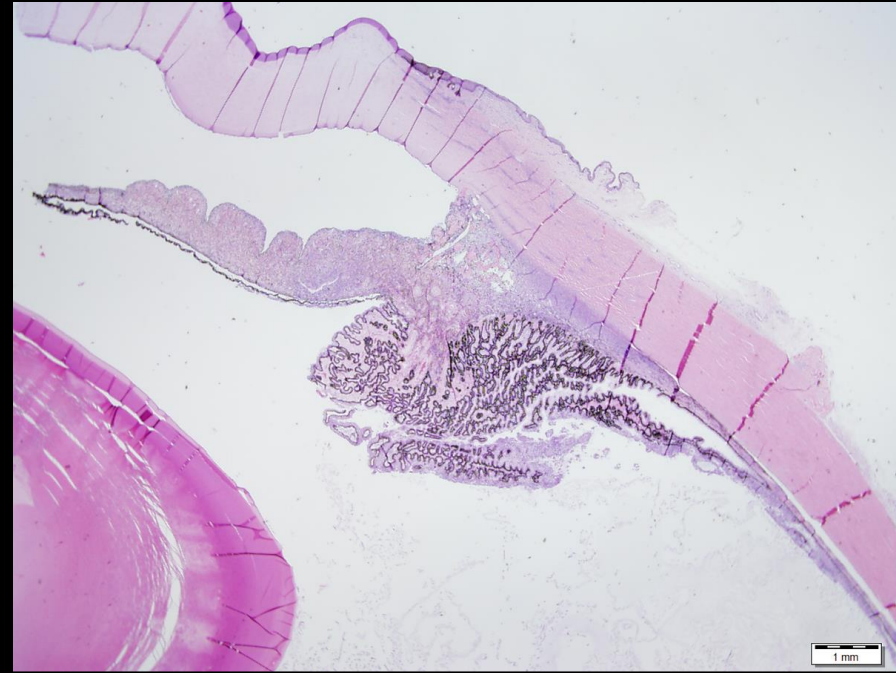- 140 cases
- 32 Appaloosa, 20 Quarterhorse, 13 Thoroughbred
- Bilateral, but not always symmetrical
- Cyclic Uveitis
- Etiology
 - Leptospirosis
 - Autoimmunity
- Classic morphologic features
 - Lymphoplasmacytic inflammation with lymphoid follicles
 - Lymphocytes within the ciliary epithelium
 - Linear hypereosinophilic cytoplasmic inclusions in the non-pigmented ciliary epithelium
 - Amyloid deposition on the inner surface of the non-pigmented ciliary epithelium

Equine Recurrent Uveitis (ERU)

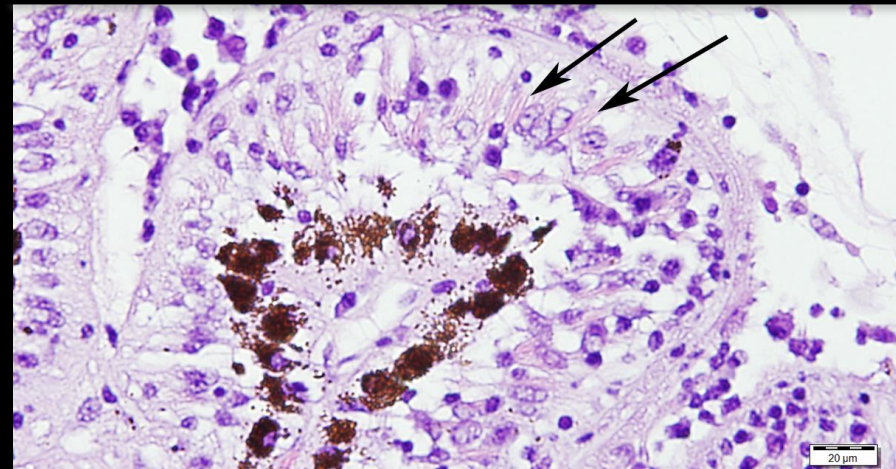


Equine Recurrent Uveitis (ERU)

Active Stage of Disease

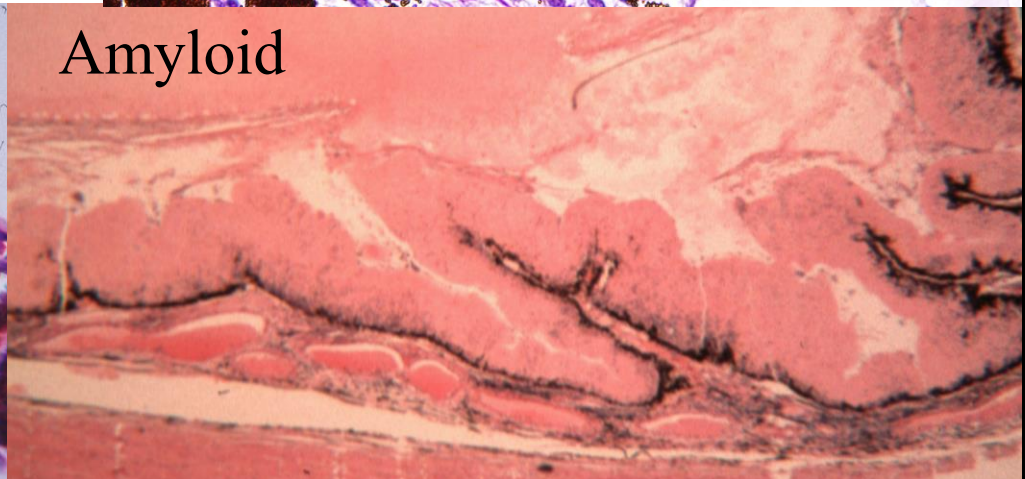
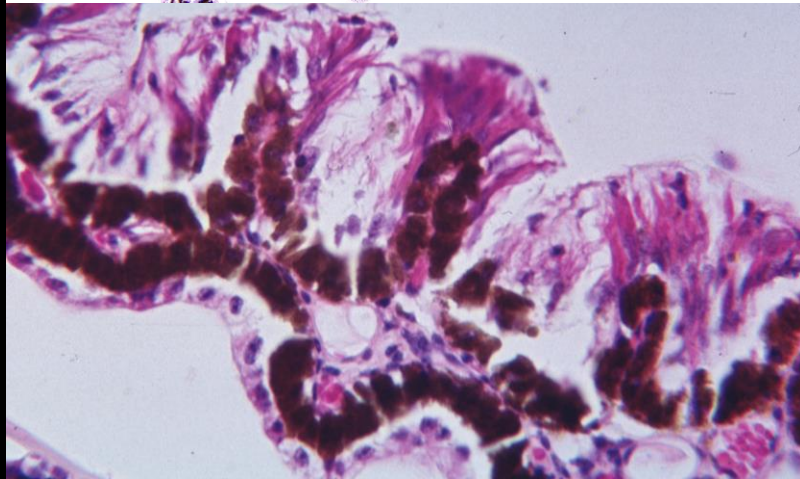
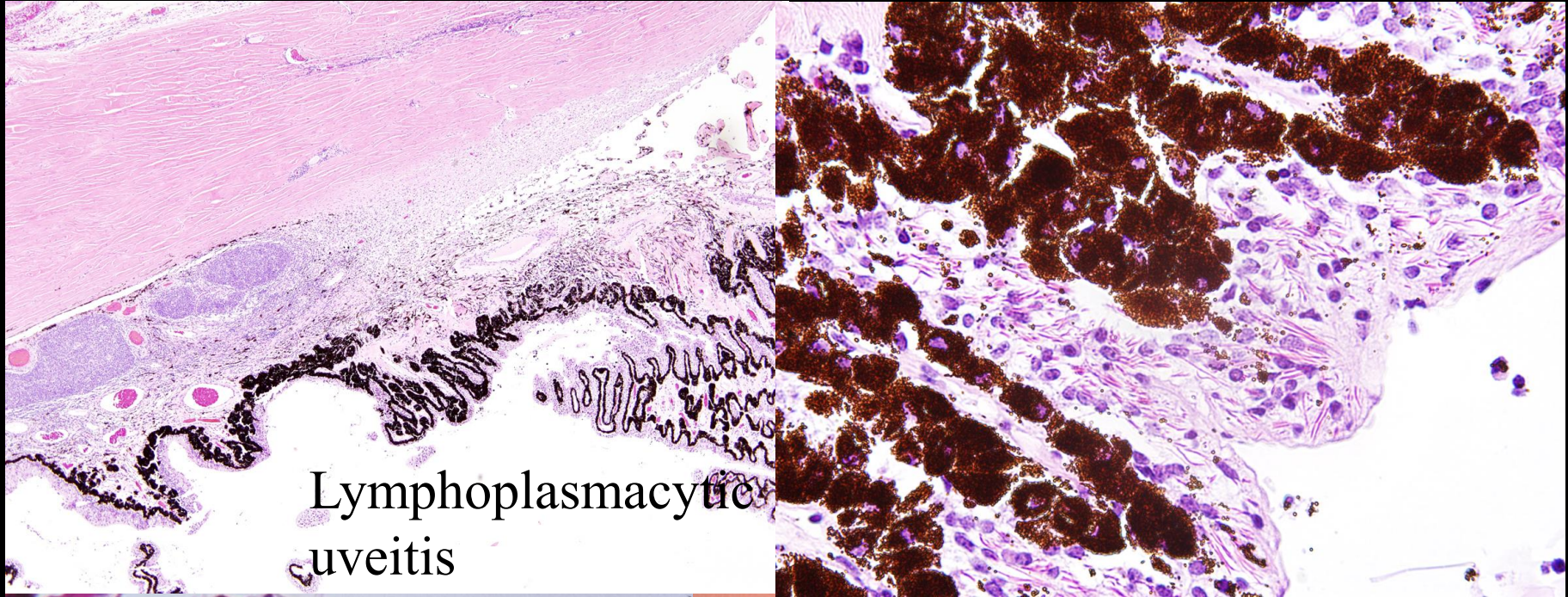


1 mm

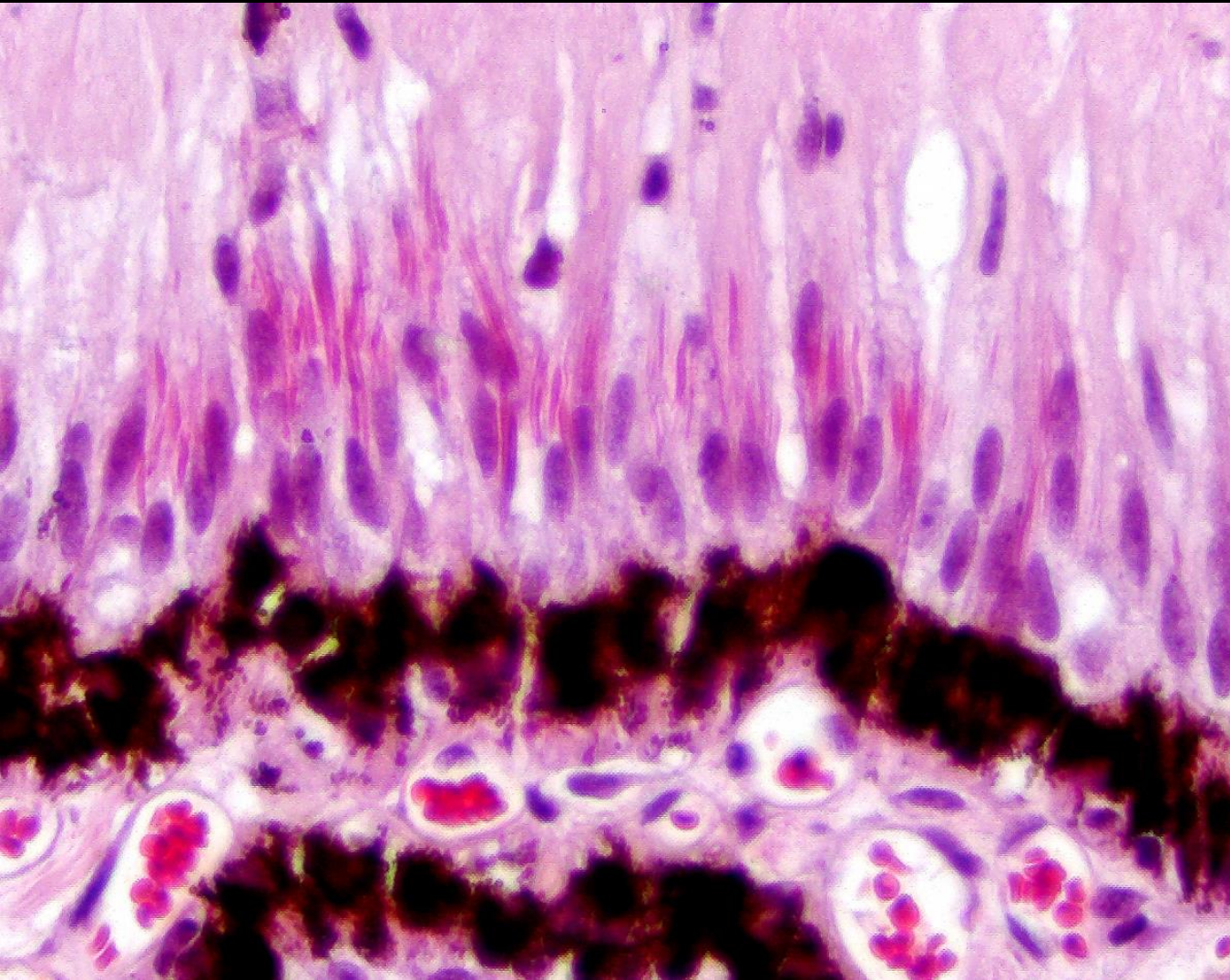


20 μ m

Equine Recurrent Uveitis (ERU)

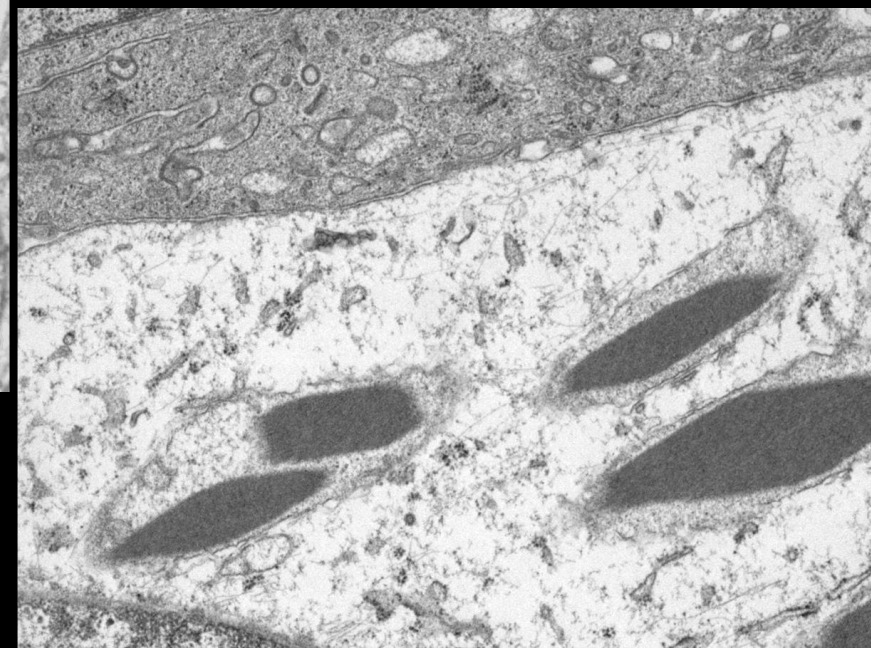
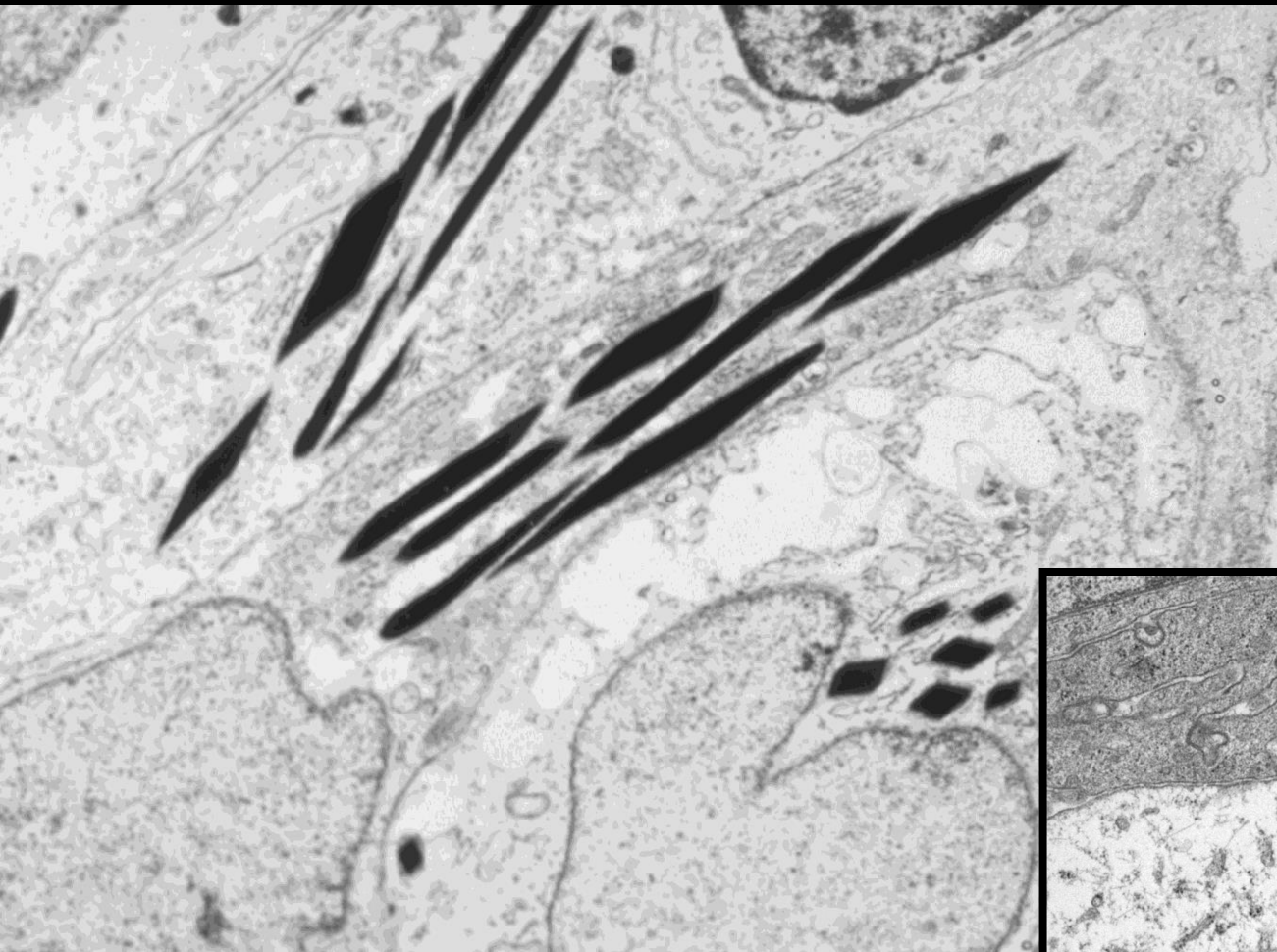
Equine Recurrent Uveitis (ERU)



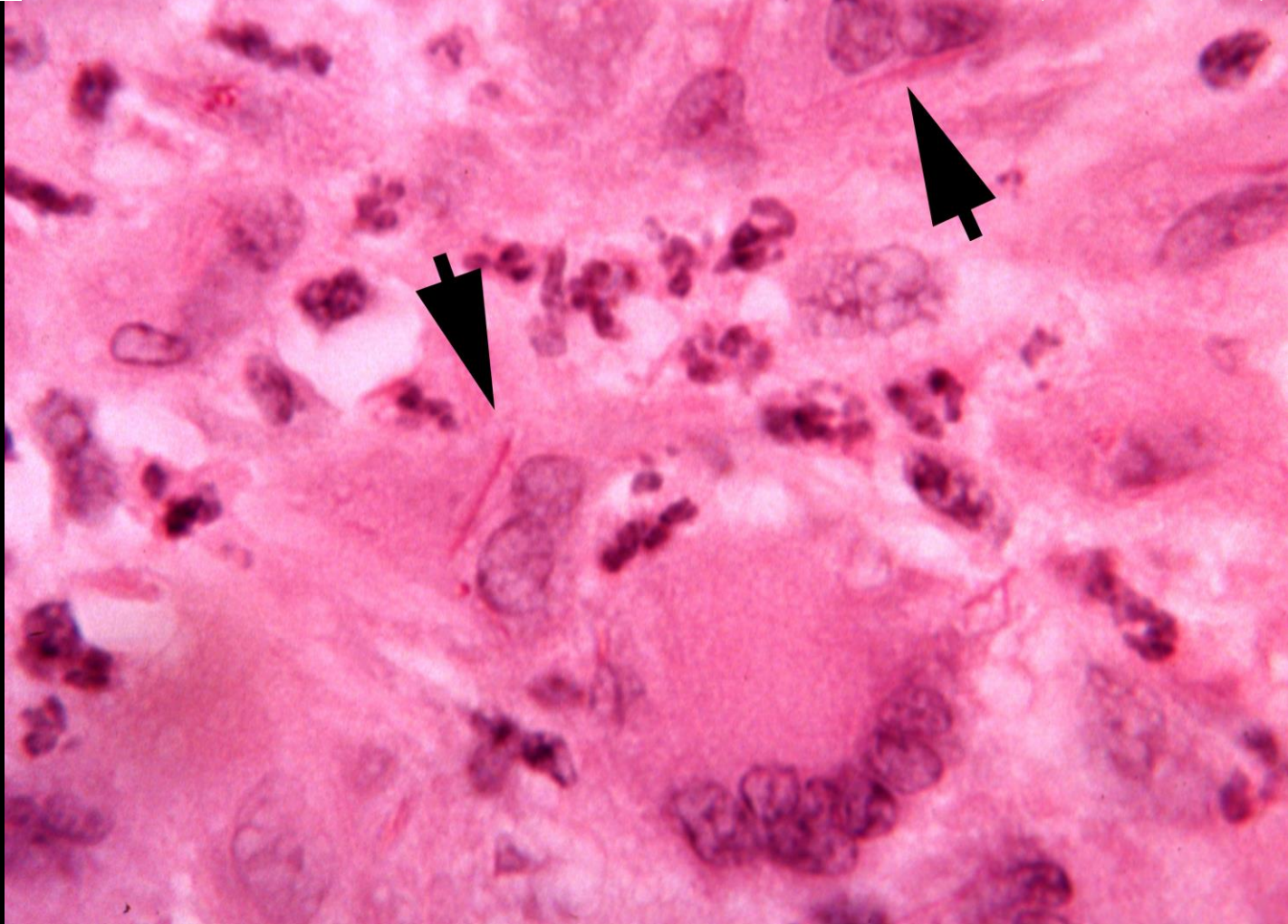
Linear eosinophilic
inclusions
in the cytoplasm
of the nonpigmented
ciliary epithelium

Equine Recurrent Uveitis (ERU)



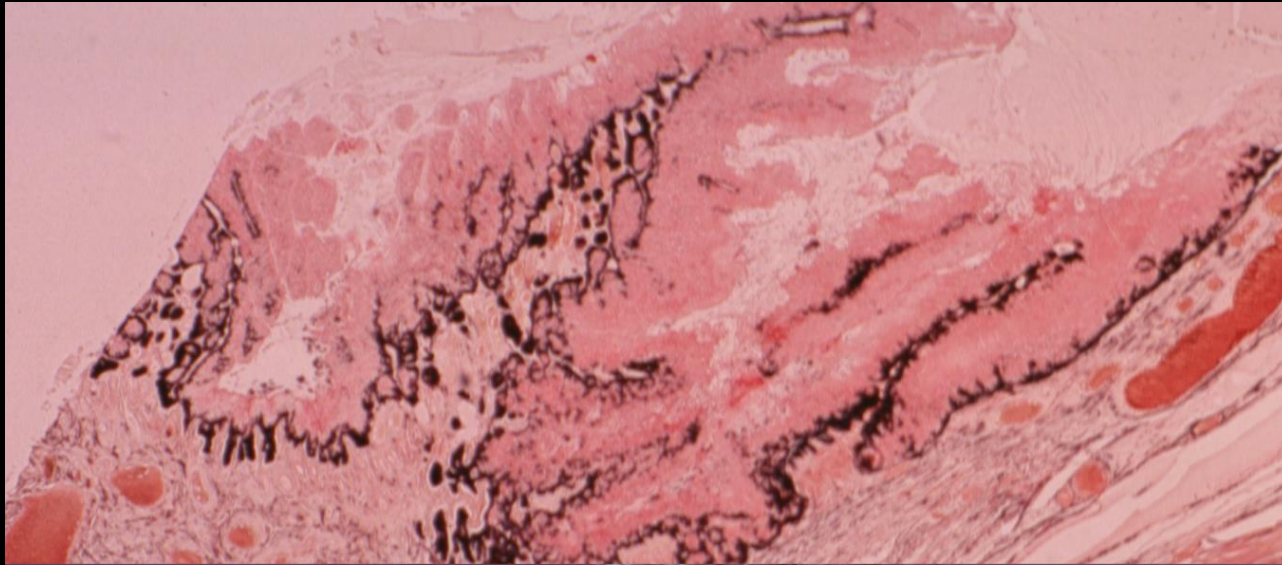
Crystalline protein inclusions
in mitochondria

Equine Recurrent Uveitis (ERU)

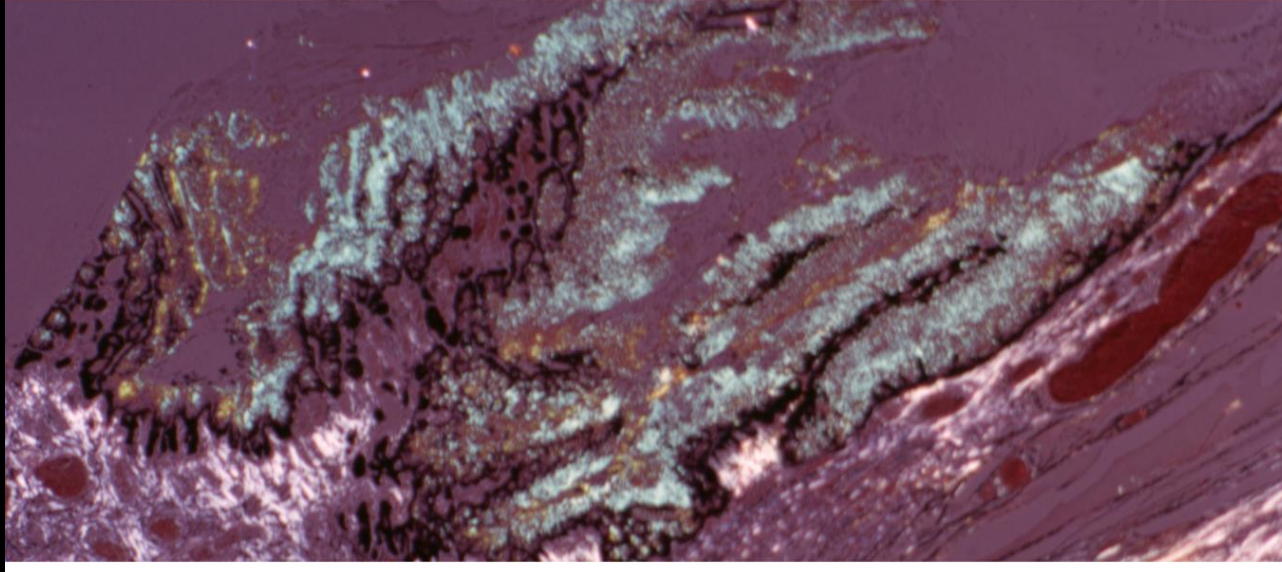


Other granulomatous conditions in horses have crystalline protein inclusions

Equine Recurrent Uveitis (ERU)

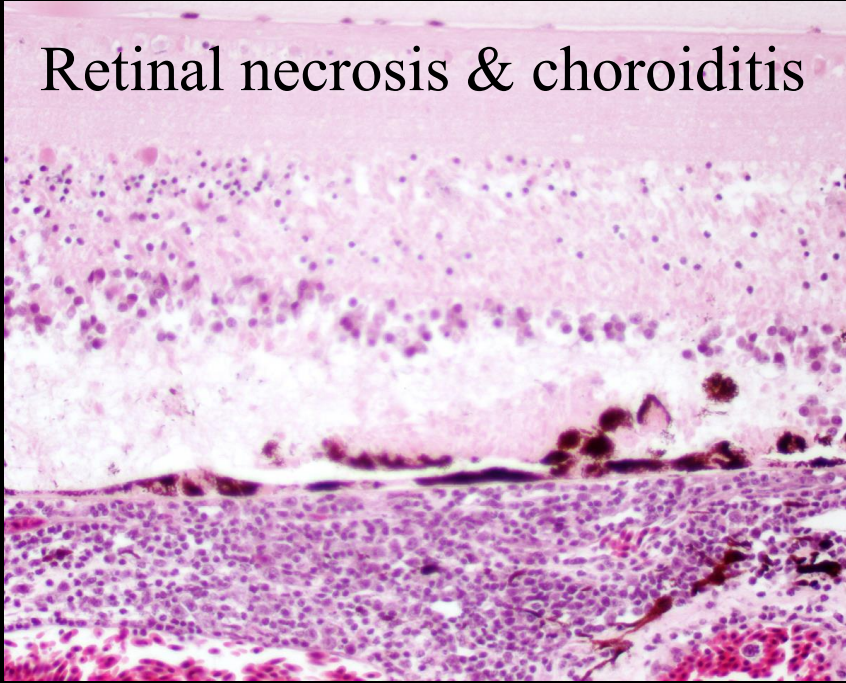


Amyloid
Deposited on
the inner aspect
of the nonpigmented
ciliary epithelium

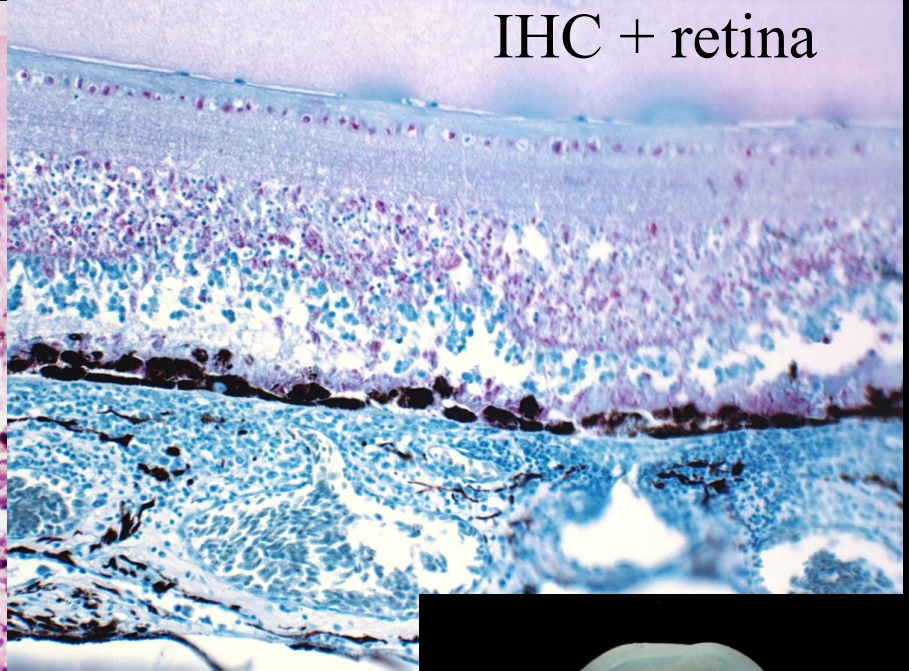


West Nile Virus in Raptors

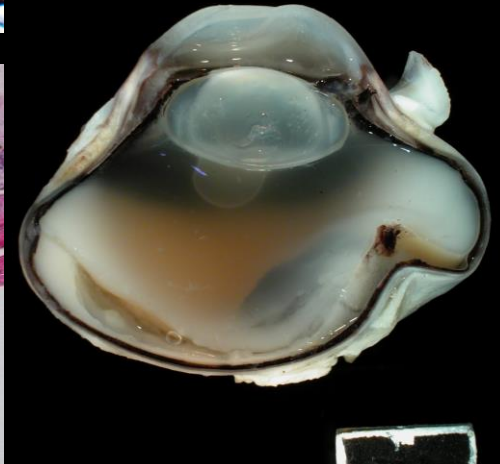
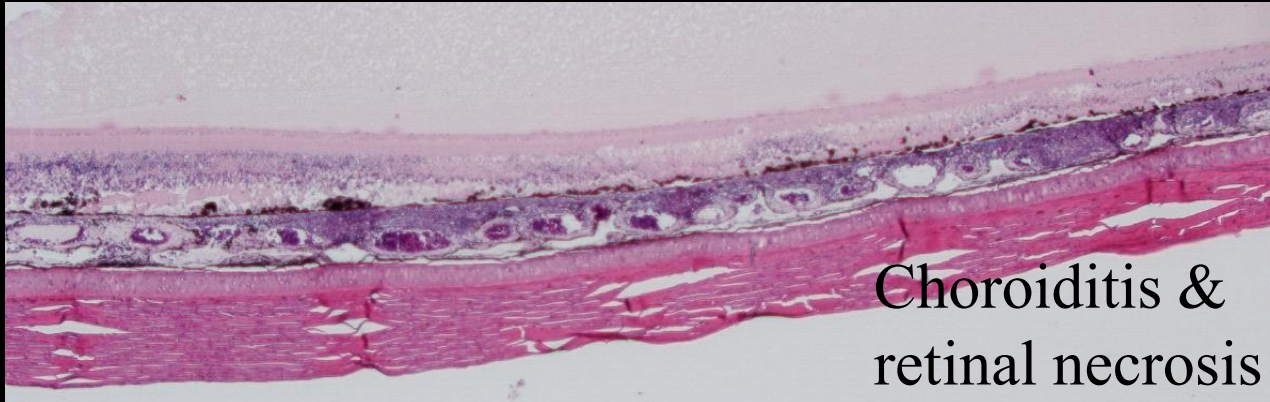
Retinal necrosis & choroiditis



IHC + retina



Choroiditis & retinal necrosis

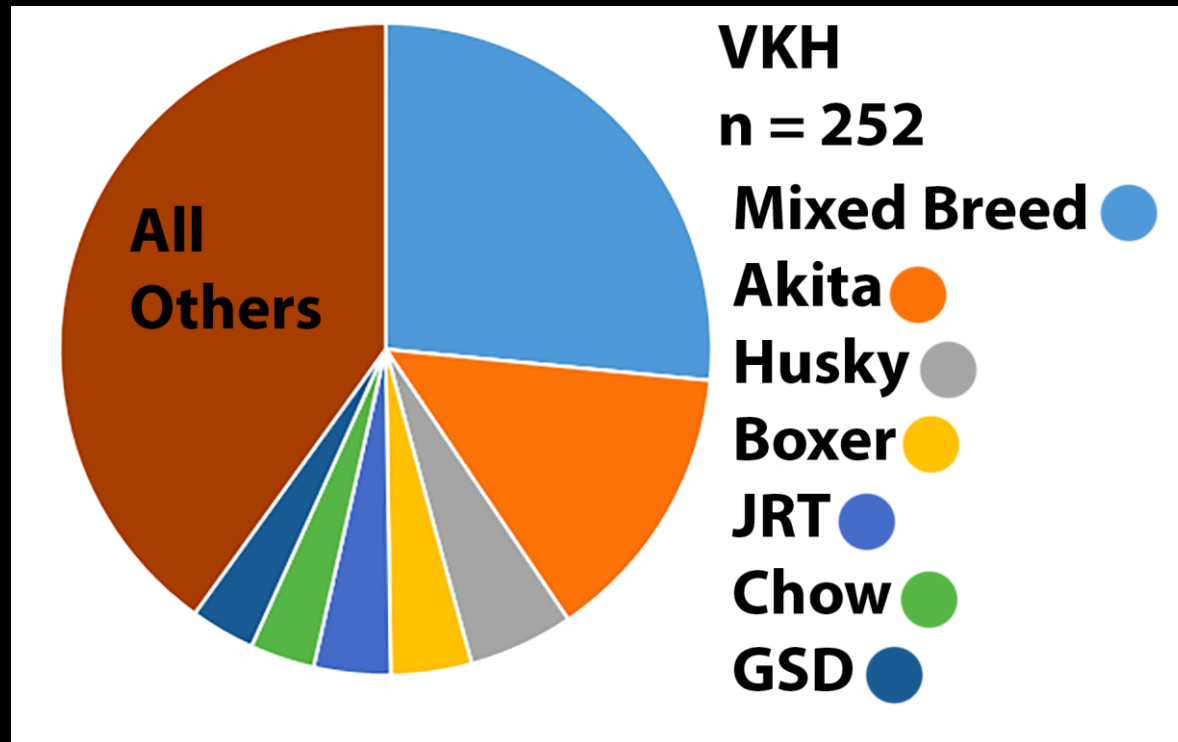


Canine Uveodermatologic Syndrome

Vogt-Koyanagi-Harada Syndrome

VKH

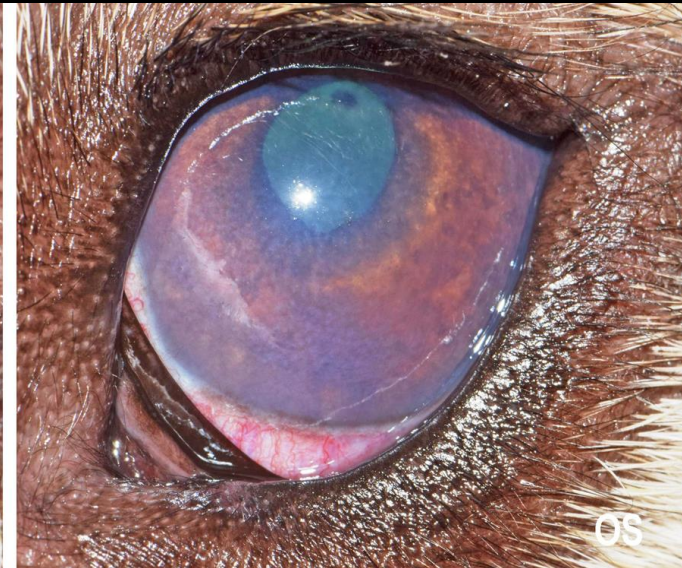
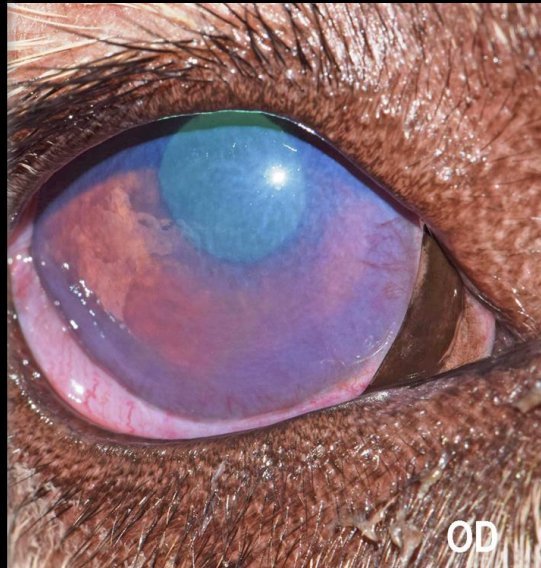
252 cases



Canine Uveodermatologic Syndrome Vogt-Koyanagi-Harada Syndrome VKH

- Breeds

| | | |
|-------|----|-------|
| 0.4% | 1 | NA |
| 30.6% | 77 | OD |
| 33.3% | 84 | OS |
| 2.4% | 6 | other |
| 27.8% | 70 | OU |
| 5.6% | 14 | X |

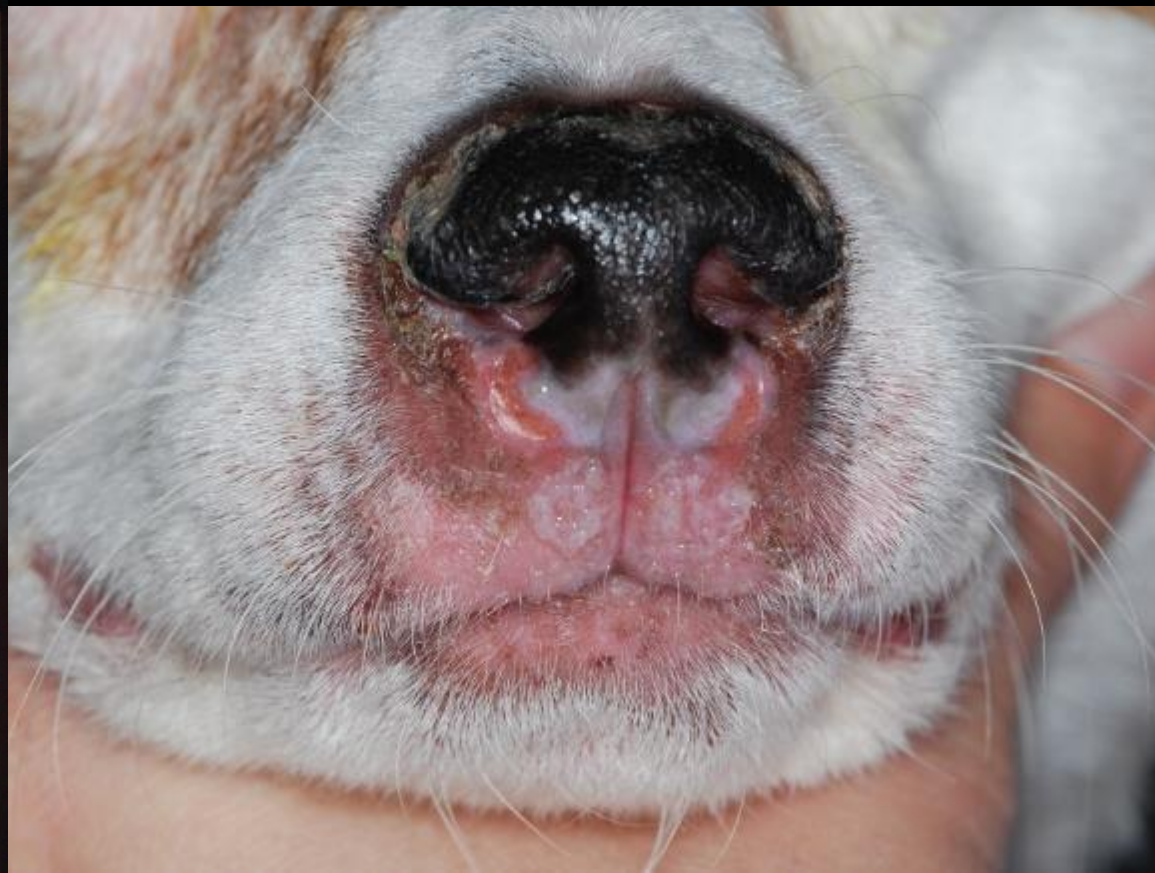

- Bilateral symmetry is a distinctive feature
- Glaucoma and retinal detachment
- Lacking retinal inflammation
- Morphologically, relatively quiet eye

Canine Uveodermatologic Syndrome

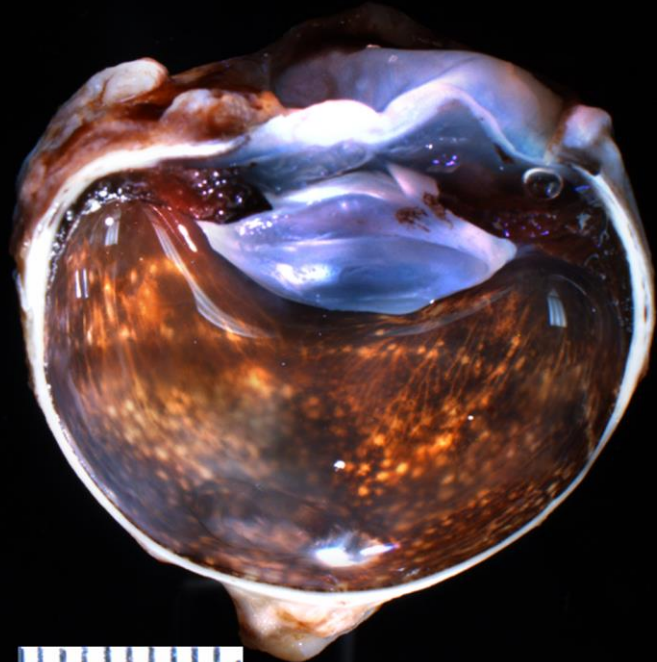
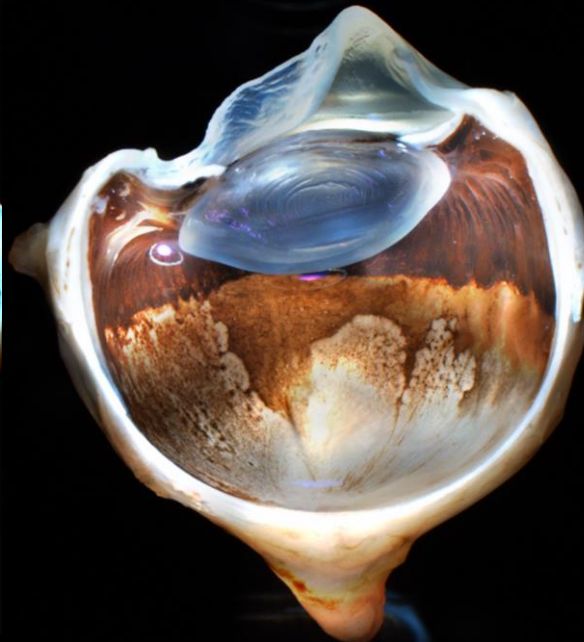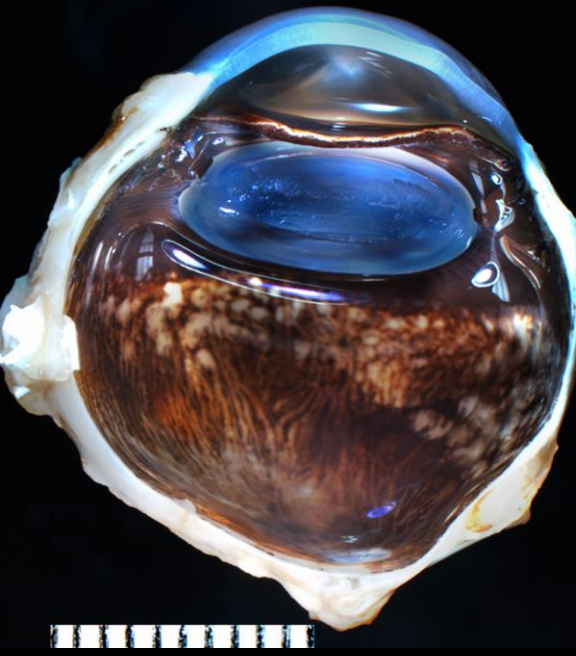
Vogt-Koyanagi-Harada Syndrome

VKH



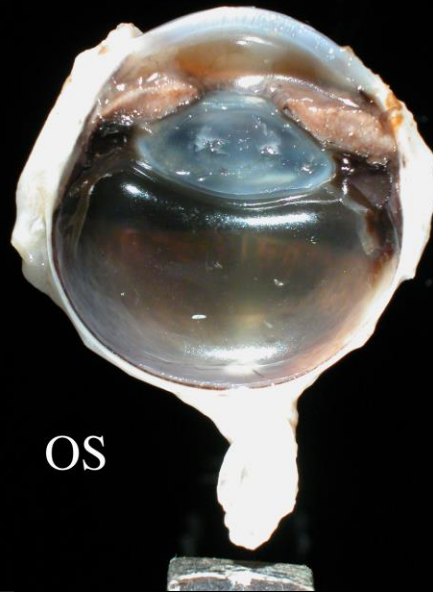
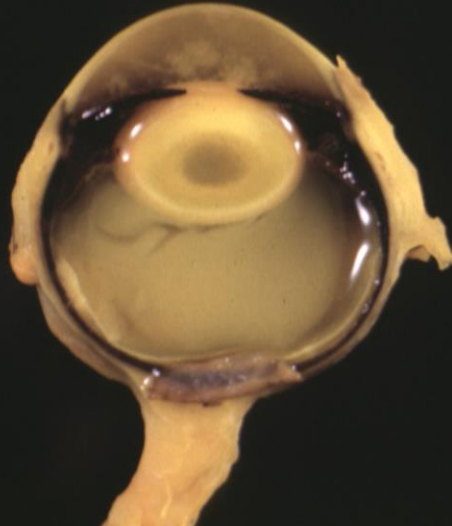
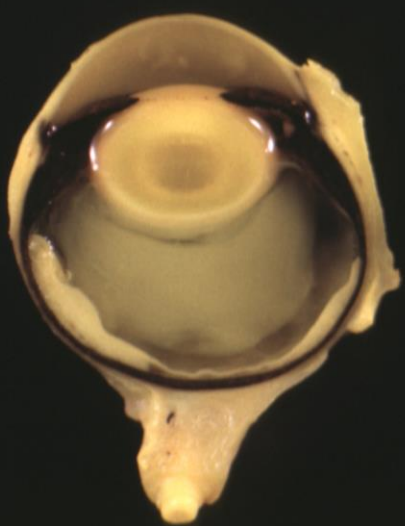
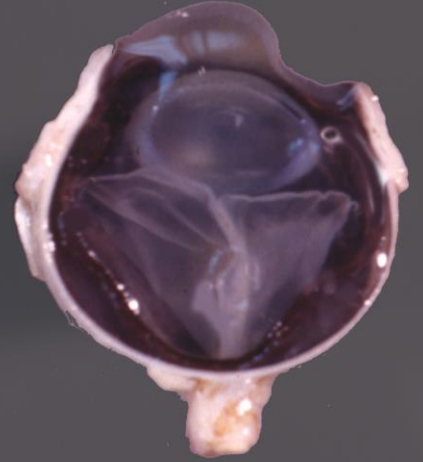
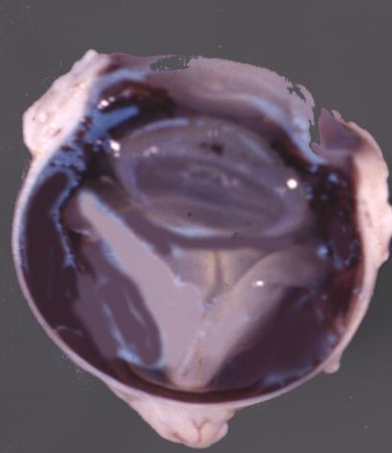
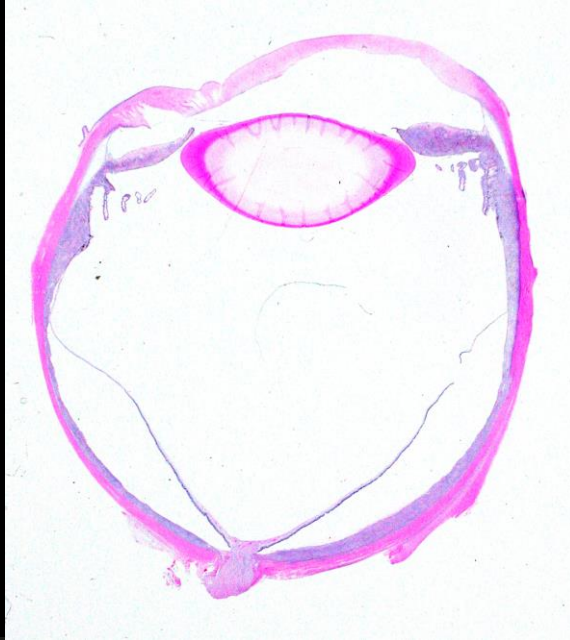In submitted cases, skin involvement is rarely described

Canine Uveodermatologic Syndrome
VKH
Depigmentation

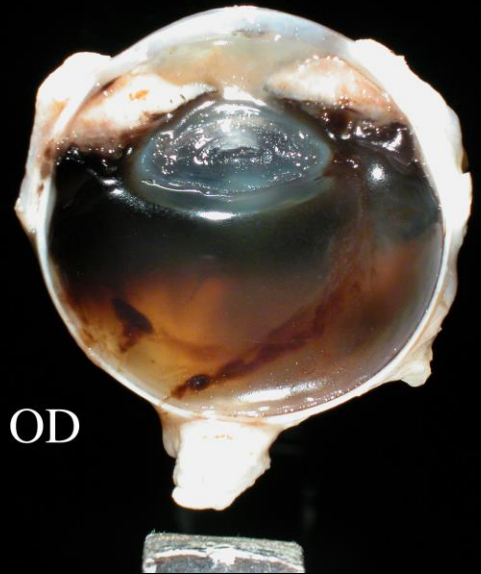


Canine Uveodermatologic Syndrome

VKH

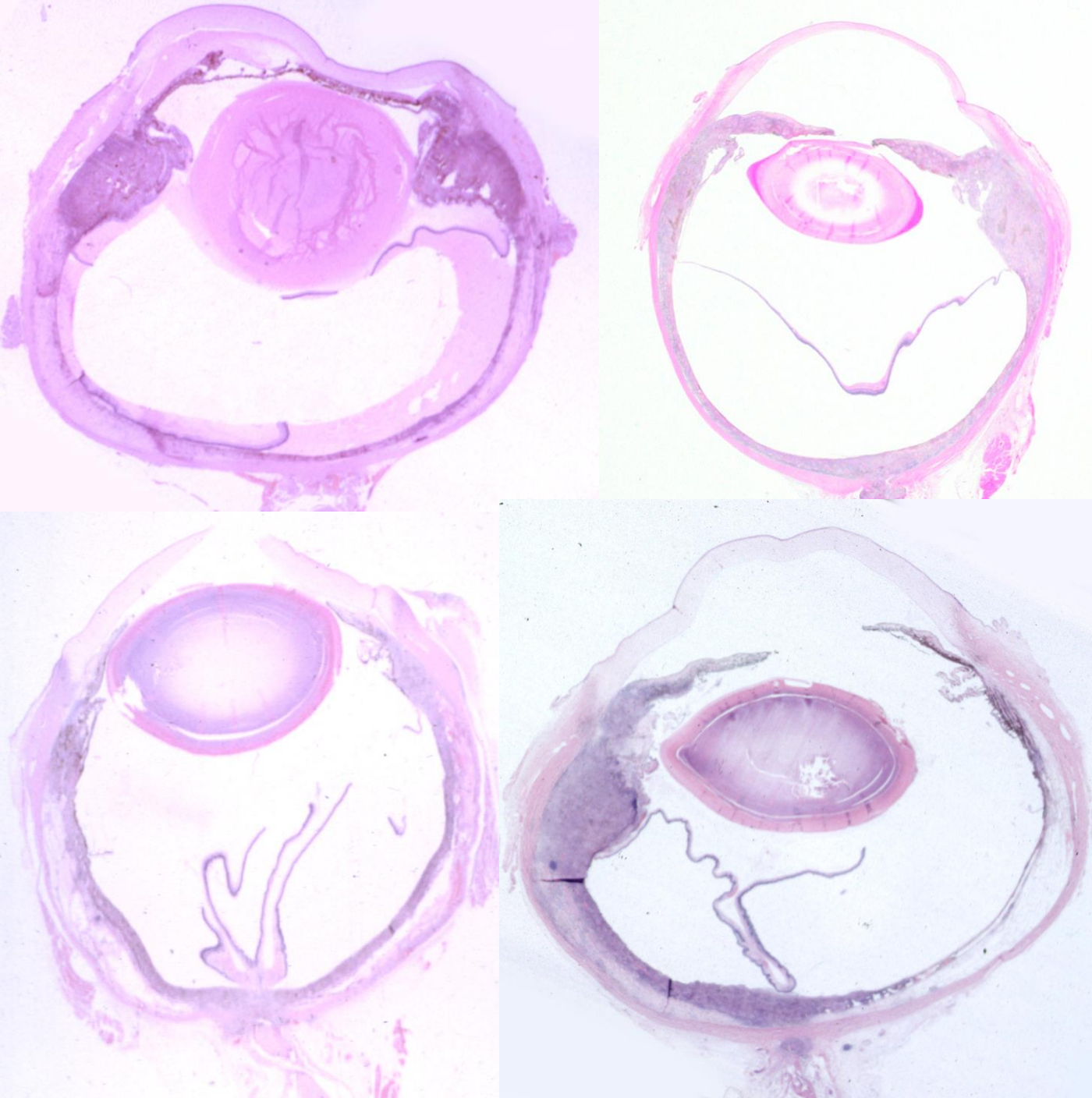


OS

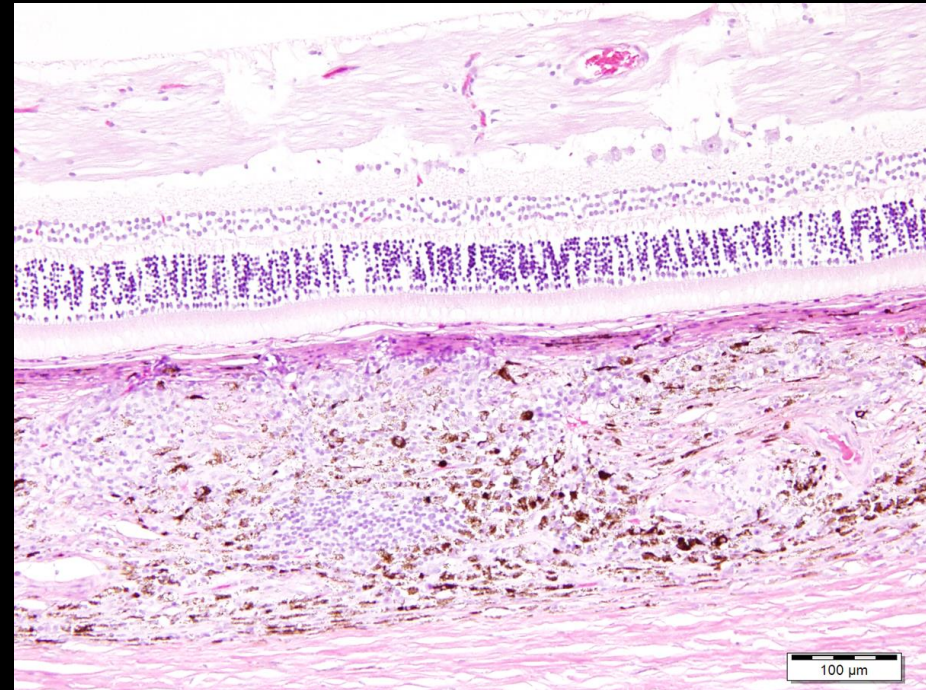
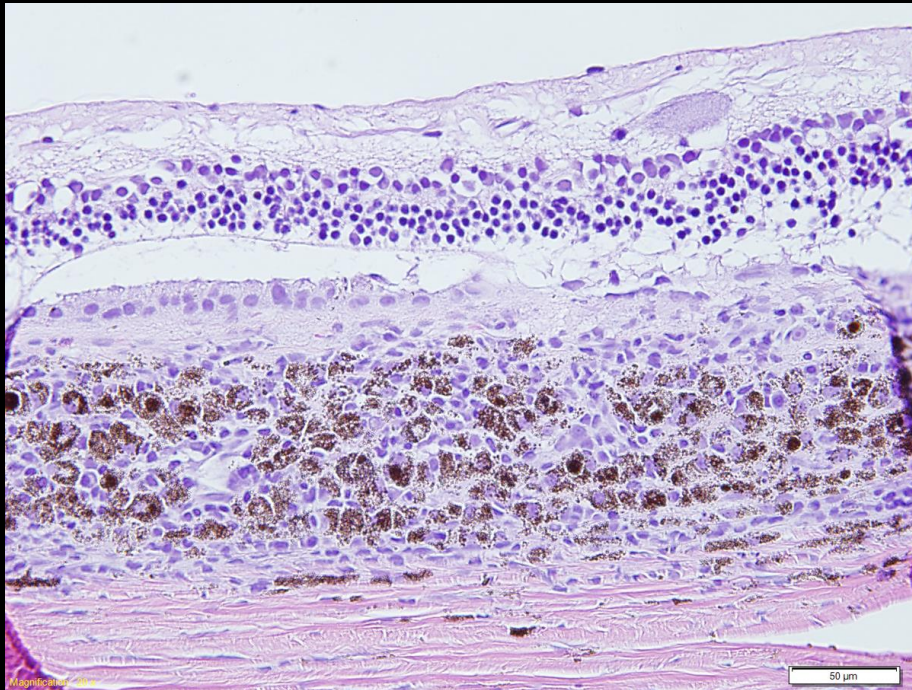


OD

Canine VKH

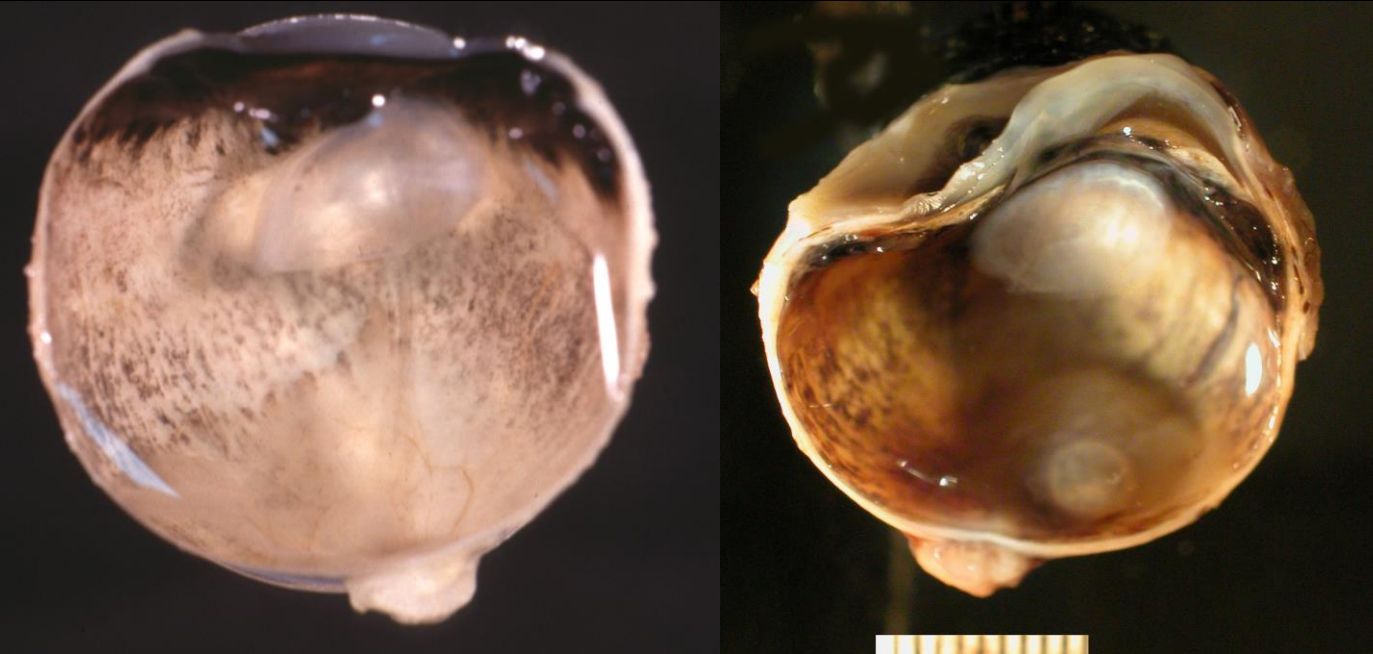

Canine Uveodermatologic Syndrome VKH

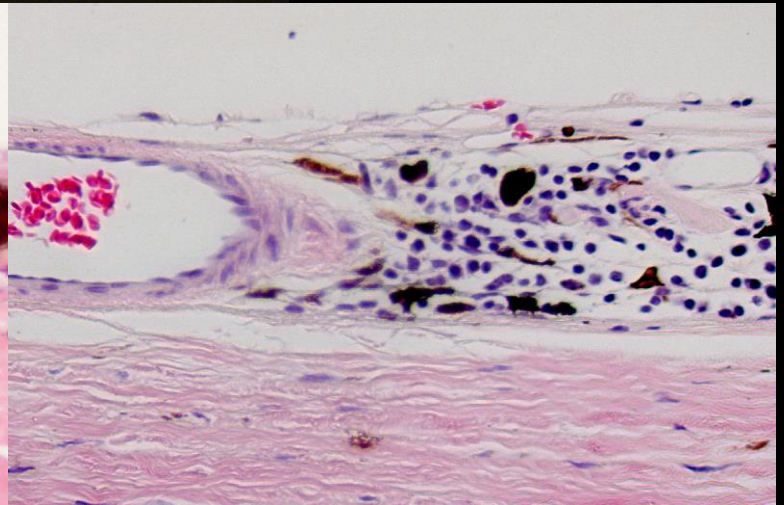
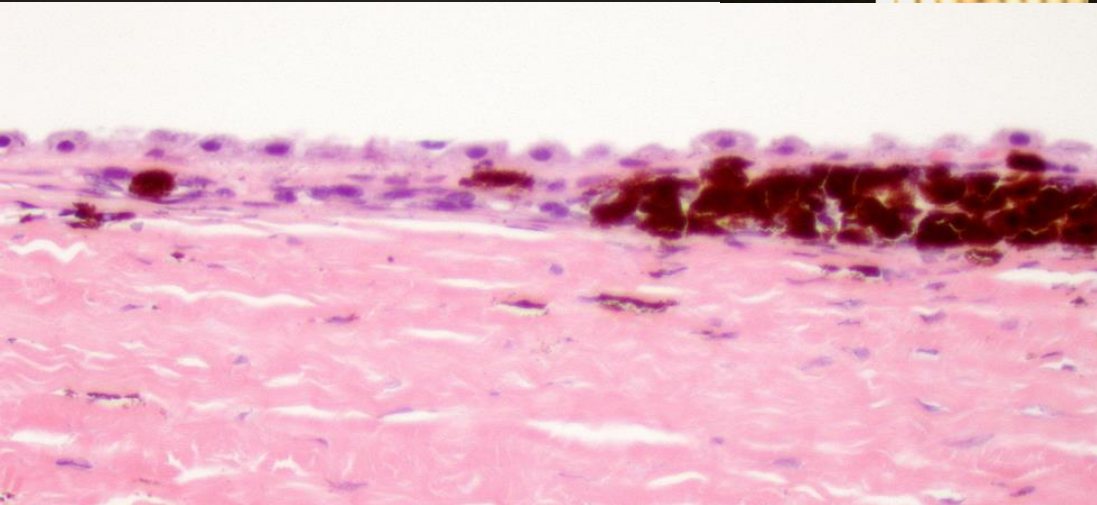


Lymphoplasmacytic and granulomatous choroiditis sparing the retina

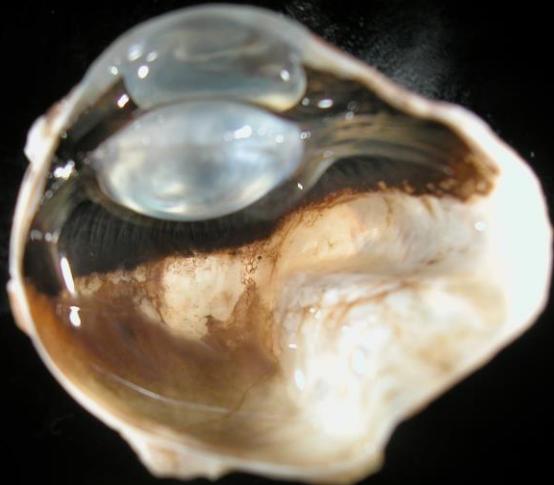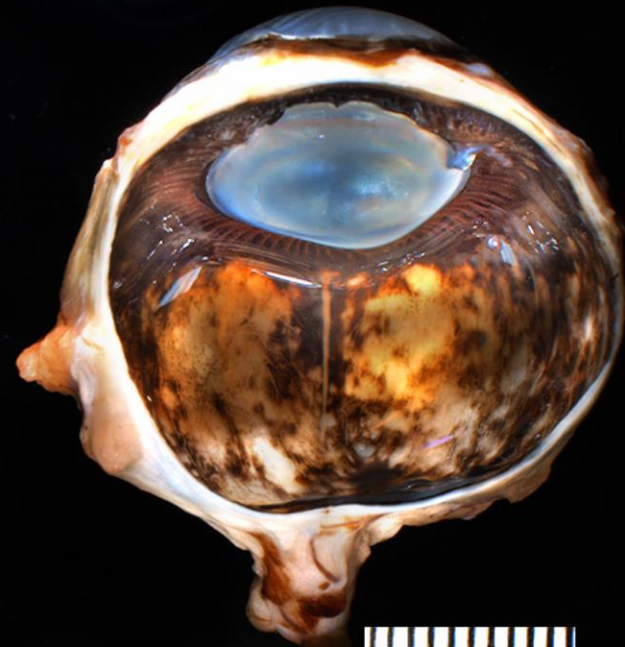
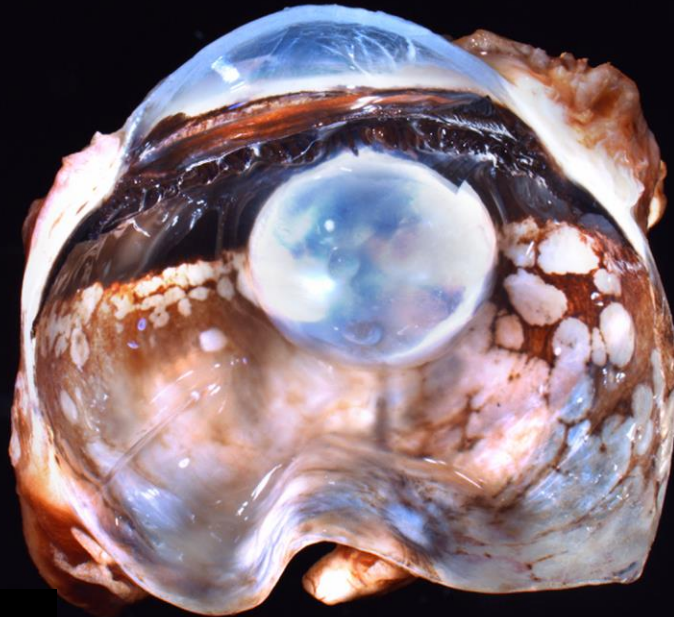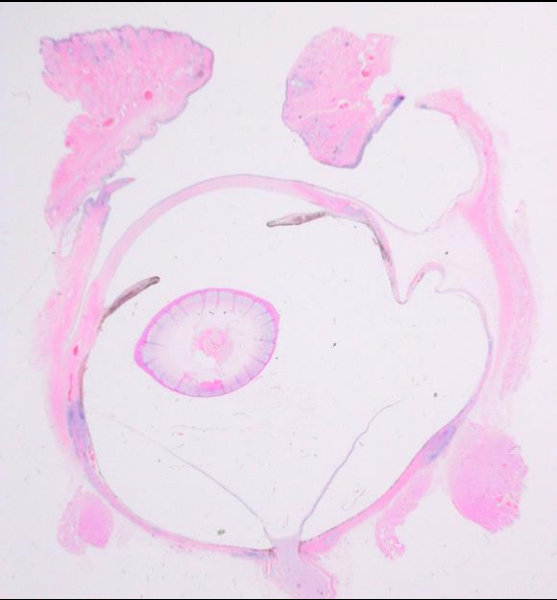
Canine Uveodermatologic Syndrome VKH



Minimal inflammation
along with marked
depigmentation
consider VKH



Uveitis, depigmentation and scleritis with ectasia



Canine Granulomatous Scleritis

“Necrotizing Scleritis”

117 cases: 22 mixed breeds, 14 Cocker Spanials, 8 Rottweilers, 7 Goldens, 5 Labs, nothing else more than 3 cases per breed

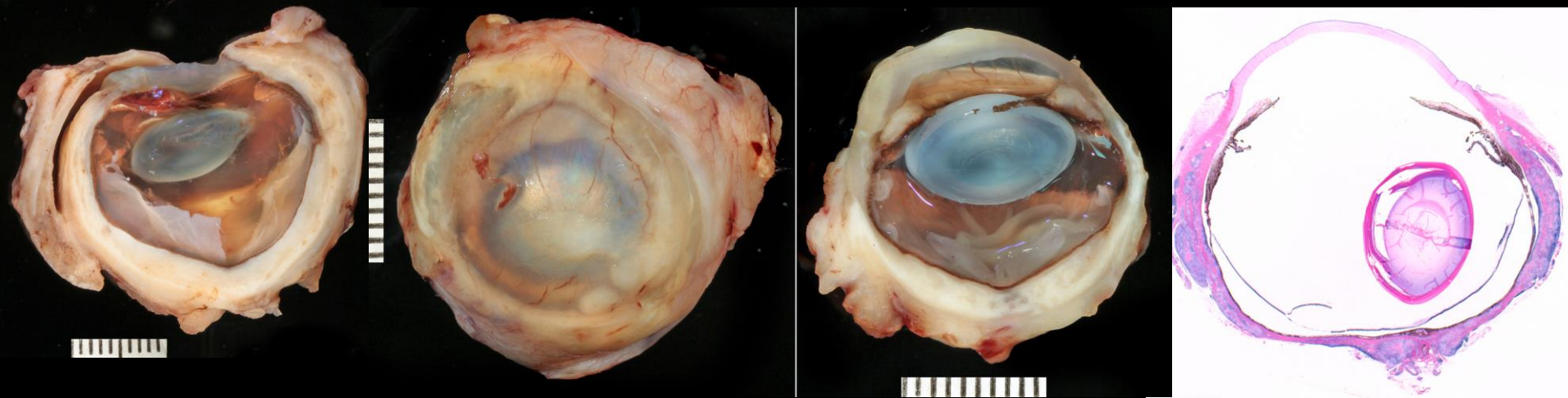
70 Females and 45 Males

The second eye is at risk

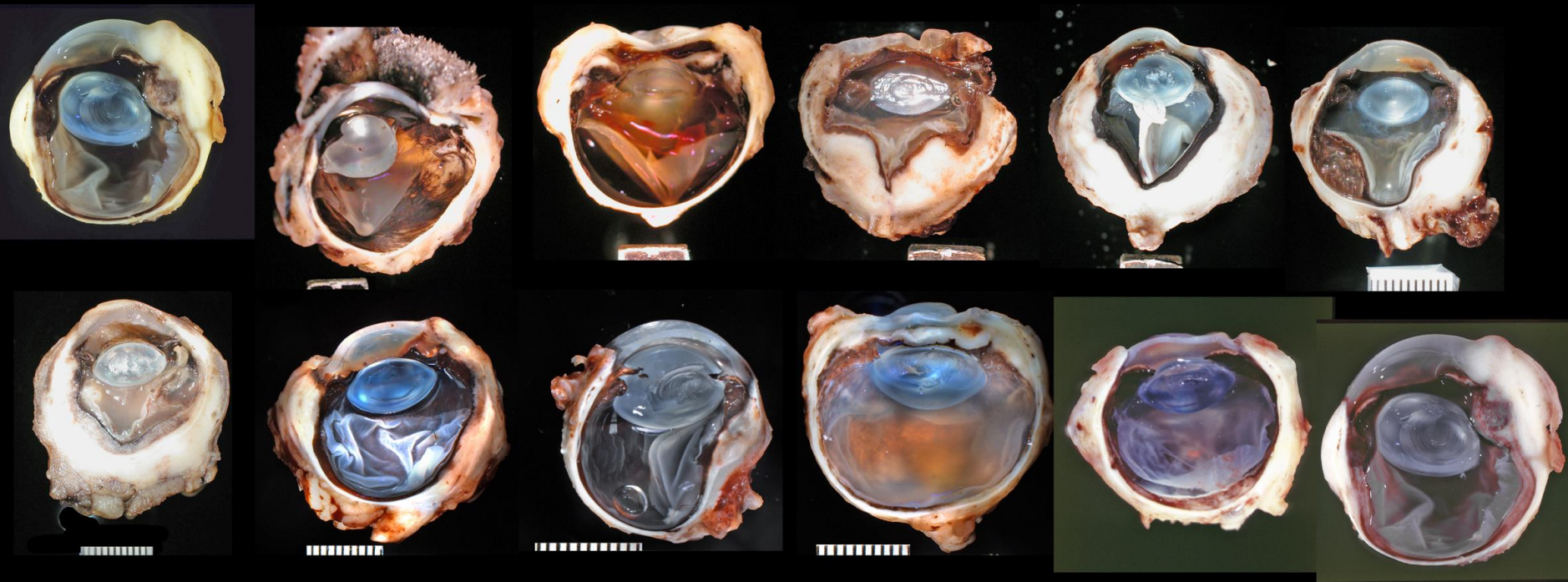
Canine Granulomatous Scleritis

Necrotizing scleritis

- The disease is defined by the scleral predilection
- You may see granulomatous uveitis, like VKH
- You may see episcleritis, like NGE

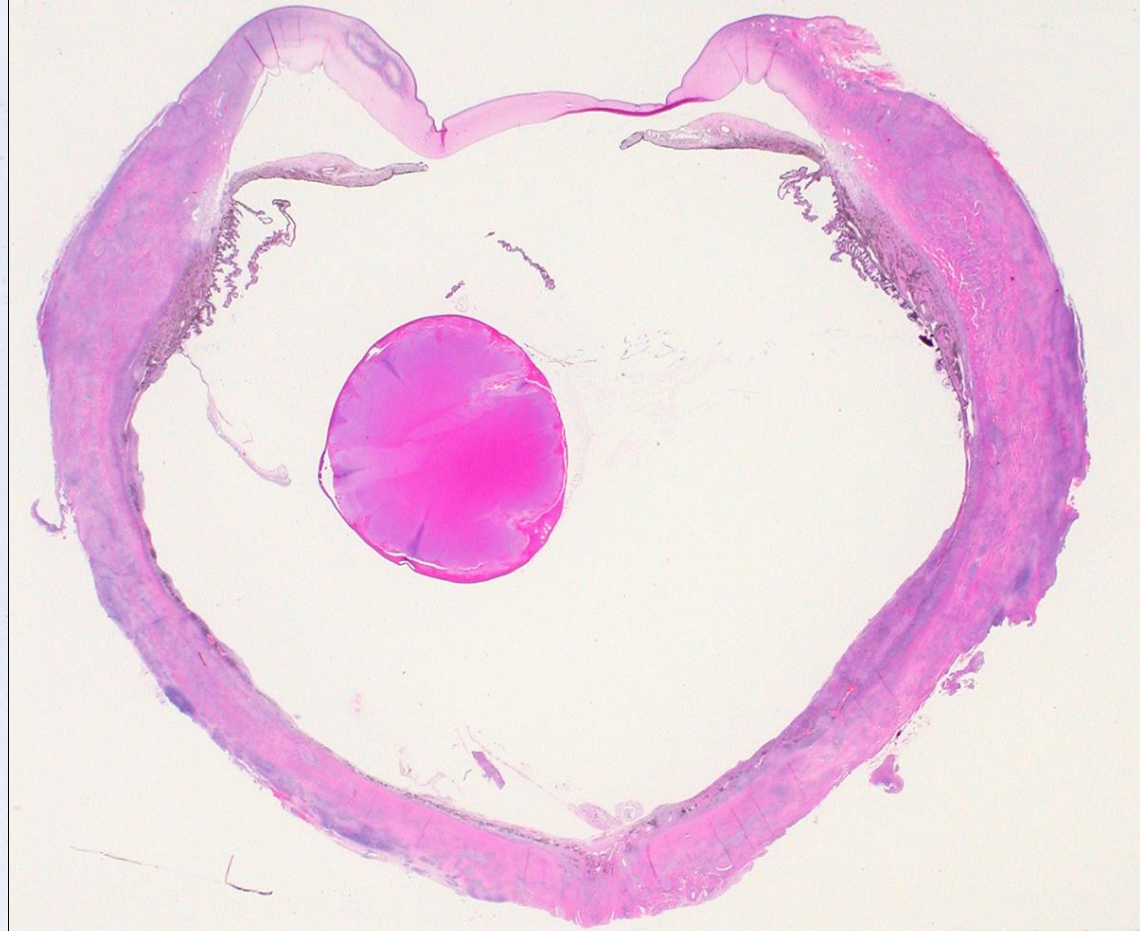
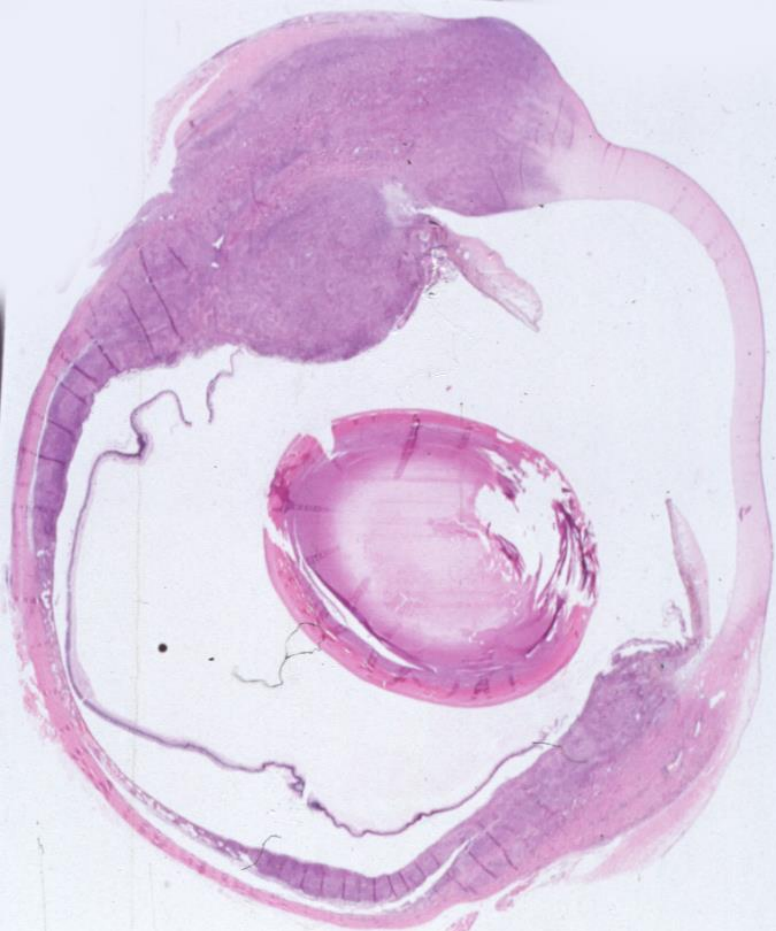


Granulomatous Scleritis



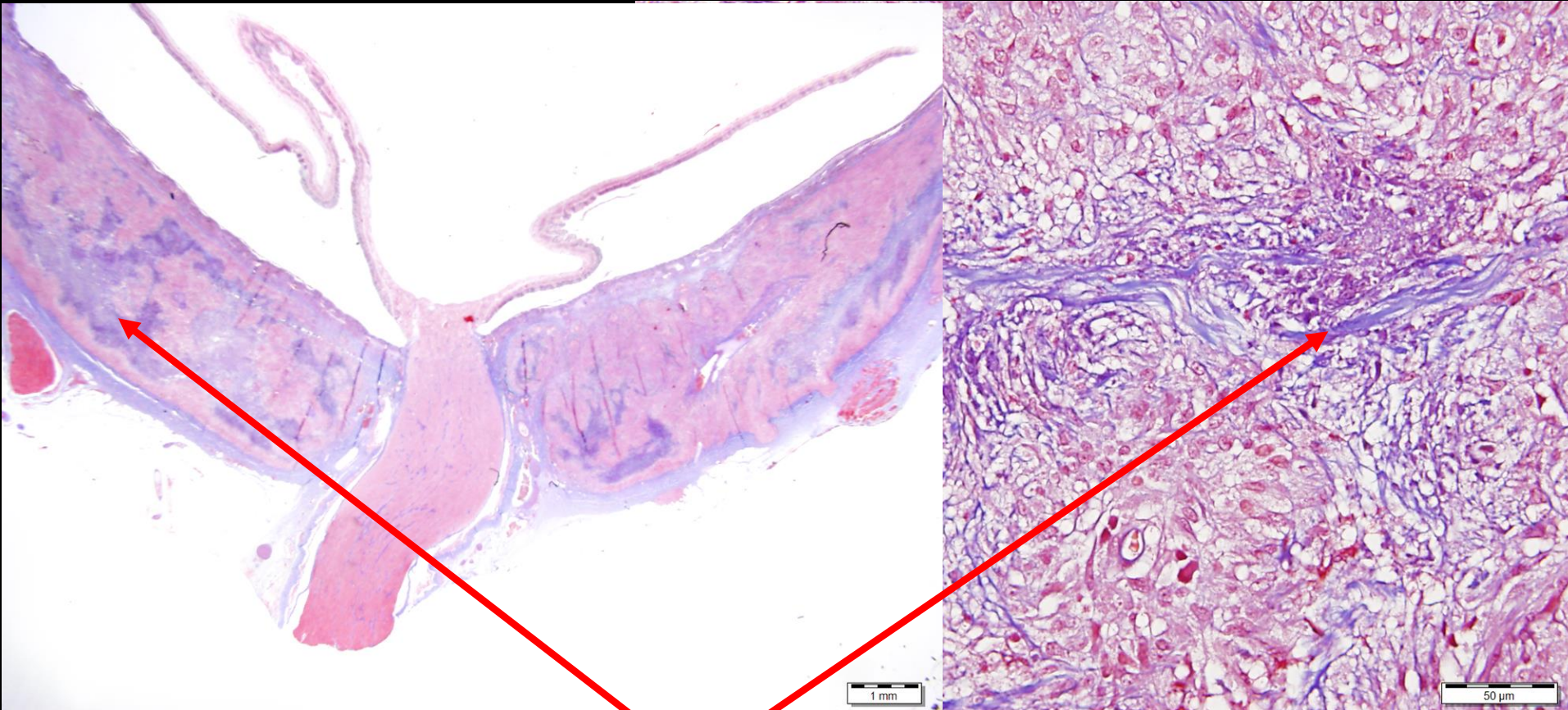
Canine Granulomatous Scleritis

Necrotizing scleritis



Canine Granulomatous Scleritis

Necrotizing scleritis



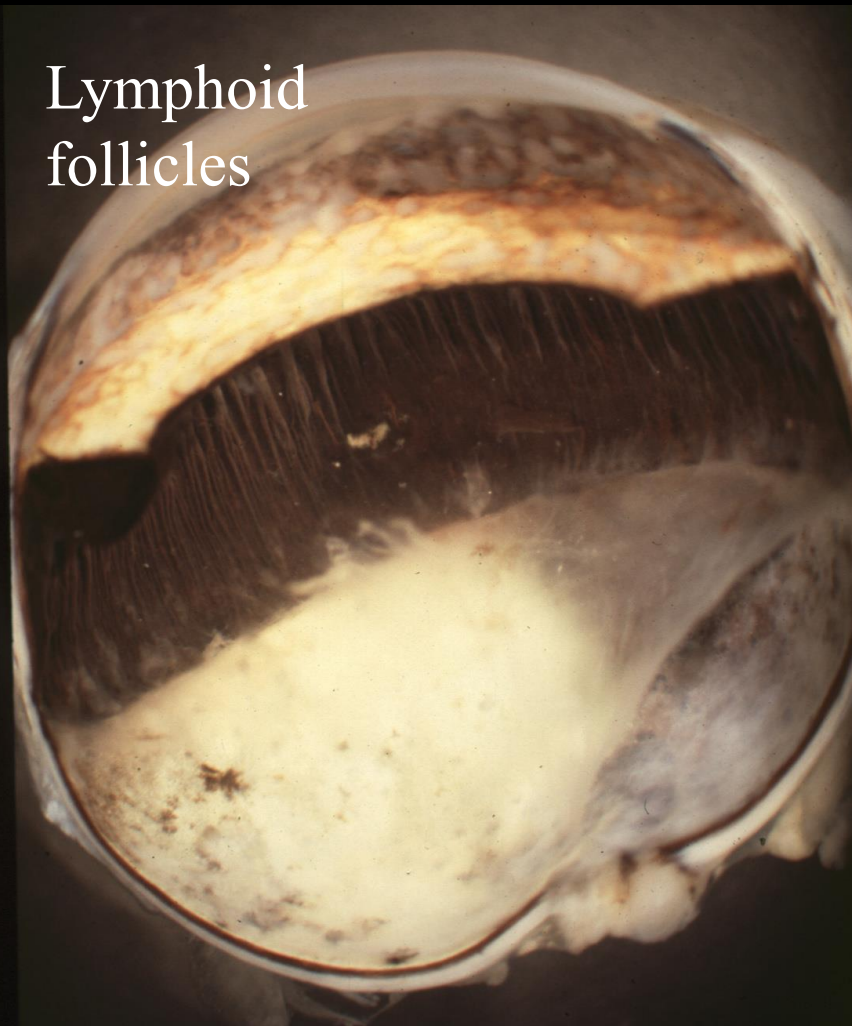
Trichrome stain shows collagenocentric pattern of inflammation

Feline Lymphoplasmacytic Uveitis (L/P Uveitis)

- 1114 cases out of 10,248 total feline cases (10%)
- Second most common disease associated with glaucoma in the COPLOW pathology collection (70% of L/P uveitis submissions have glaucoma also)
- There is vitreous degeneration that is underemphasized in this disease
- About 10% have lens protein in the anterior vitreous, secondary to rupture/leakage at the level of the posterior pole
- Many possible causes have been studied or suggested, but the cause is surely nonspecific and multifactorial

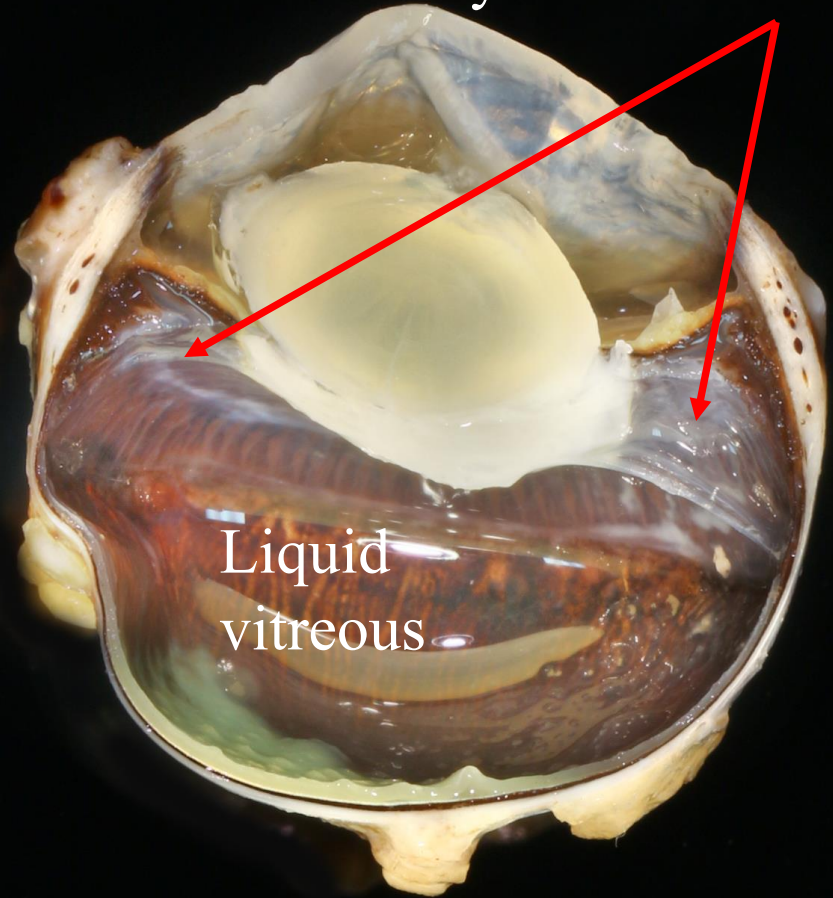
Feline Lymphoplasmacytic Uveitis (L/P Uveitis)

Lymphoid
follicles

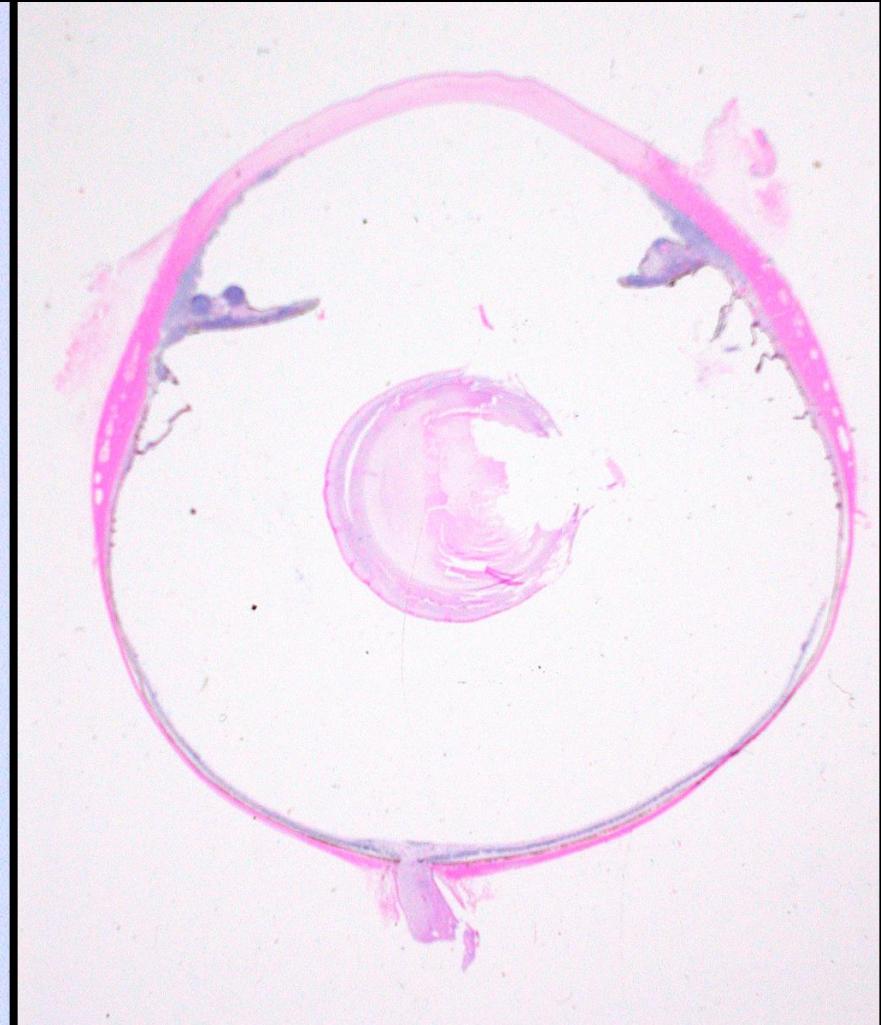
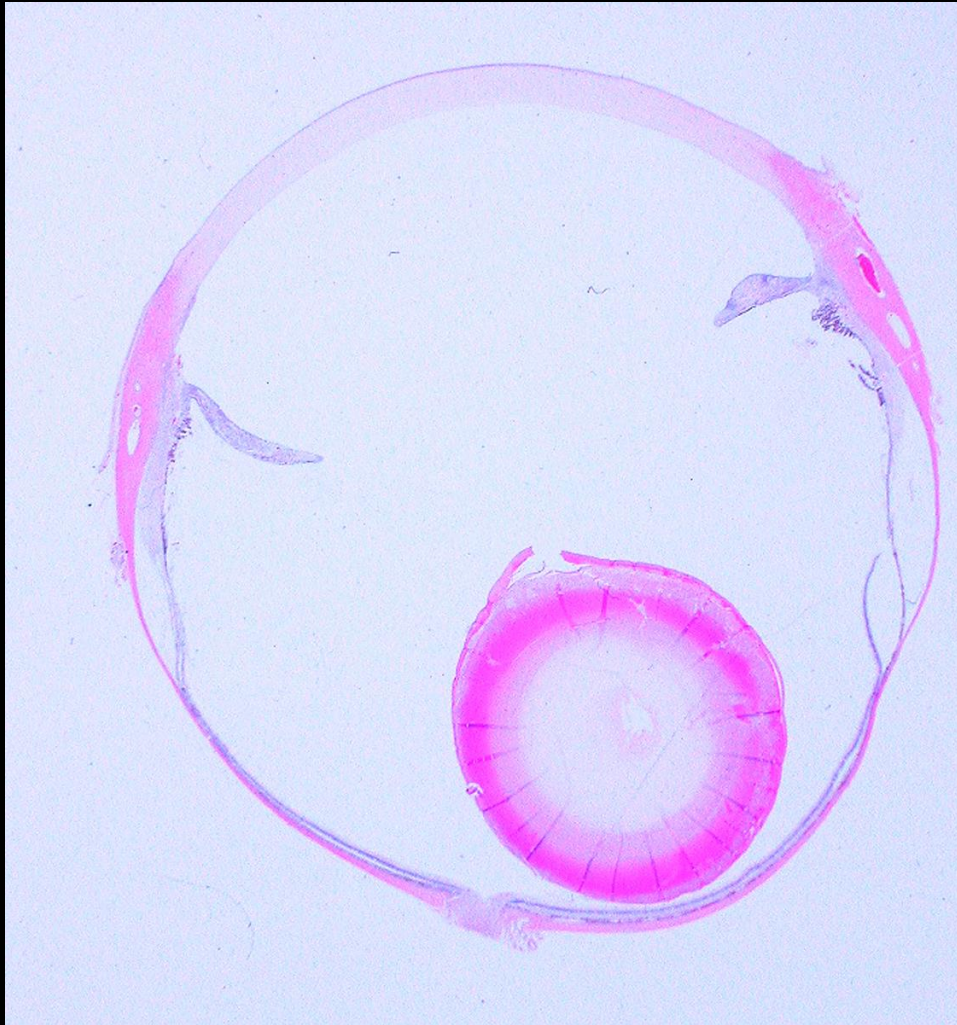


Cyclitic membranes

Liquid
vitreous

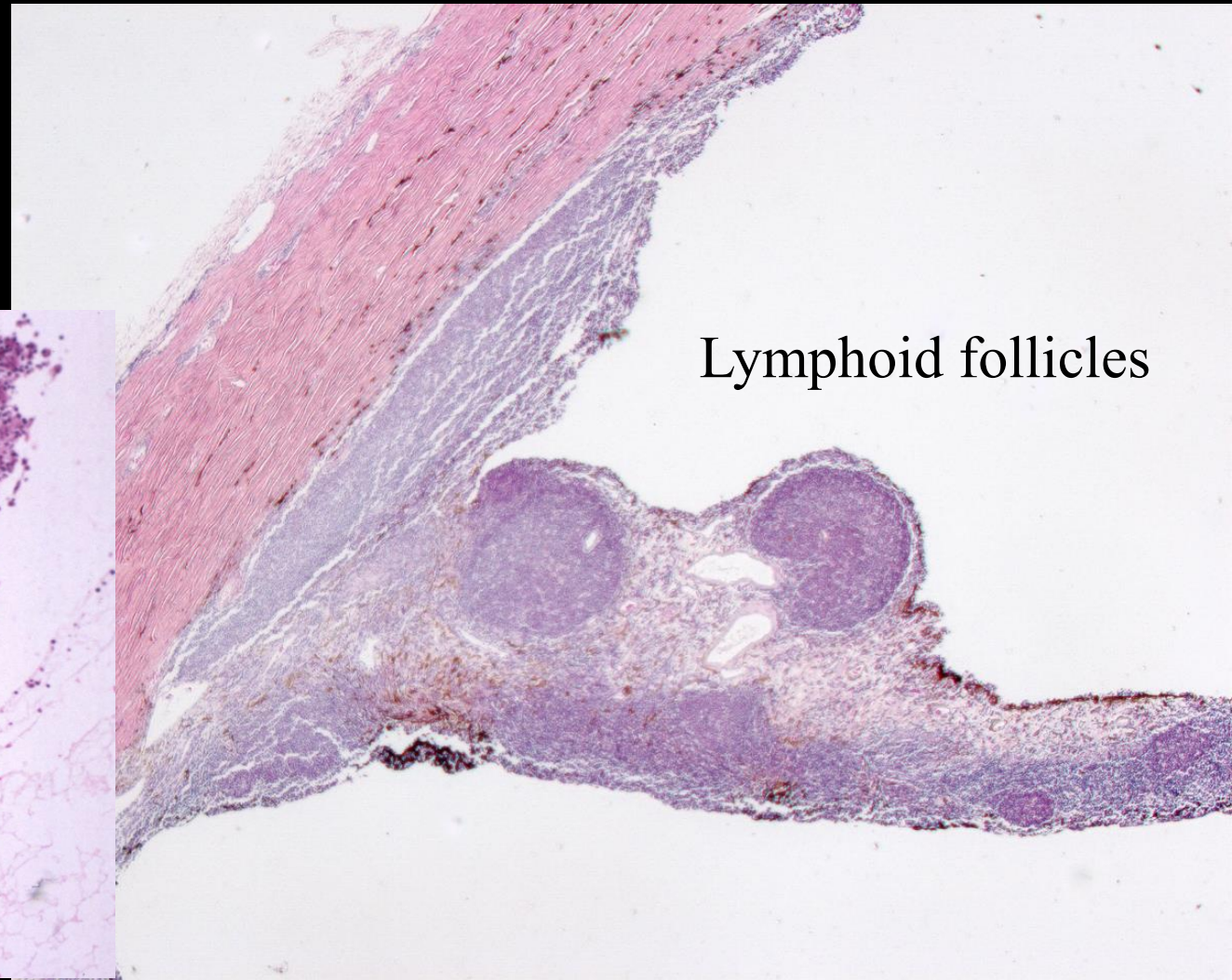
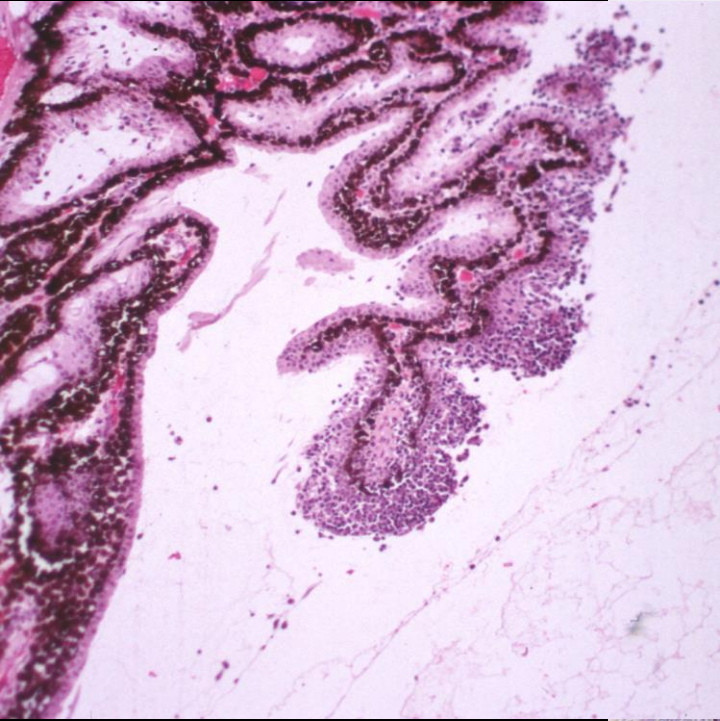


Feline Lymphoplasmacytic Uveitis (L/P Uveitis)



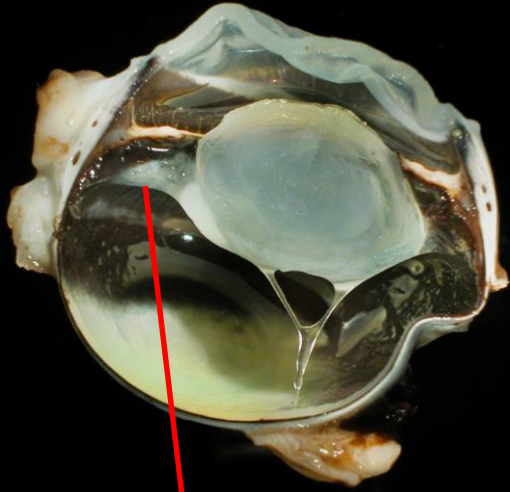
Feline Lymphoplasmacytic Uveitis (L/P Uveitis)

Lymphoid cells
in the ciliary epithelium

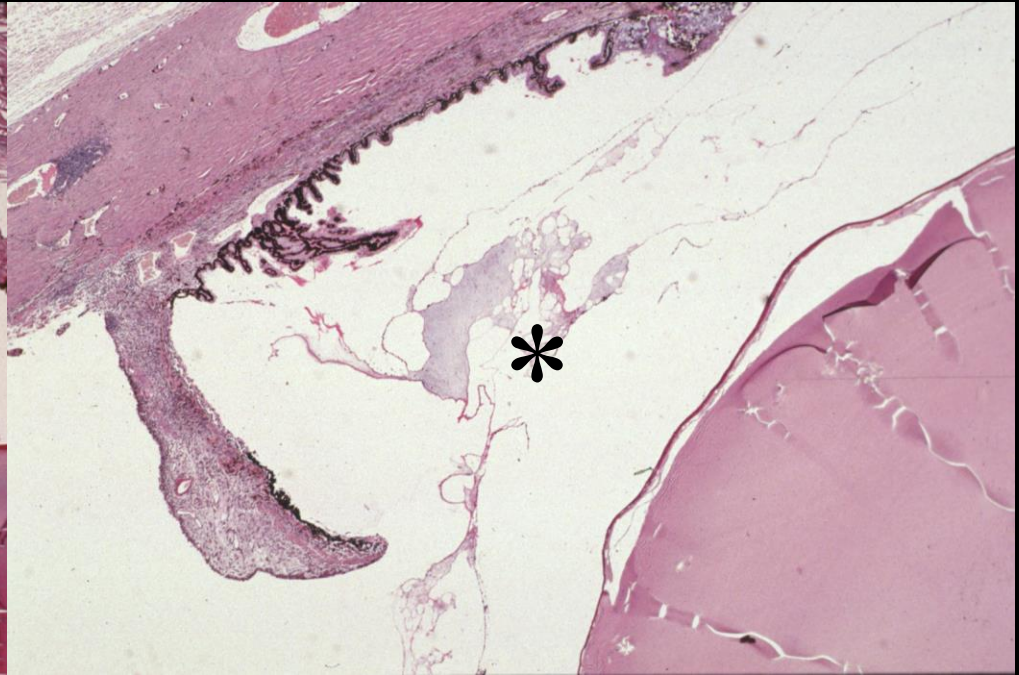
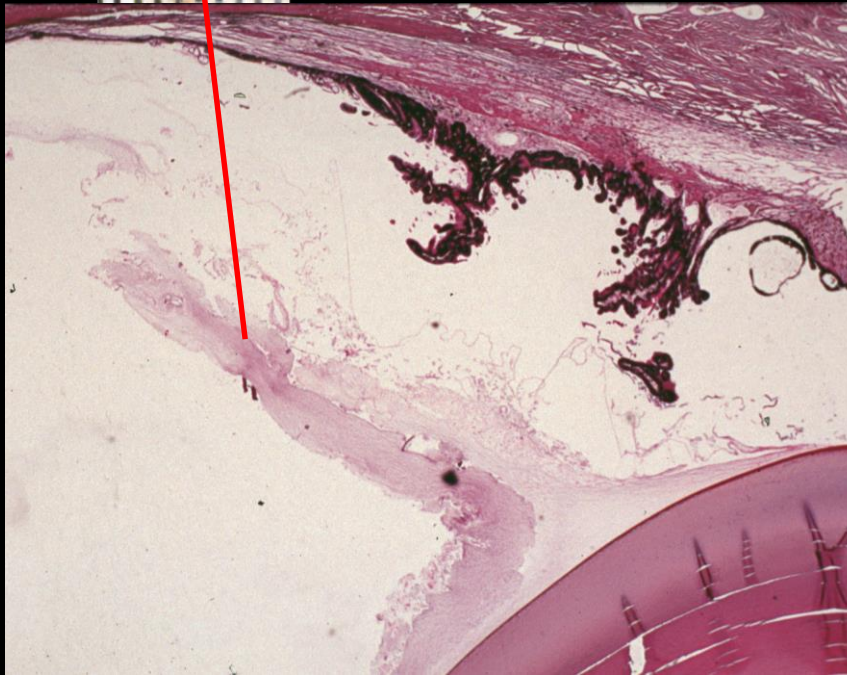


Lymphoid follicles

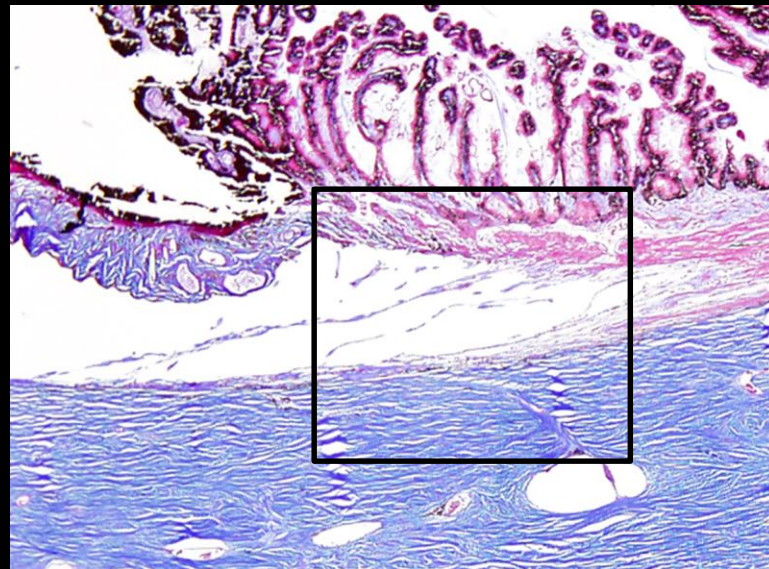
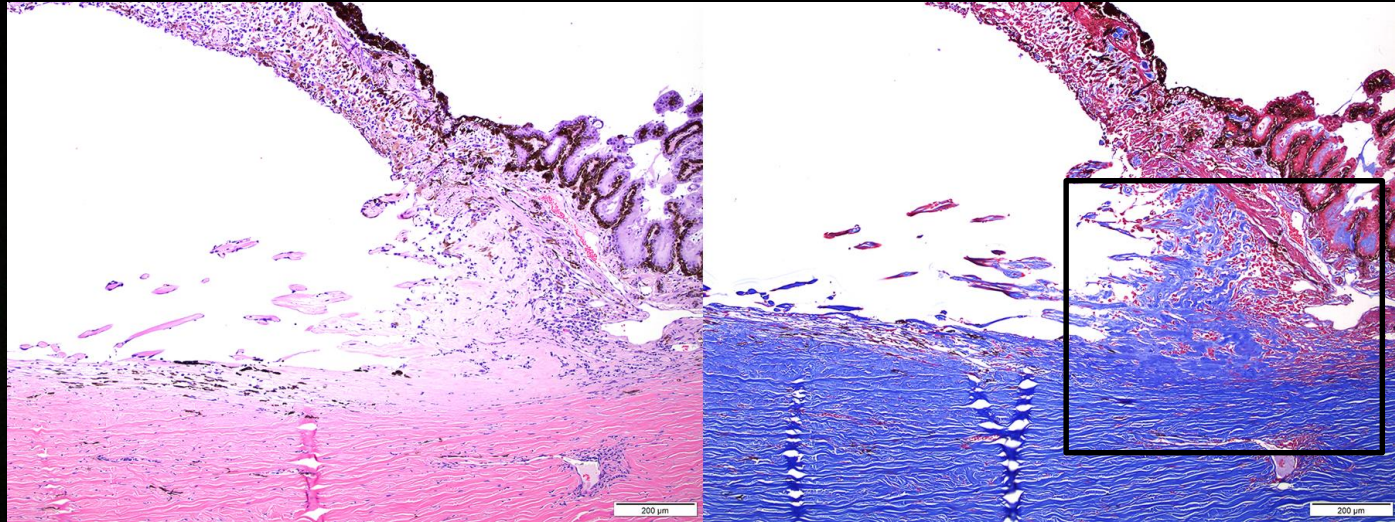
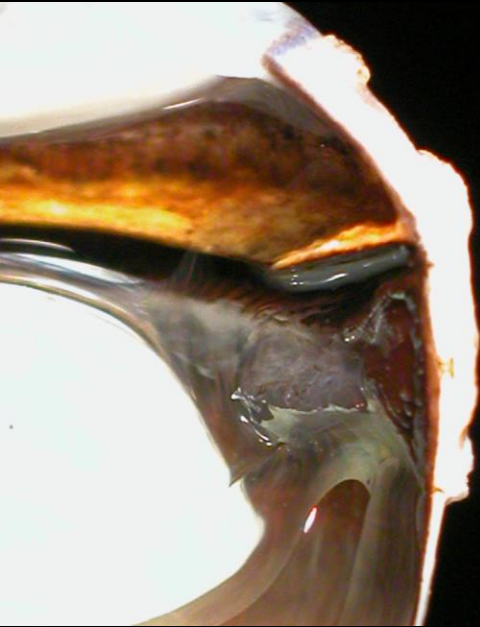
Feline Lymphoplasmacytic Uveitis (L/P Uveitis)



Cyclitic membranes

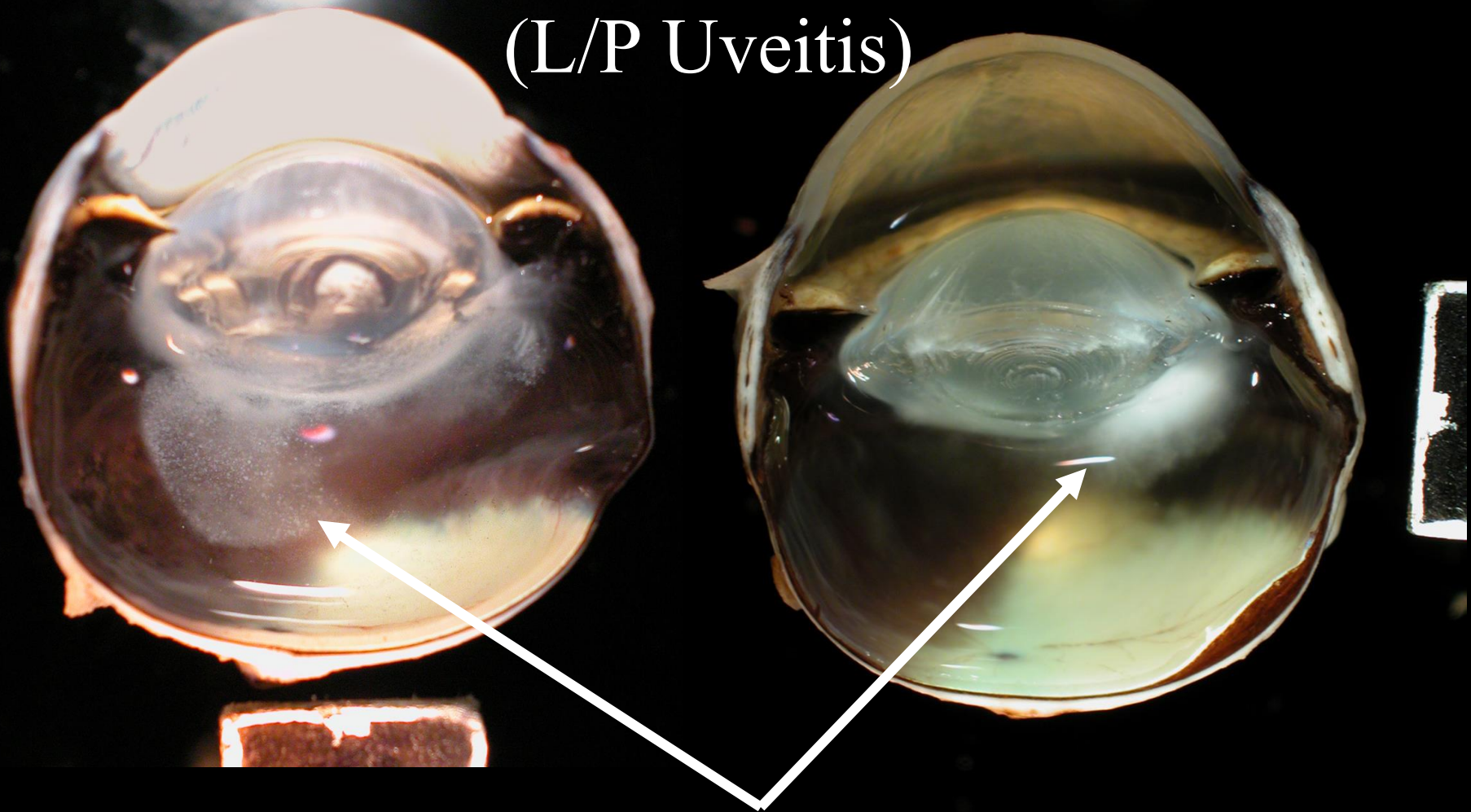


Feline Lymphoplasmacytic Uveitis (L/P Uveitis)



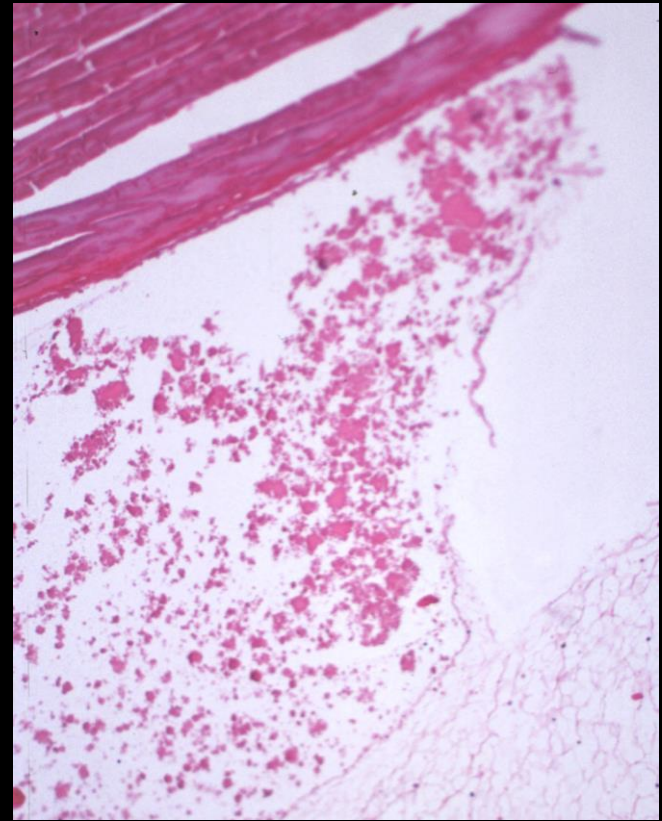
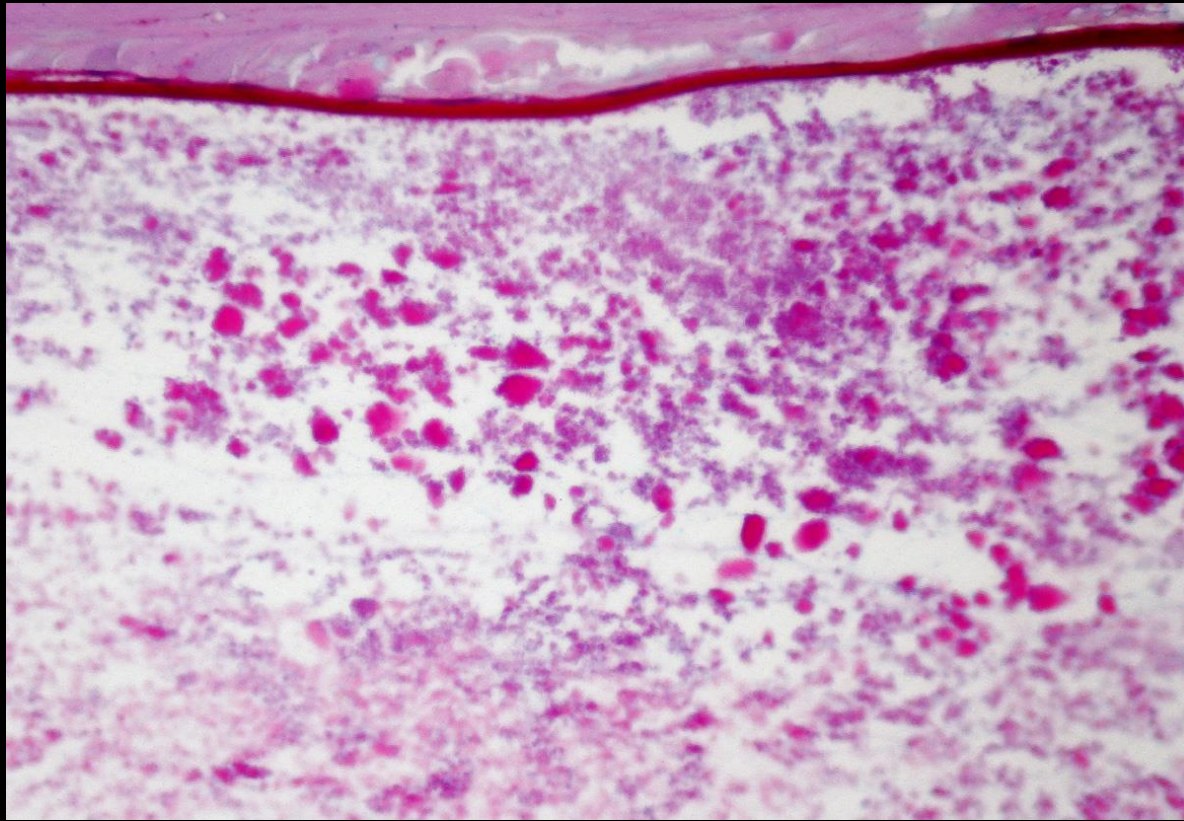
Fibrosis of the corneoscleral
trabecular meshwork:
*possible cause of glaucoma
in some cats with l/p uveitis*

Feline Lymphoplasmacytic Uveitis (L/P Uveitis)



Lens Protein

Feline Lymphoplasmacytic Uveitis (L/P Uveitis)



Hyper-eosinophilic protein granules interpreted as lens protein

Lymphoplasmacytic Uveitis in Cats by Sex

| Feline Lymphoplasmacytic Uveitis | | | | | |
|----------------------------------|-----|---|-----------------------------|----|---|
| No Granular Protein n = 1009 | | | Granular Protein n = 113 | | |
| 26.1% | 263 | F | 21.2% | 24 | F |
| 2.7% | 27 | i | 21.2% | 24 | s |
| 23.3% | 235 | s | 75.2% | 85 | M |
| 0.1% | 1 | X | 2.7% | 3 | i |
| 70.5% | 711 | M | 72.6% | 82 | n |
| 4.7% | 47 | i | 3.5% | 4 | X |
| 65.8% | 664 | n | 3.5% | 4 | X |
| 3.5% | 35 | X | | | |
| 3.5% | 35 | X | | | |

Total cats: 41% Female & 54% Male
n = 10,300

Melanoma: 45% Female & 52% Male
n = 2763

Strong Male Bias

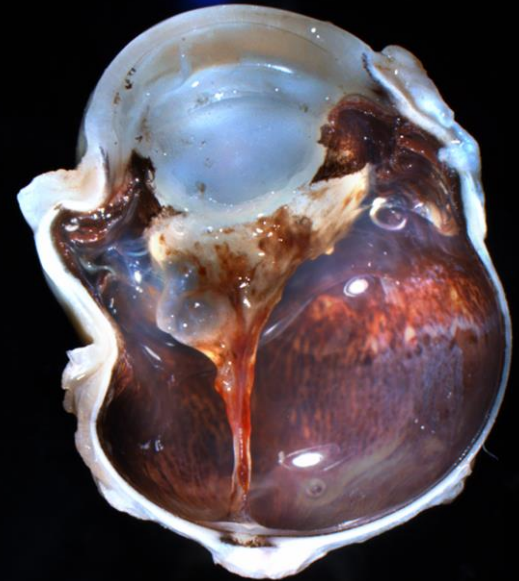
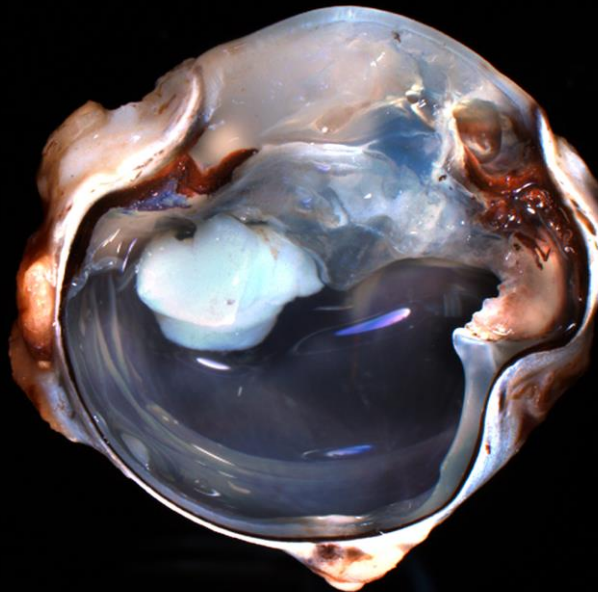
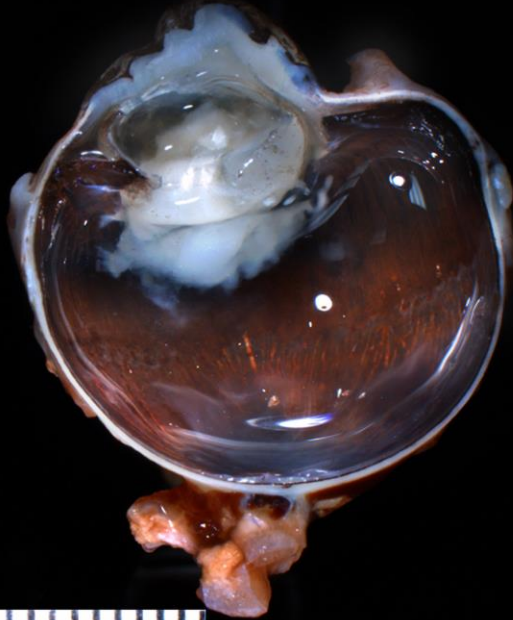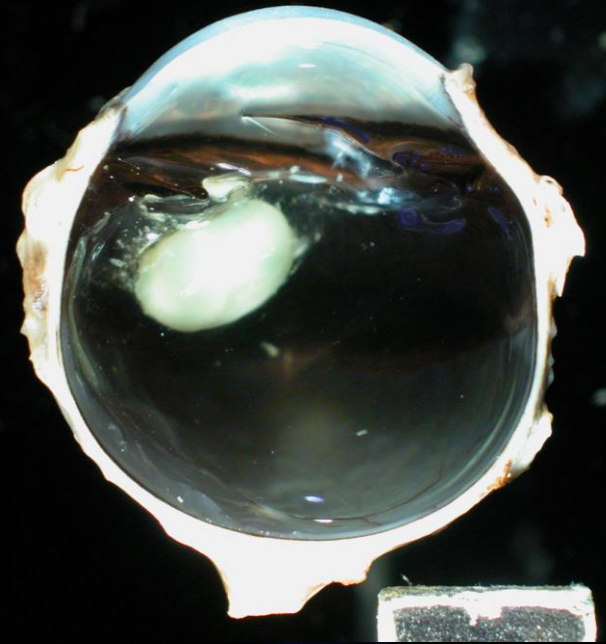
Lens Induced Inflammation

The Phacitis Syndromes

- Lens Induced Uveitis (**Phacolytic Uveitis**)
 - Hypermature cataract
 - Results in synechia followed by possible glaucoma
- Septic Implantation Syndrome
 - Cat Scratch
 - Bacteria embedded in the lens tissue
- **Phacoclastic uveitis**
 - Bland phacophagocytic inflammation
 - Lens capsule rupture or post operative exposure of lens protein
 - Purely a bland macrophage response
 - Asymmetric Uveitis – Non-diabetic
 - Robust pyogranulomatous reaction
 - Carpeting of the uvea, retina, lens, or cornea
 - Small breed dogs with the Poodle being the most common
 - Asymmetric Uveitis – Diabetic variant
 - Robust pyogranulomatous reaction identical to above
 - Miniature Schnauzers are the most common breed

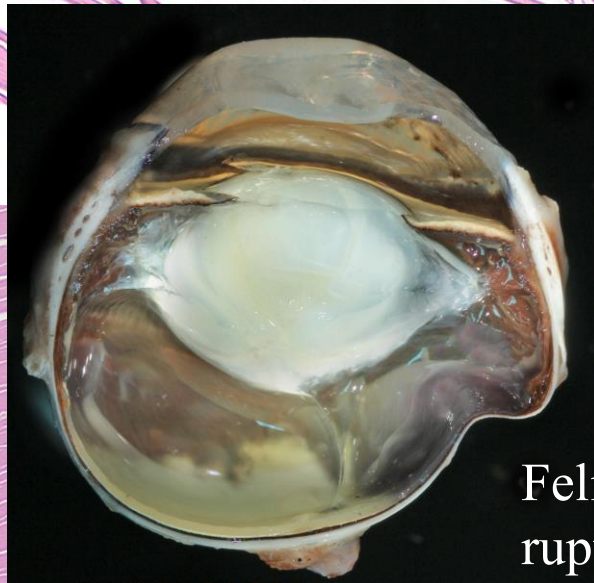
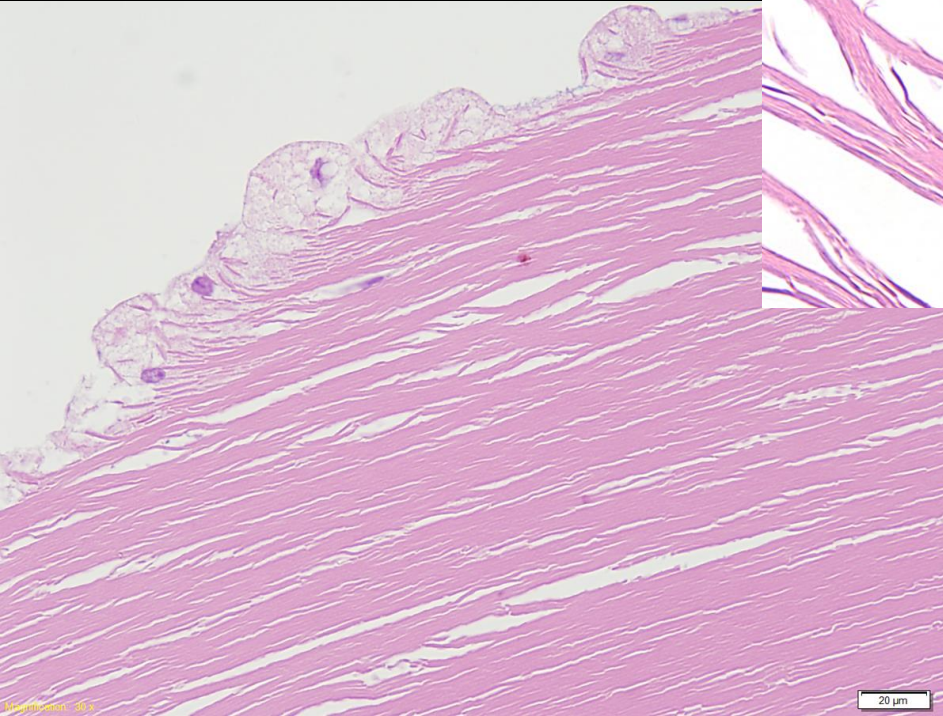
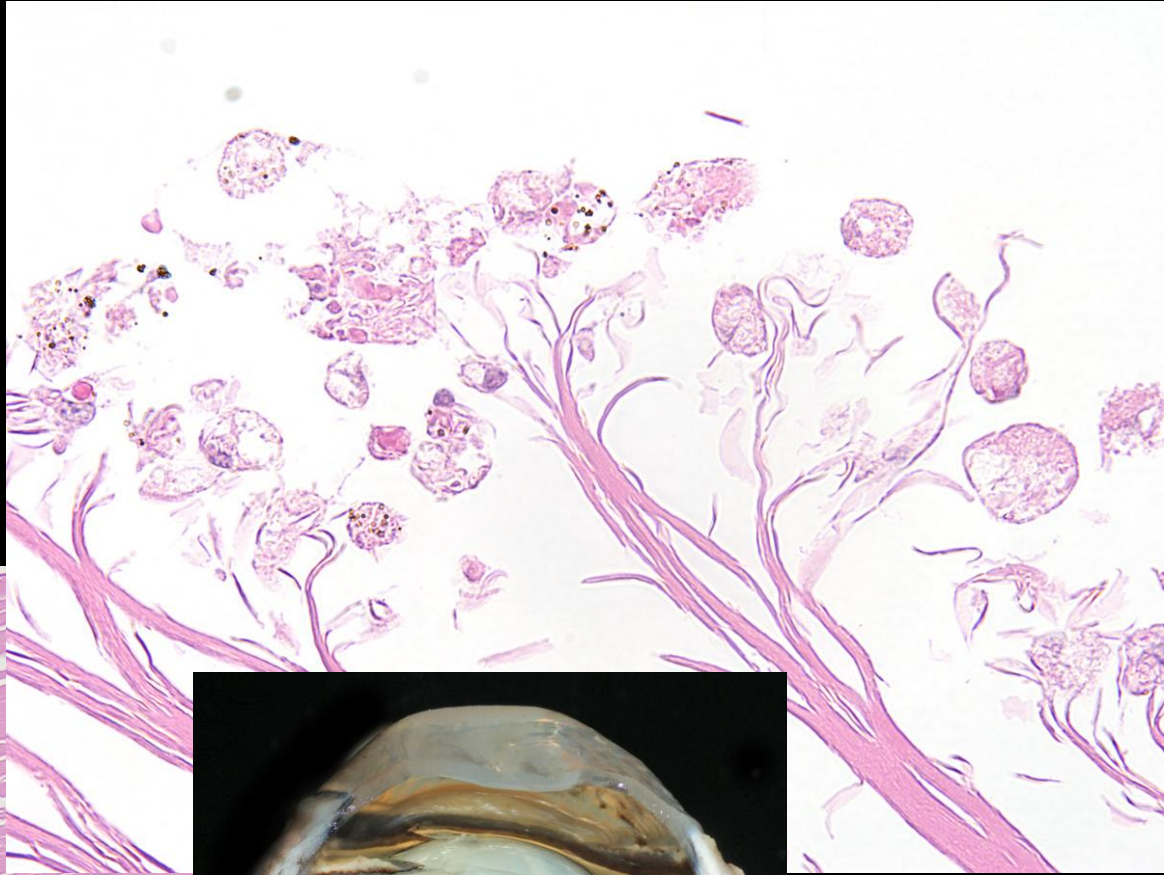
Lens Induced Uveitis Phacolytic *Phacolytic*

Synechia
Traction bands
Glaucoma



Bland Phacoclastic Uveitis

Phacophagocytes



Feline: Lens capsule rupture

20 µm



Asymmetric Uveitis

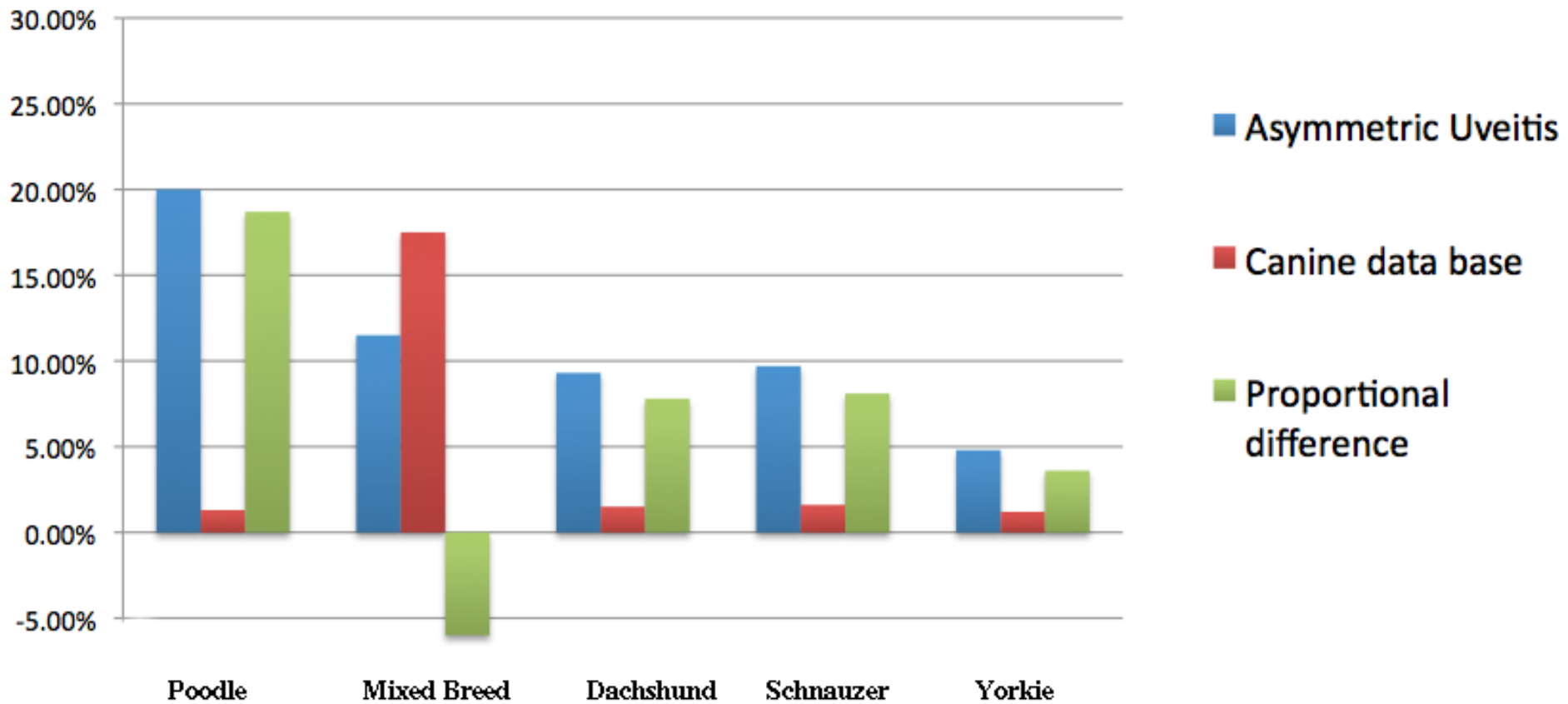
Diabetic and non-diabetic forms

- Pyogranulomatous carpeting of the uvea, retina. Posterior cornea, or lens
- Retinitis and retinal necrosis is common
- Typical Breeds (Diabetic), Total = 82 cases
 - Schnauzer, Bichon, Yorkie, Cairn , Labrador*
- Typical Breeds (Non-diabetic), Total = 237 cases
 - Poodle, Mixed*, Dachshund, Schnauzer, Yorkie
 - * = under-represented
- Typically occurs first in one eye then the other (*Faster in diabetic*)
- Can be prevented or delayed with immune modulation (*Non-diabetic*)

Asymmetric Uveitis

Non-diabetic Breeds

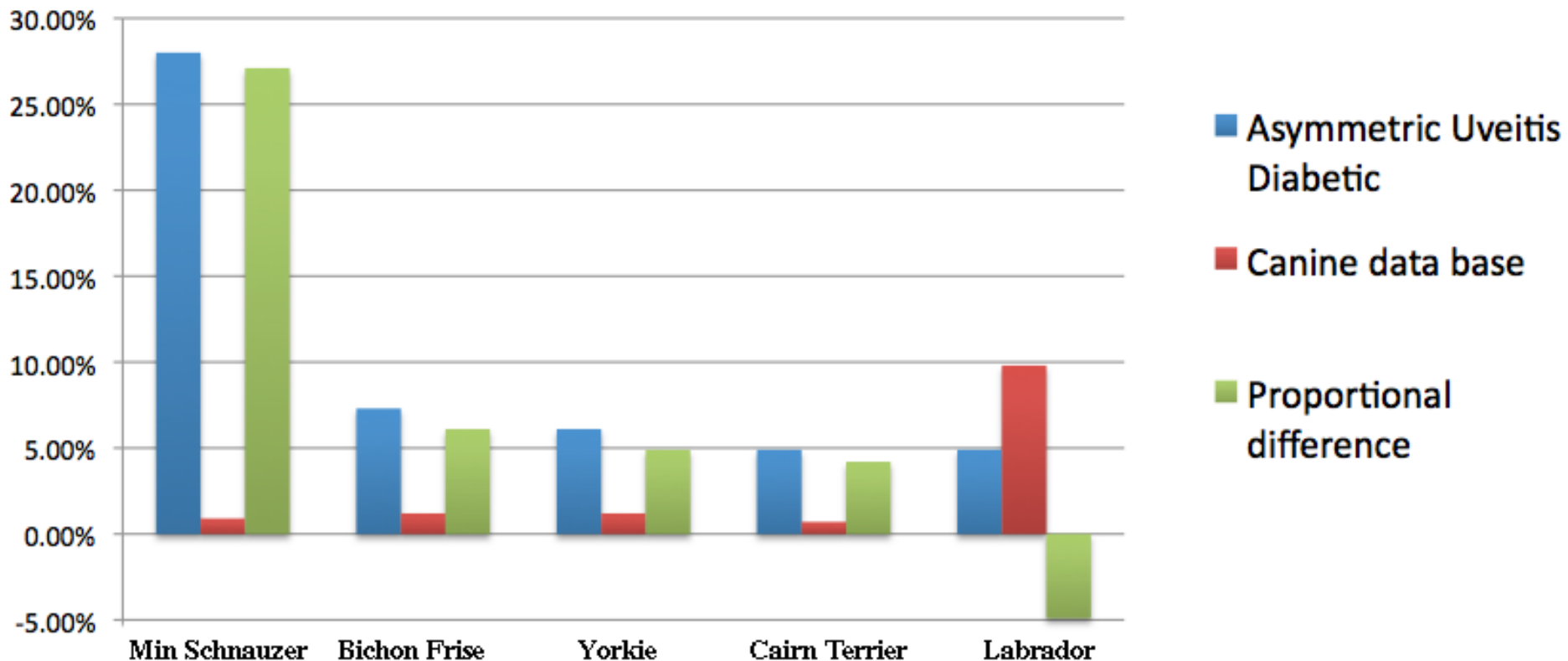
Canine Database - 29,760 records
Asymmetric Uveitis: 237 Records



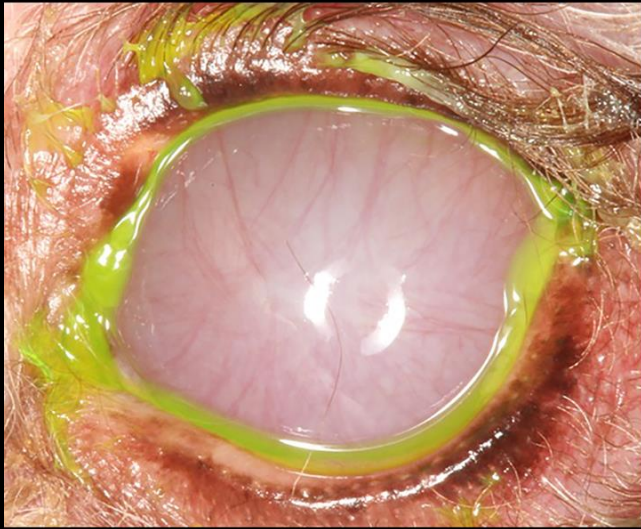
Asymmetric Uveitis

Diabetic Breeds

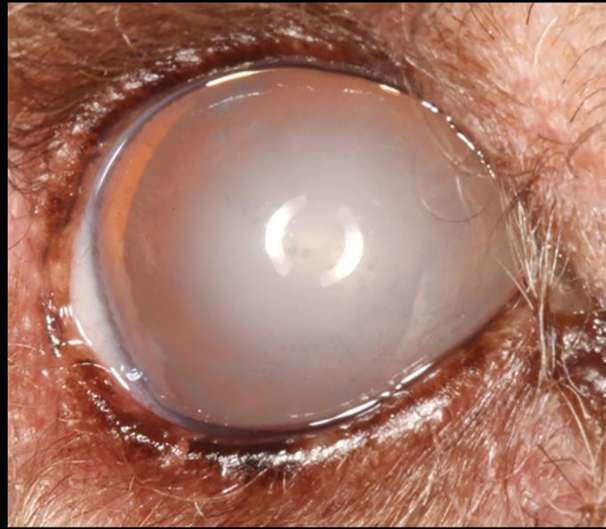Canine data base - 29,760 records
Asymmetric Uveitis - Diabetic Variant: 82 Records



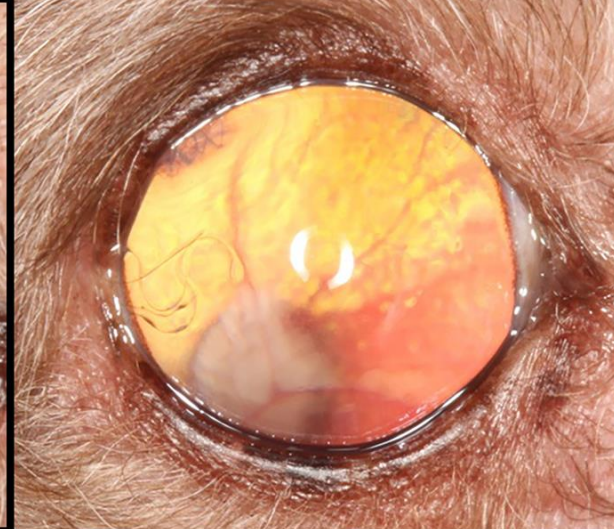Asymmetric Uveitis



**Asymmetric Uveitis
First Eye**



**Second Eye Before
Lens Removal**

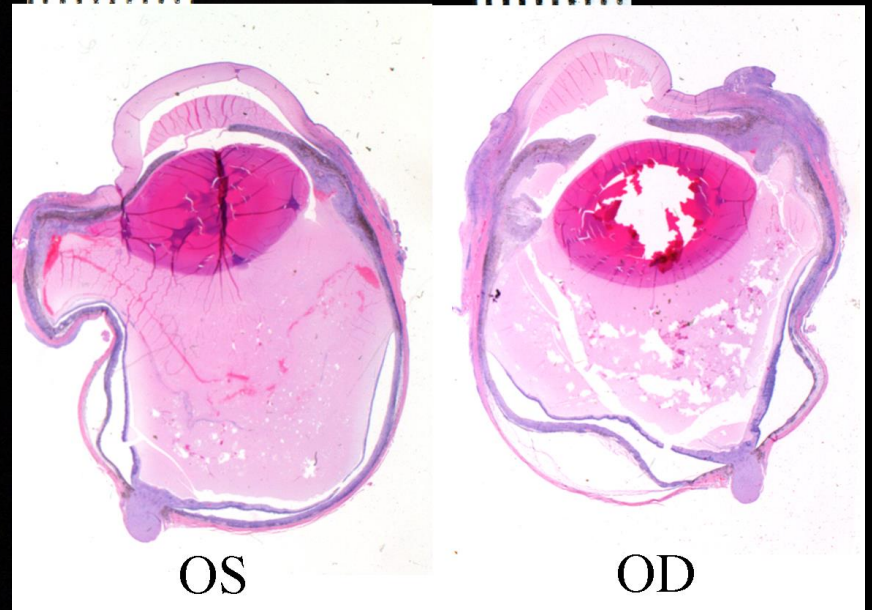
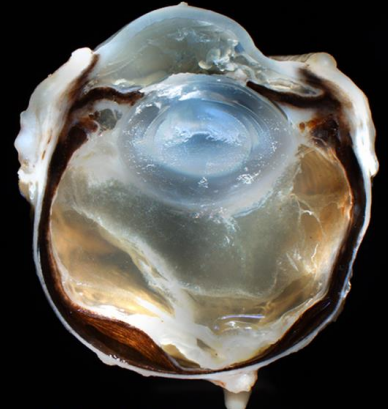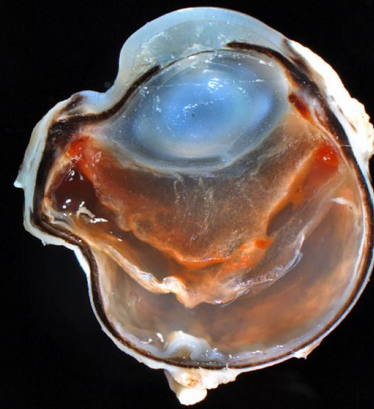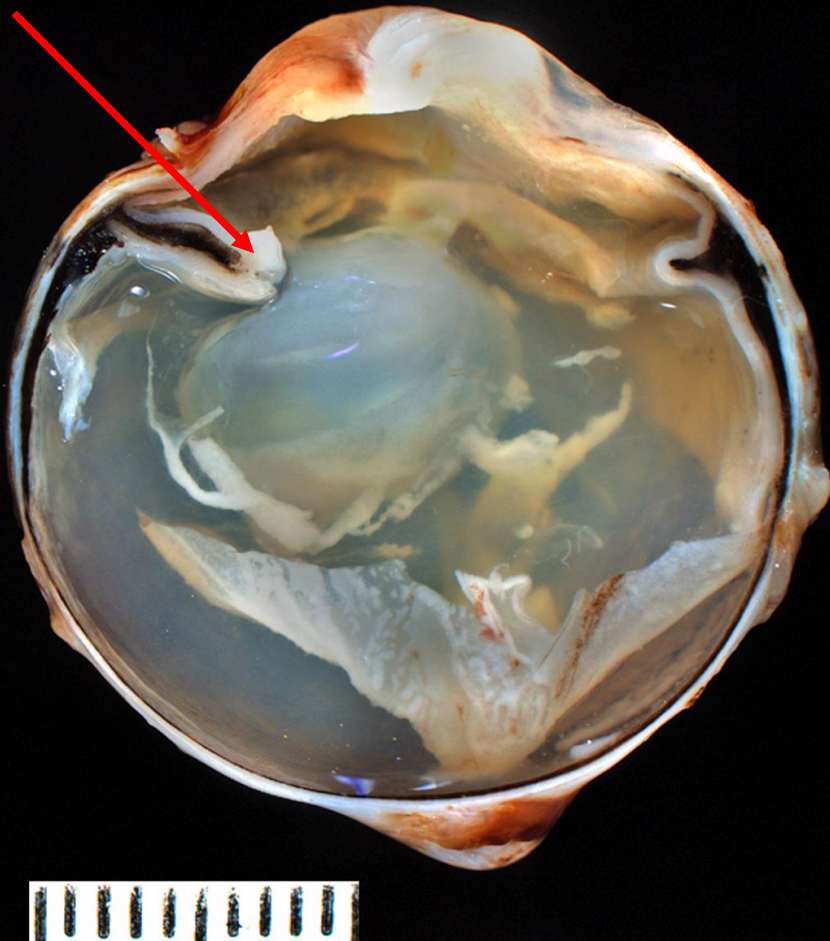


**Second Eye After
Lens Removal**

Matt Fife

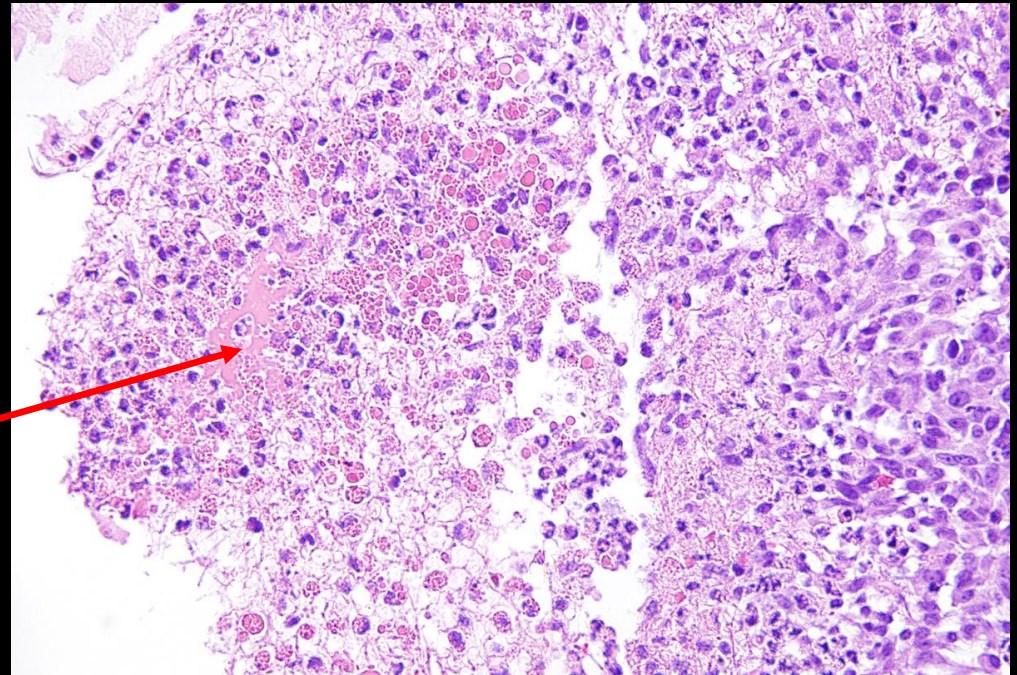
Asymmetric Uveitis

Histiocytic carpeting



Asymmetric Uveitis

Lens protein
In phagocytosis



Lens

Lens protein droplets

20 µm

Carpeting of the choroid

