

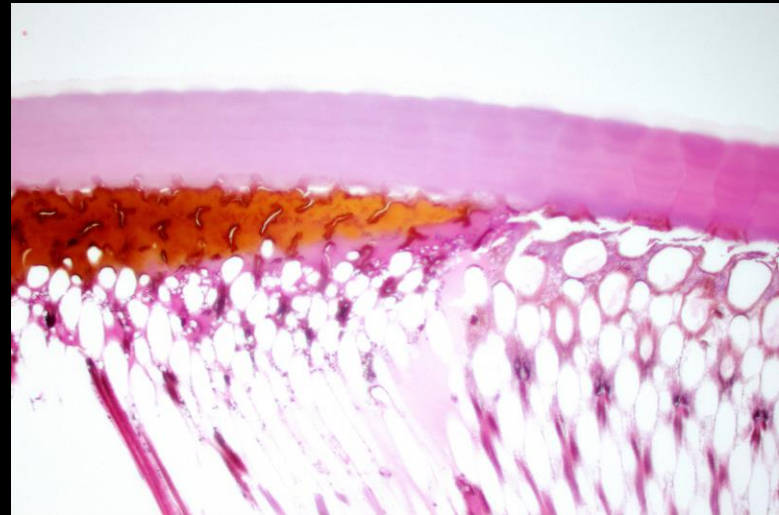
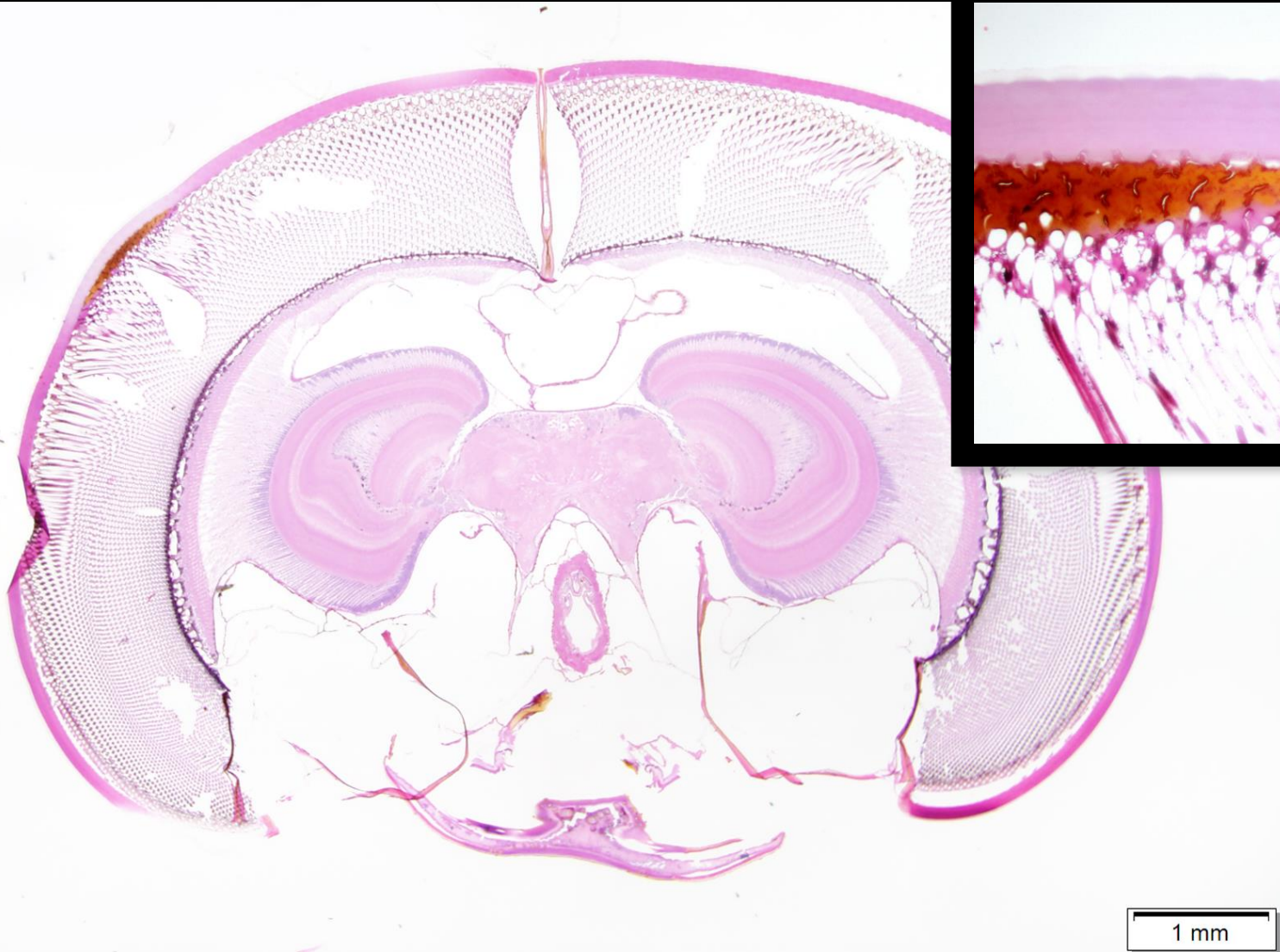A Potpourri of Ocular Pathology in Exotic Species

Richard R Dubielzig

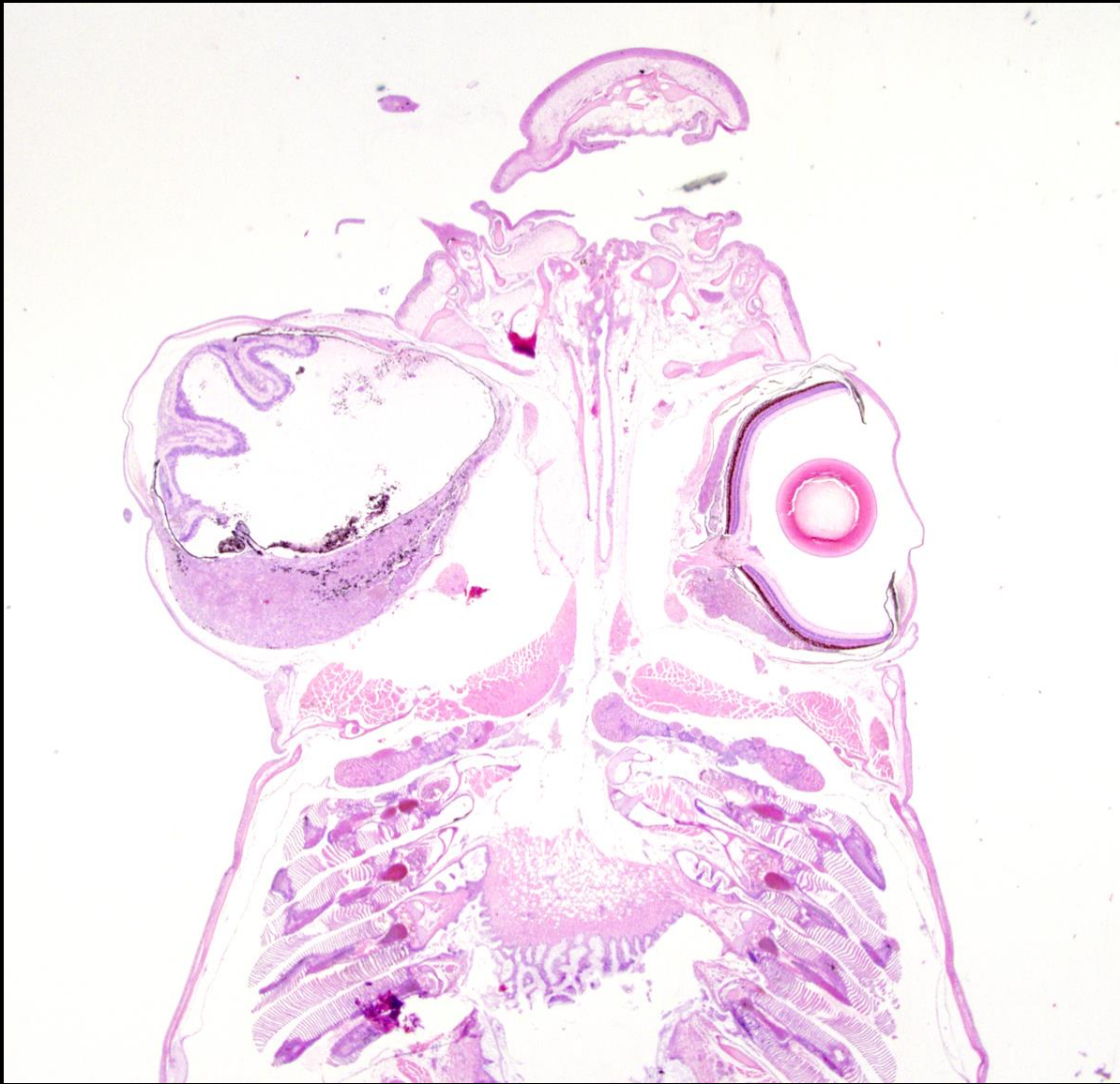Dragonfly



Dragonfly

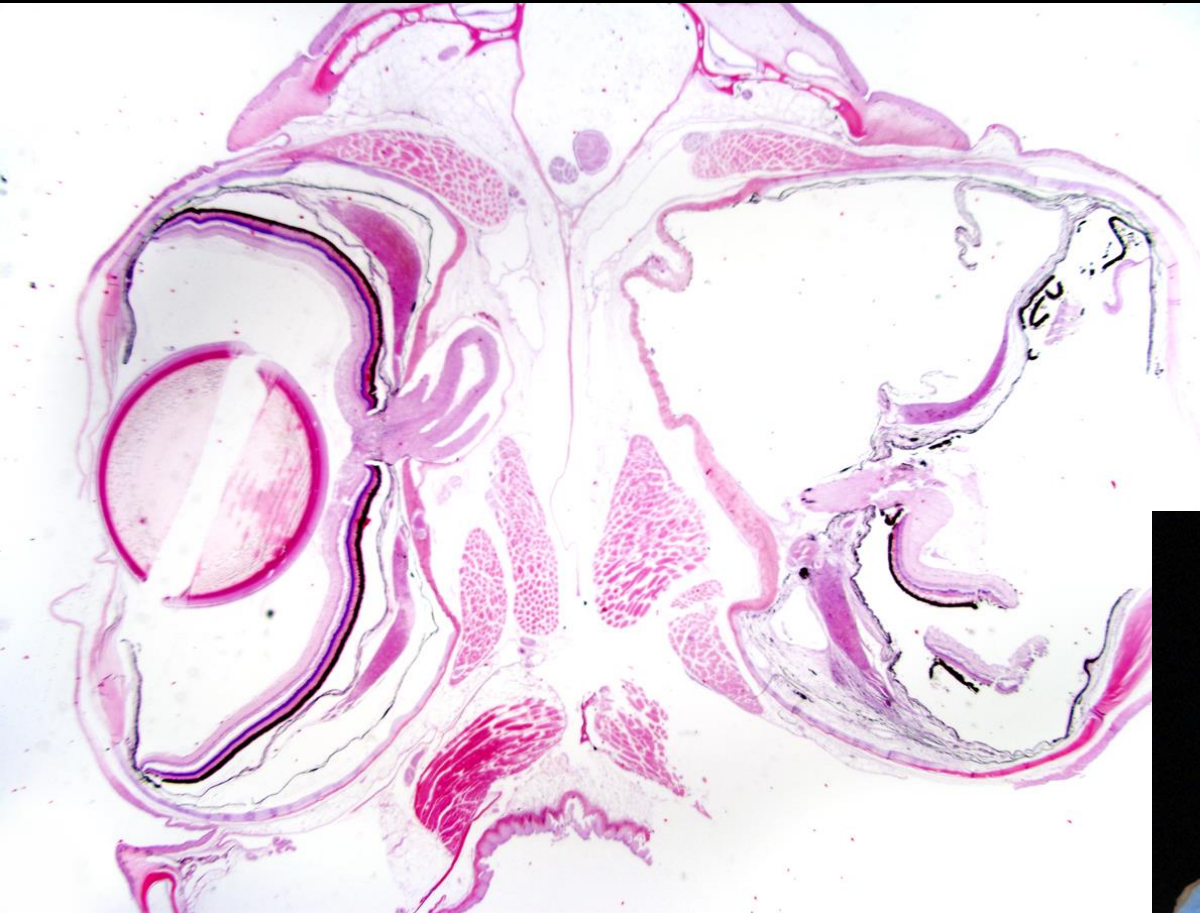


Fish

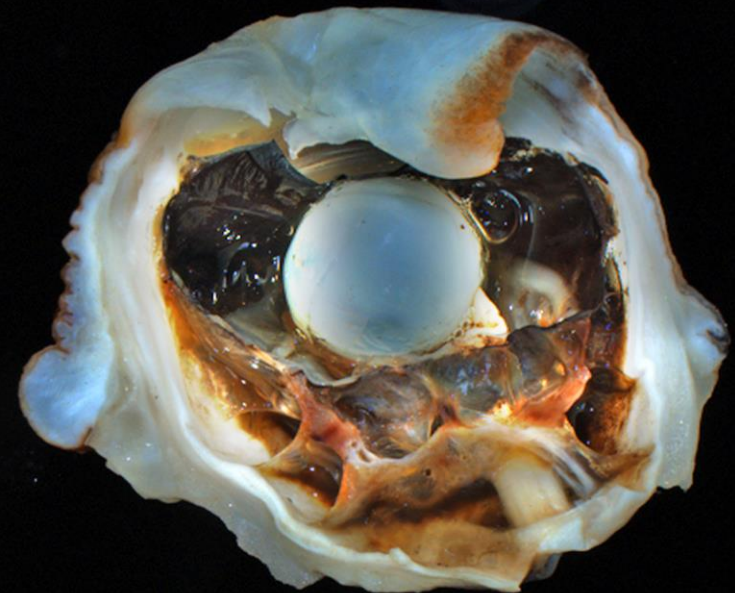

Zebra Fish
normal and
chronic trauma

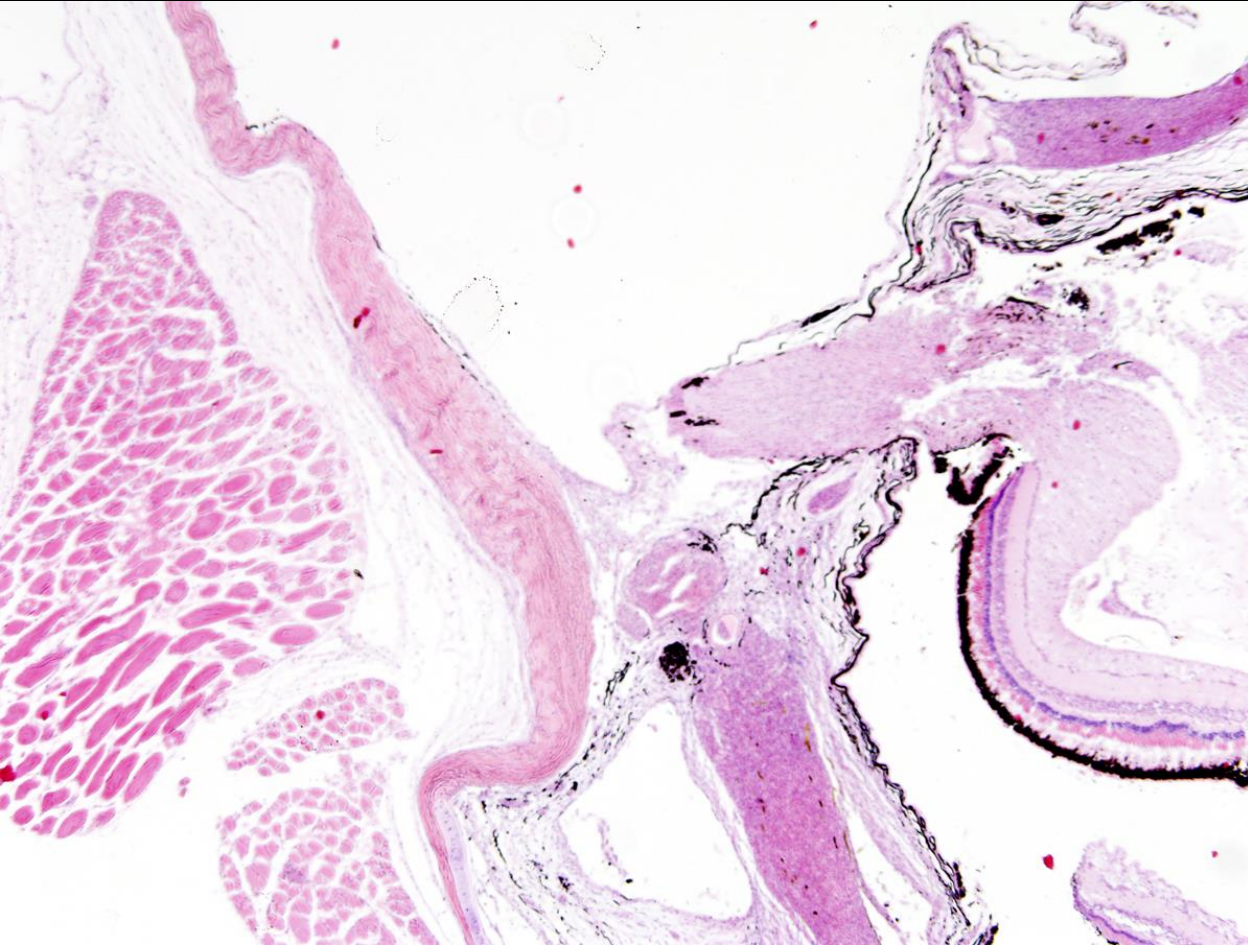
Fish



Perch
Gas bubble
“Popeye”

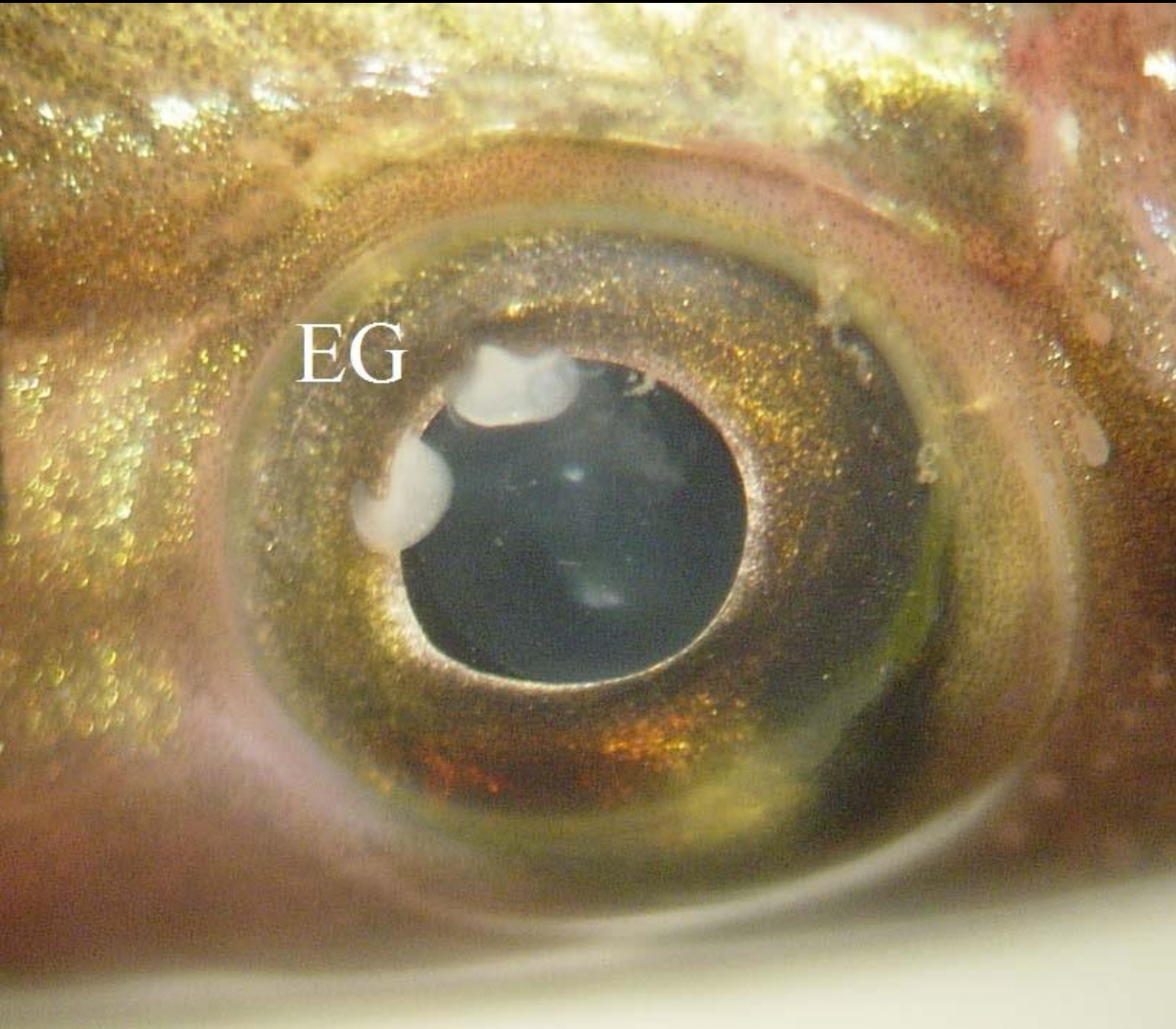


Fish



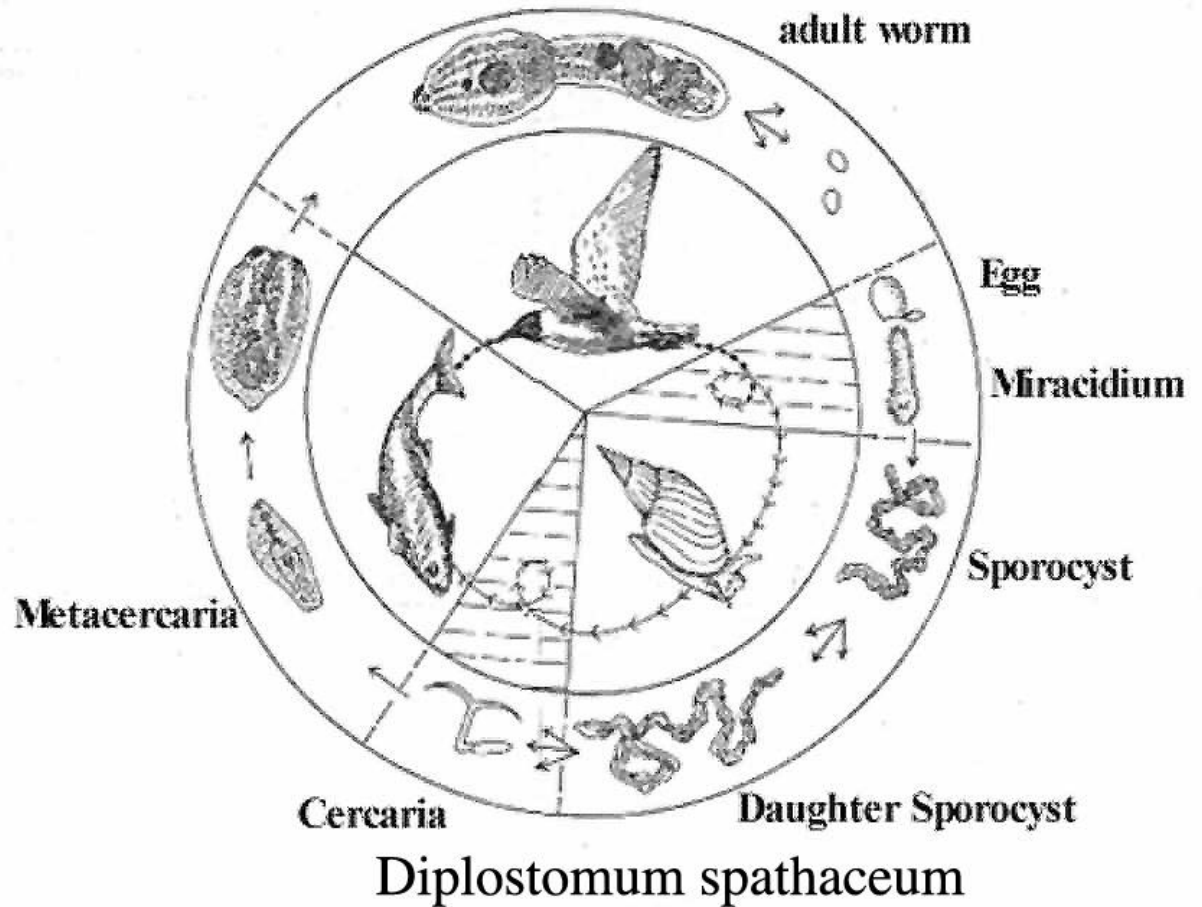
Perch
Gas bubble
“Popeye”

Fish

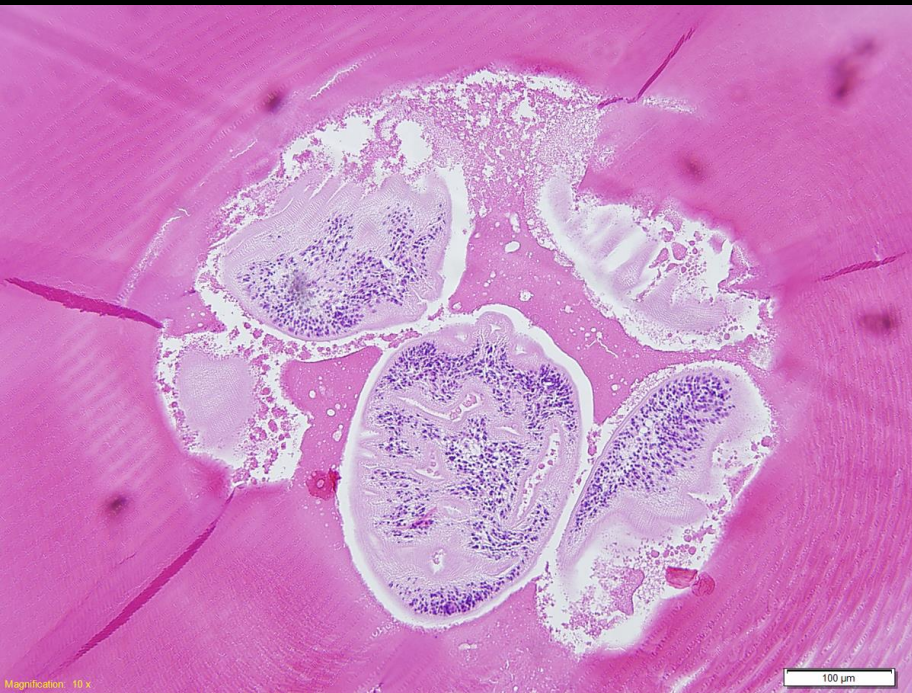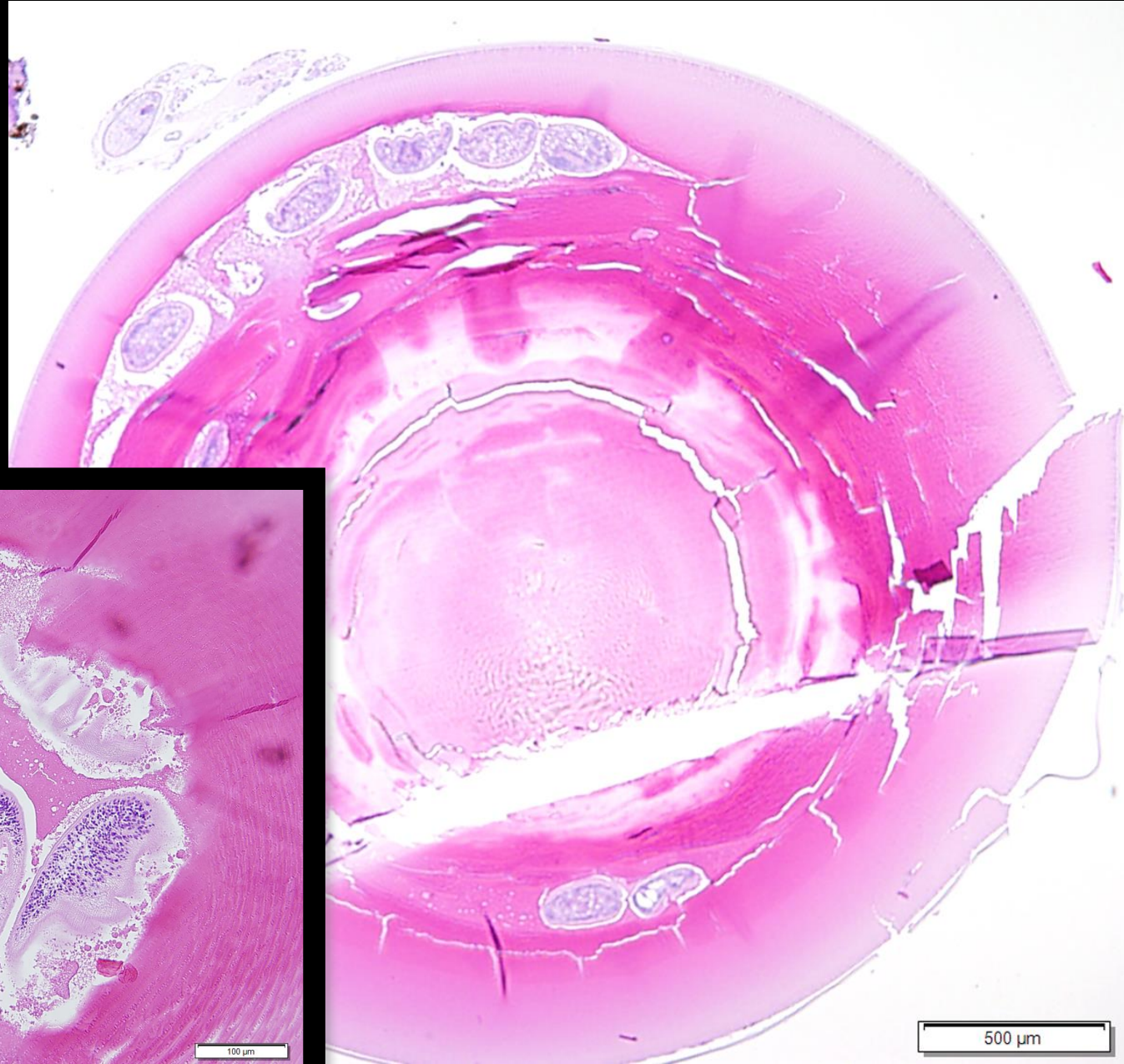


Diplostomu spp.
Trematode parasites
Migrating to
the lens

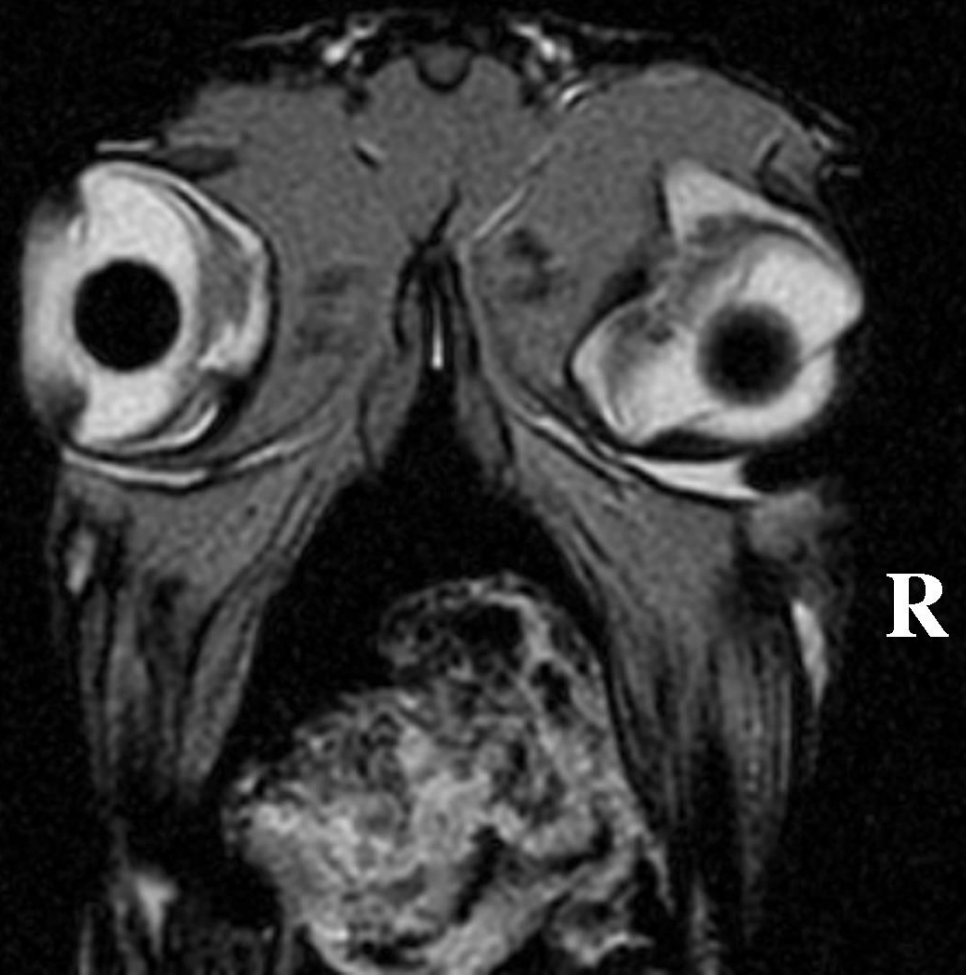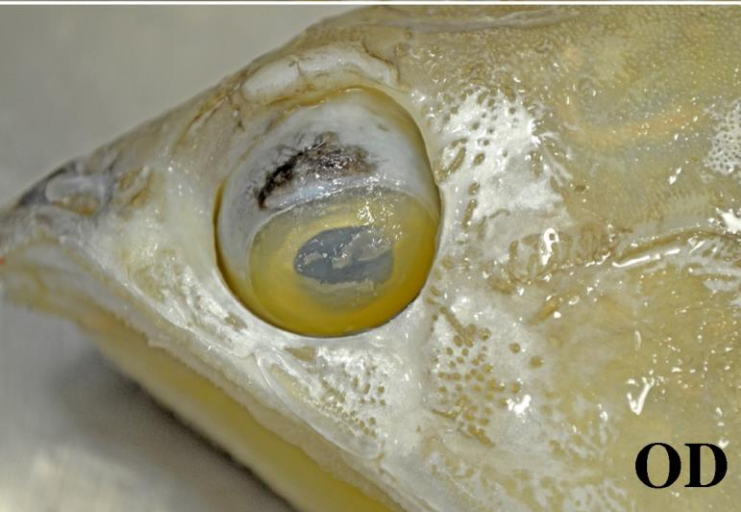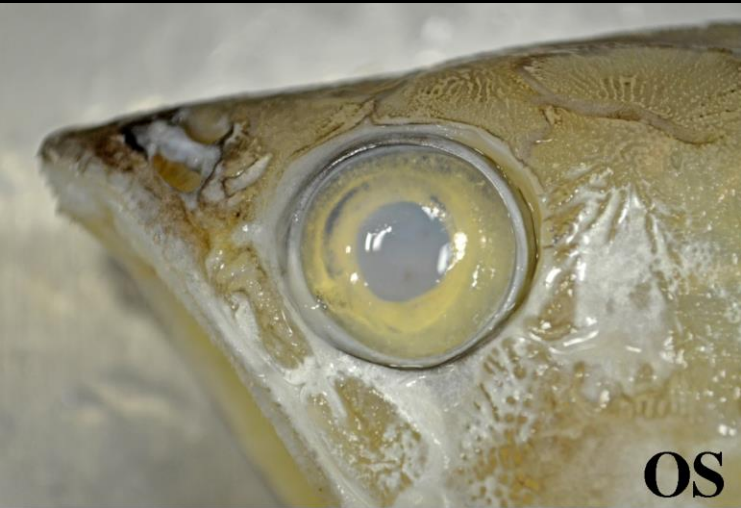Fish



Fish Diplostomum spp.

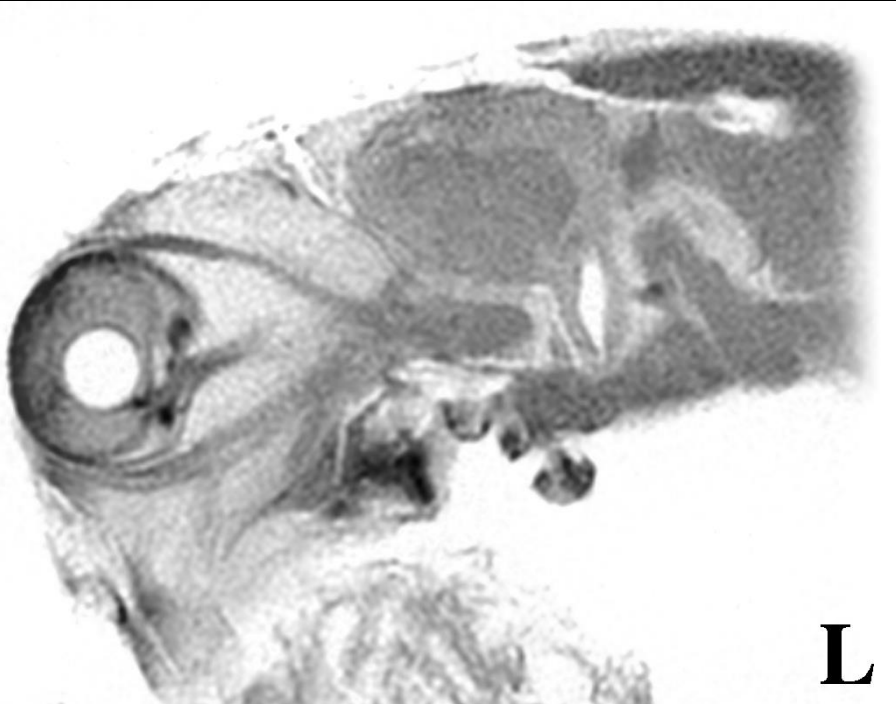


Arowana sp “Drop Eye”

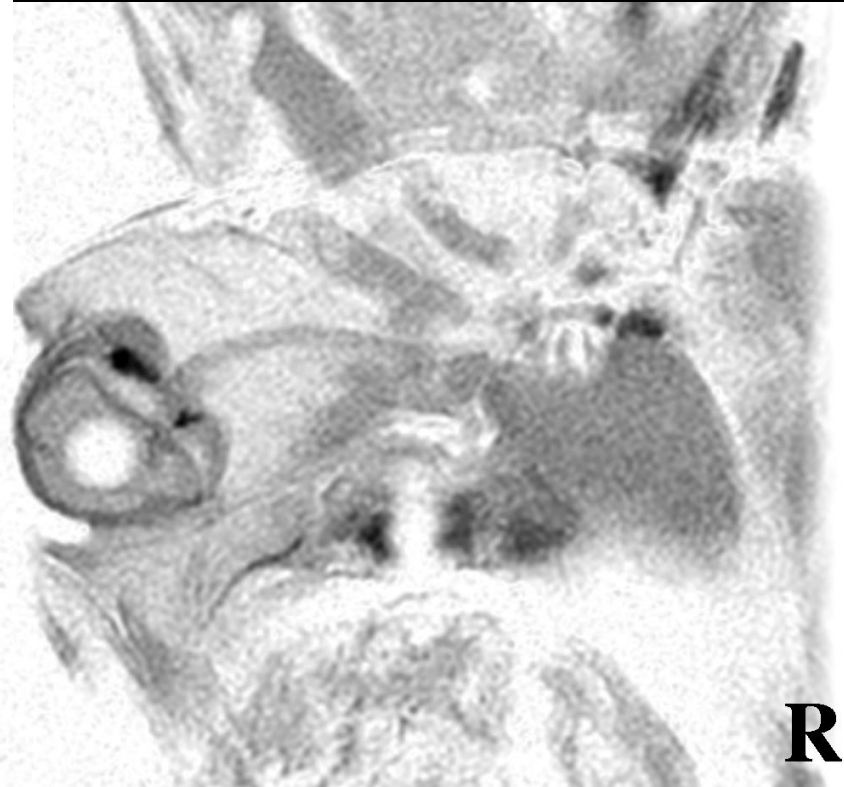


Arowana sp

“Drop Eye”



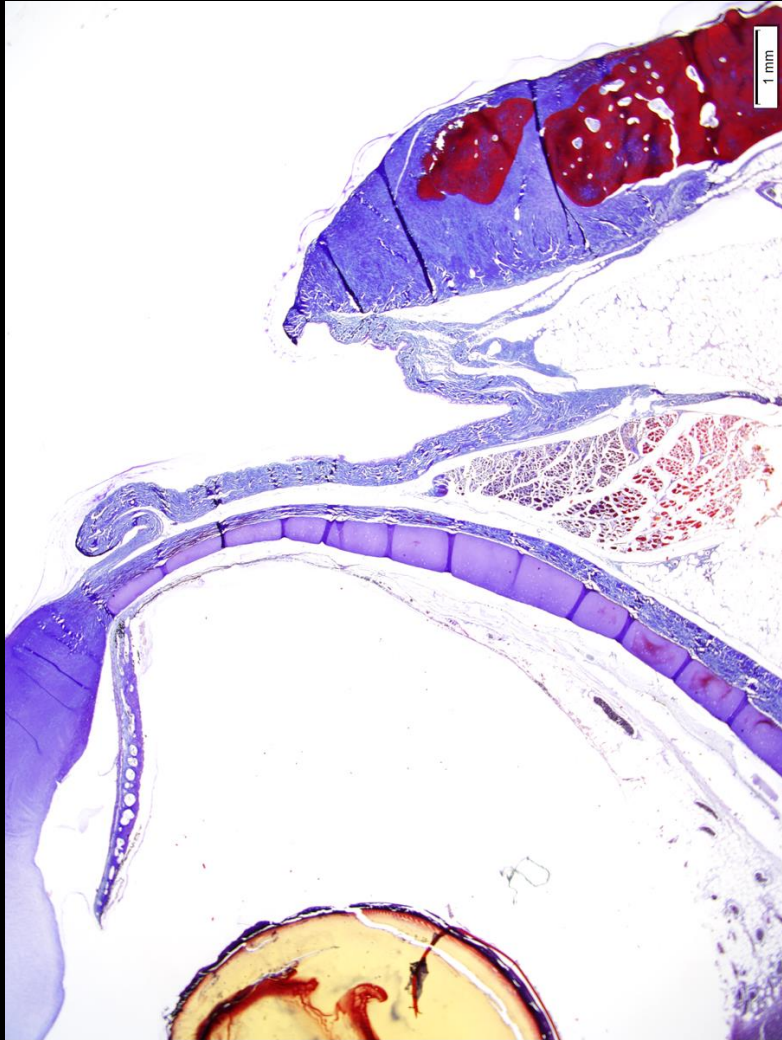
L



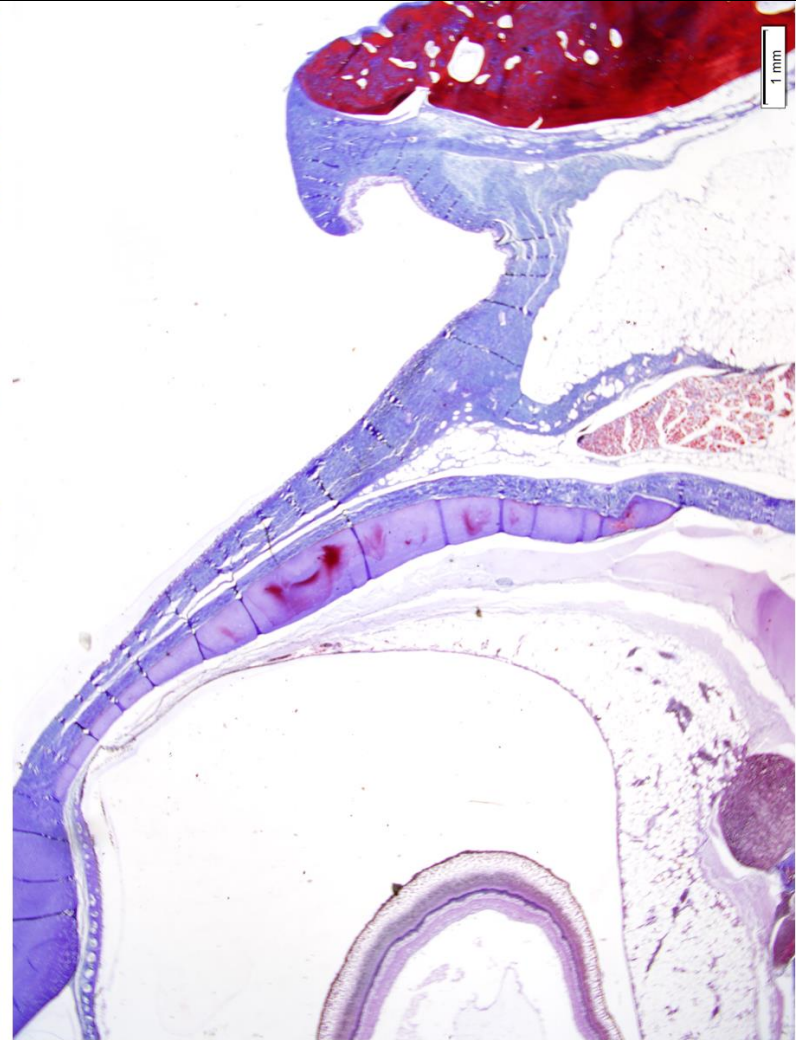
R

Arowana sp

“Drop Eye”



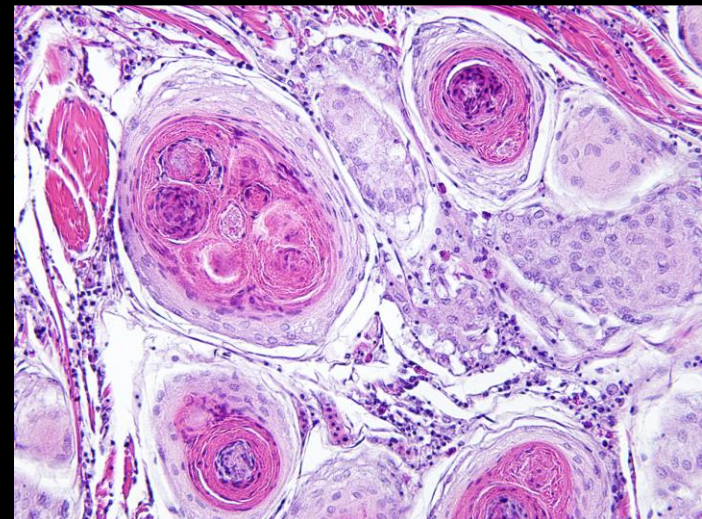
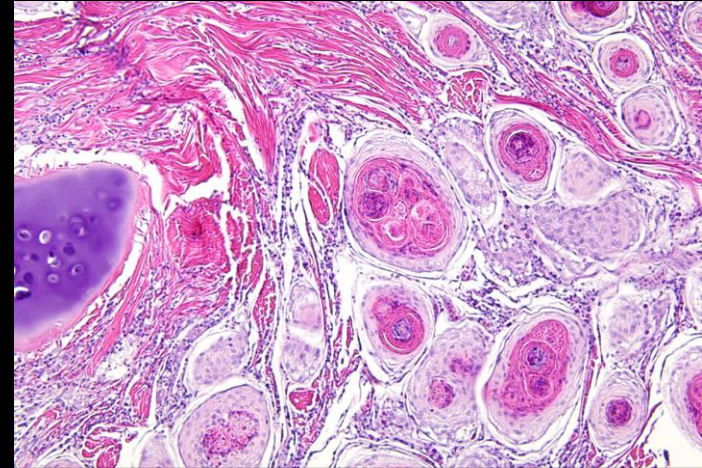
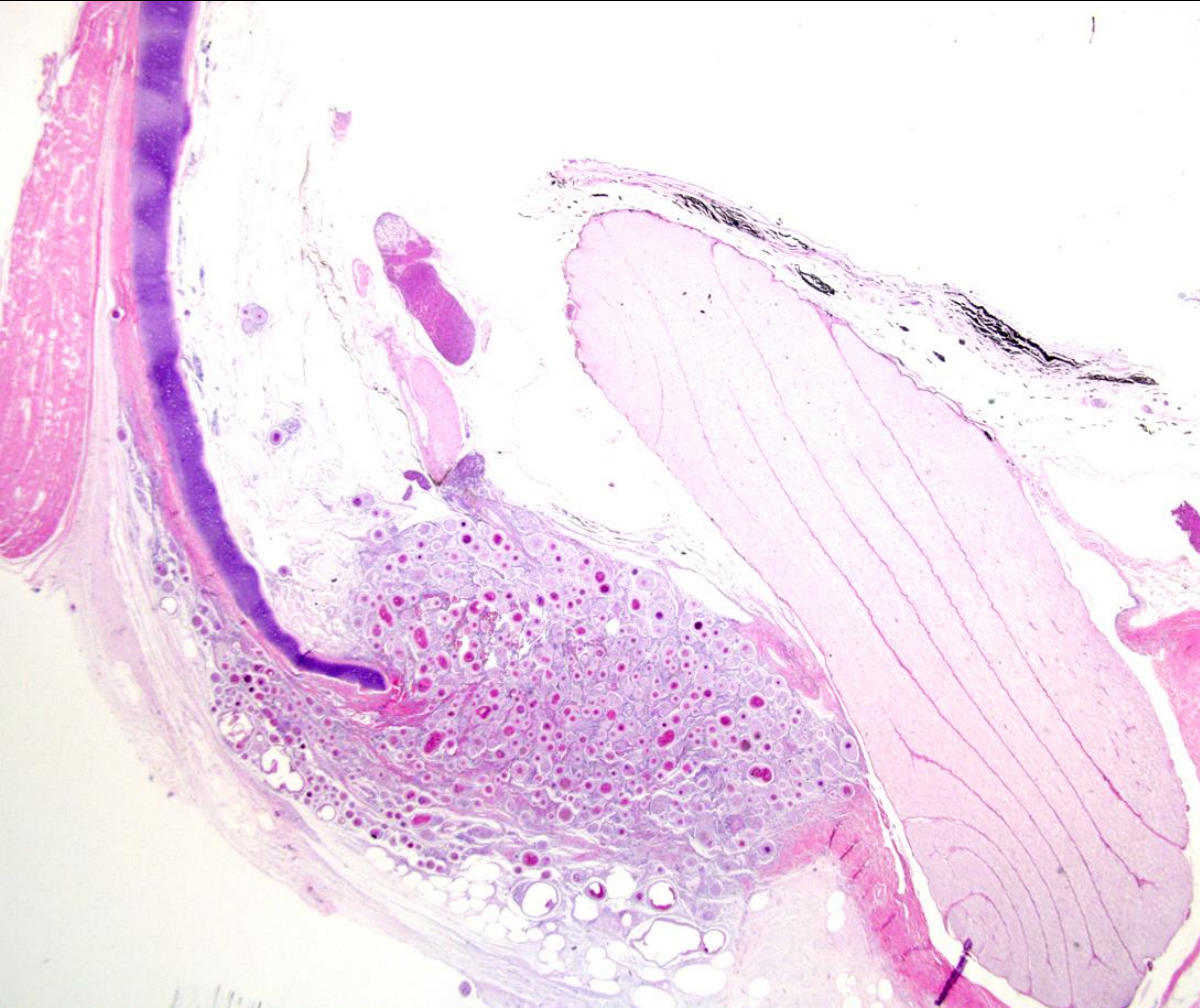
Normal



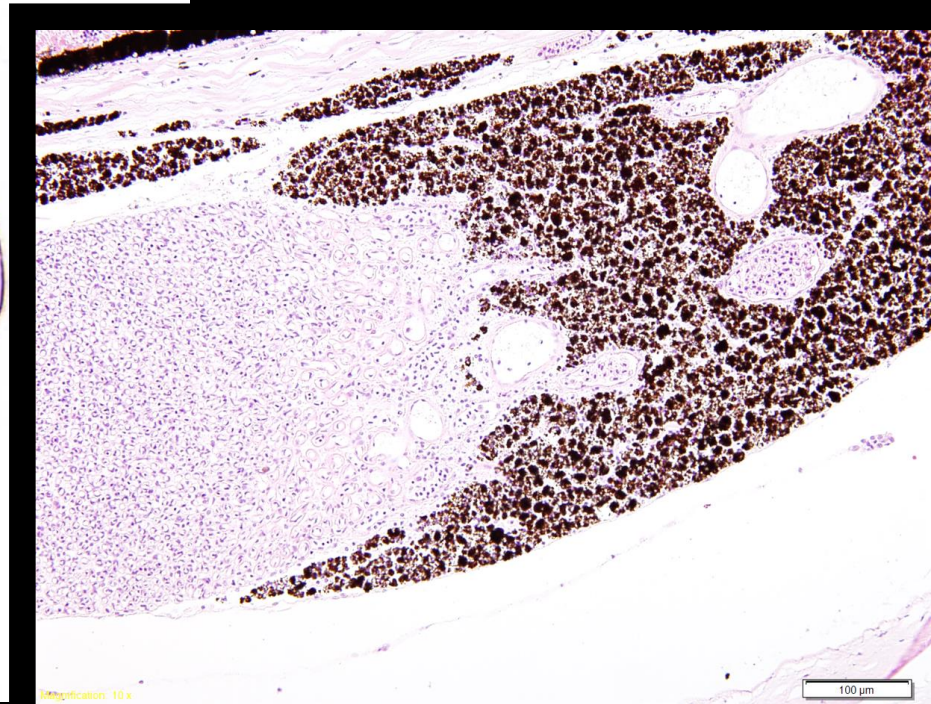
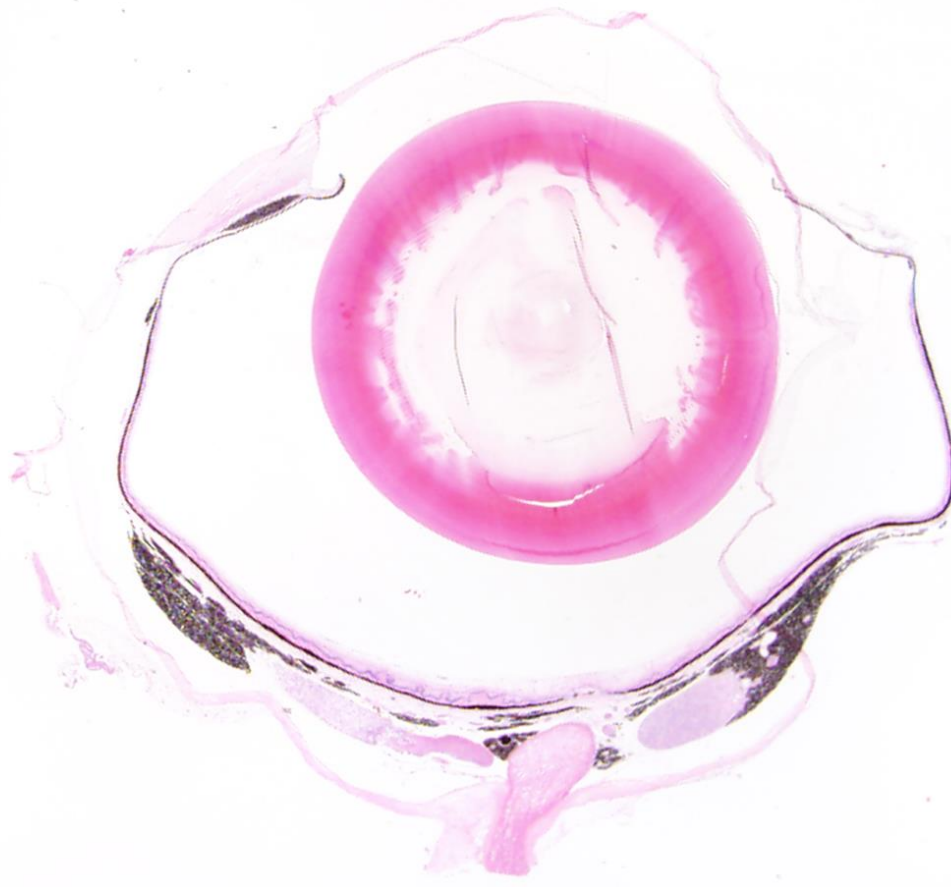
Up Side

Abnormal

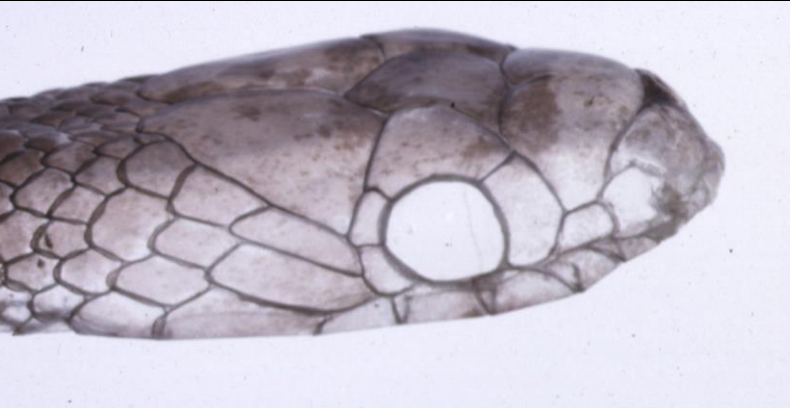
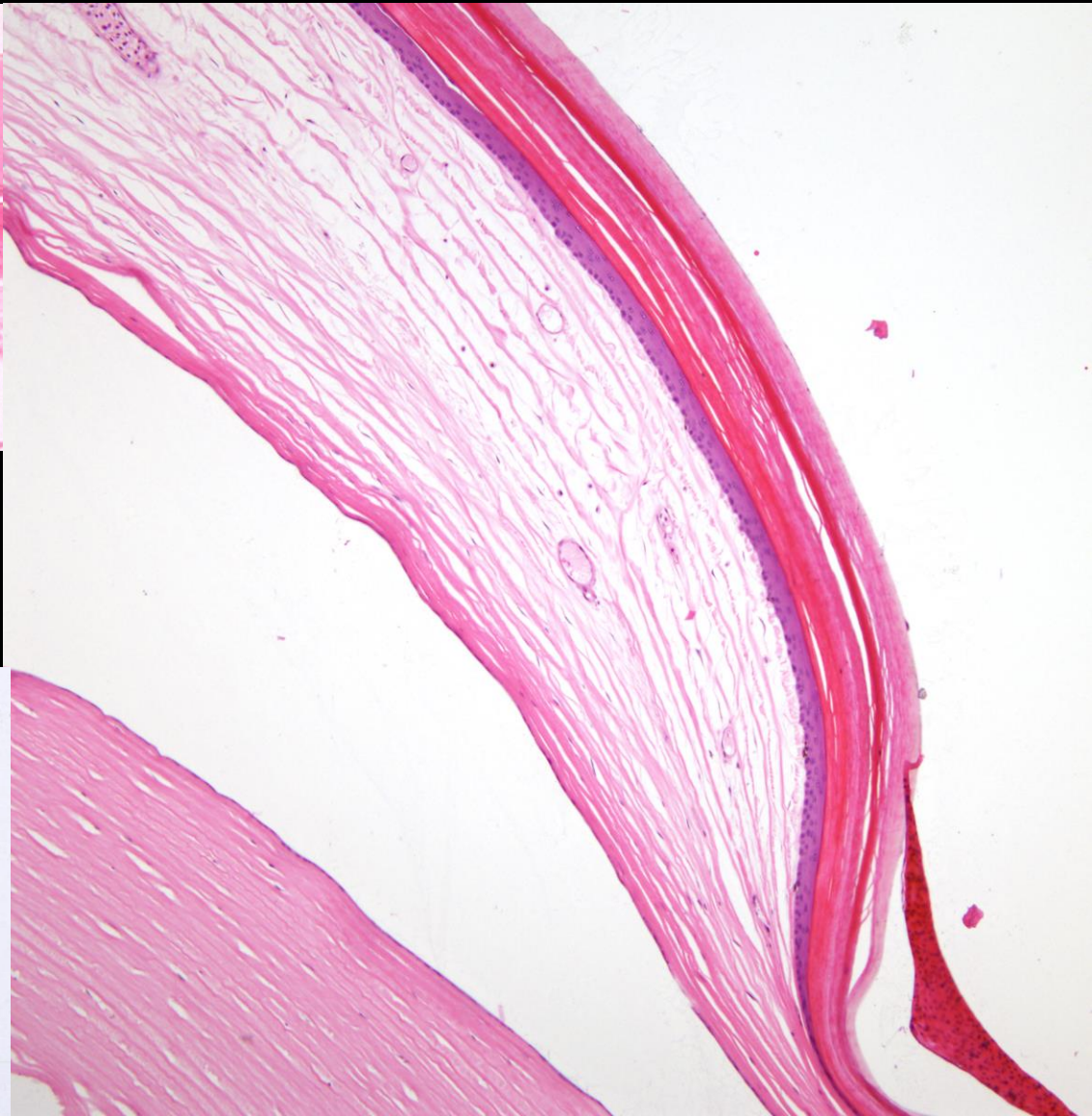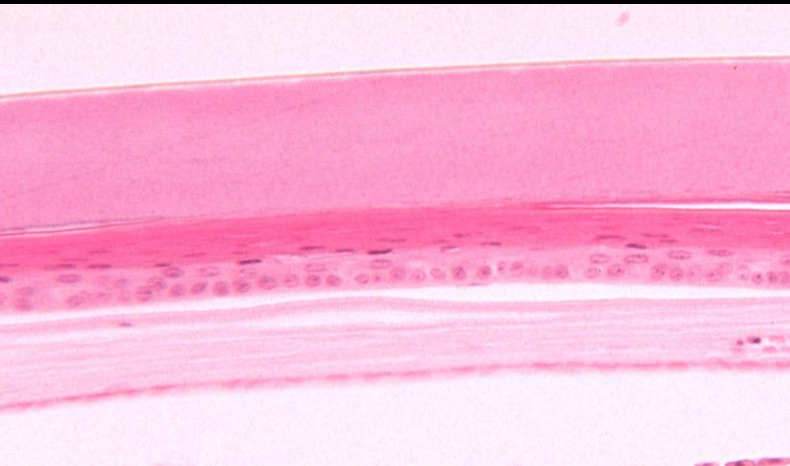
Fish Eye Septic Granuloma



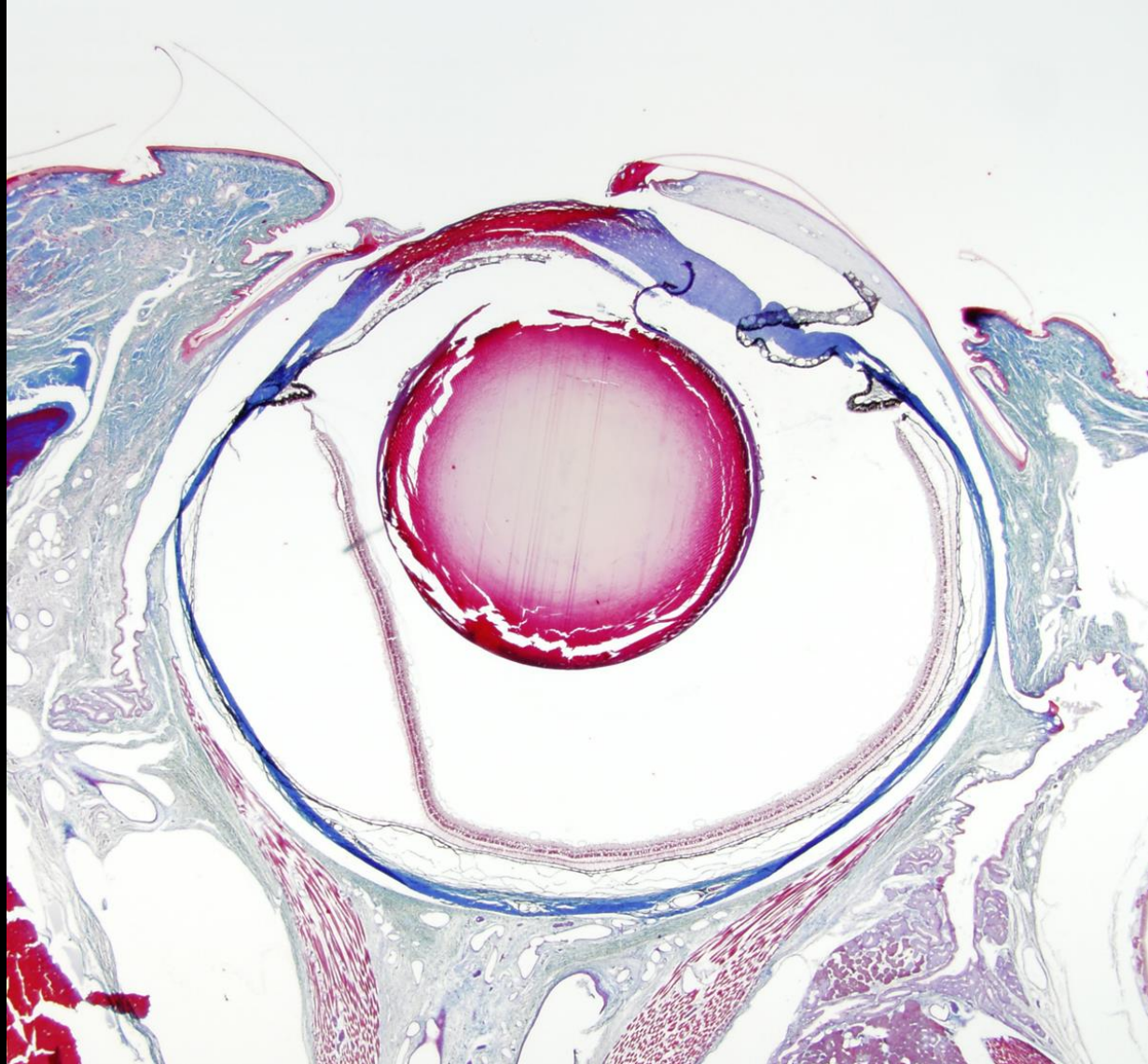
Non-specific inflammation Melanomacrophage accumulaton

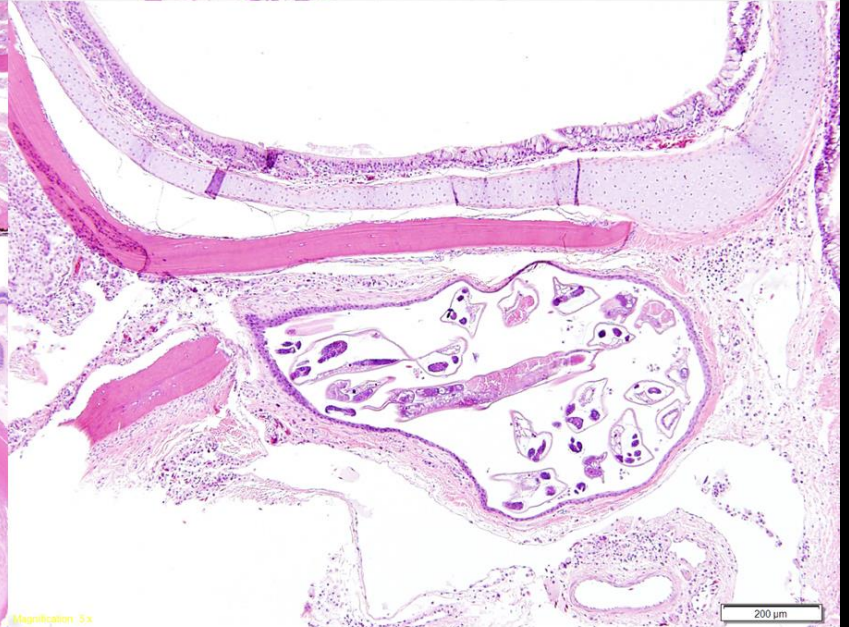
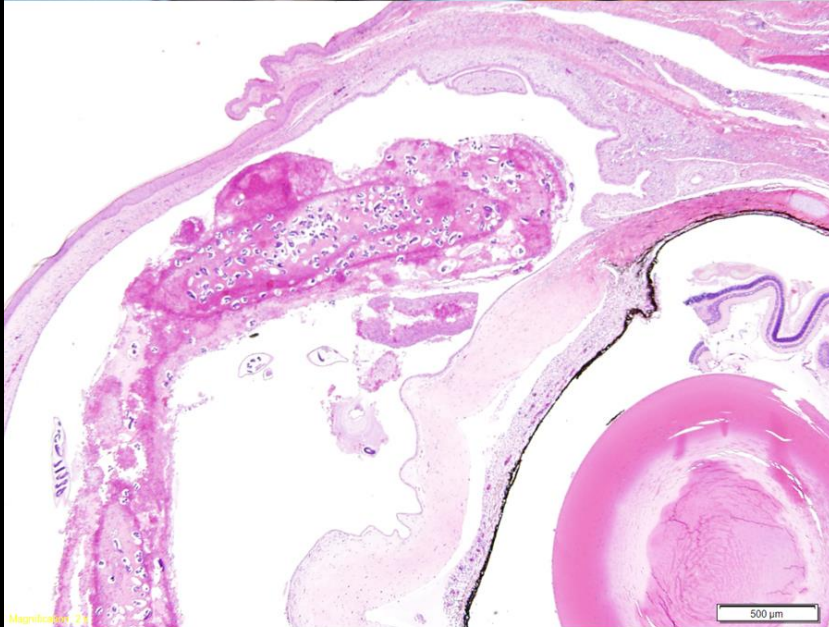
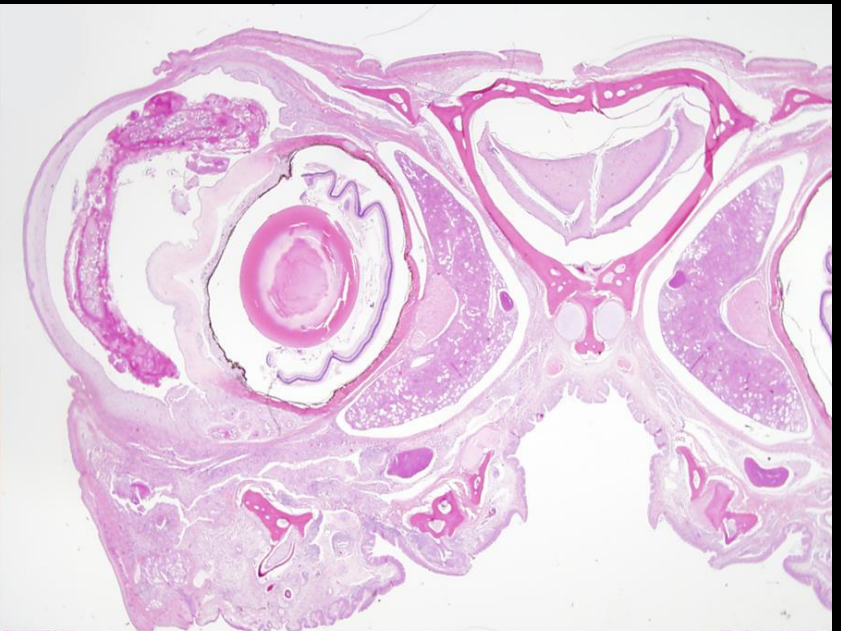
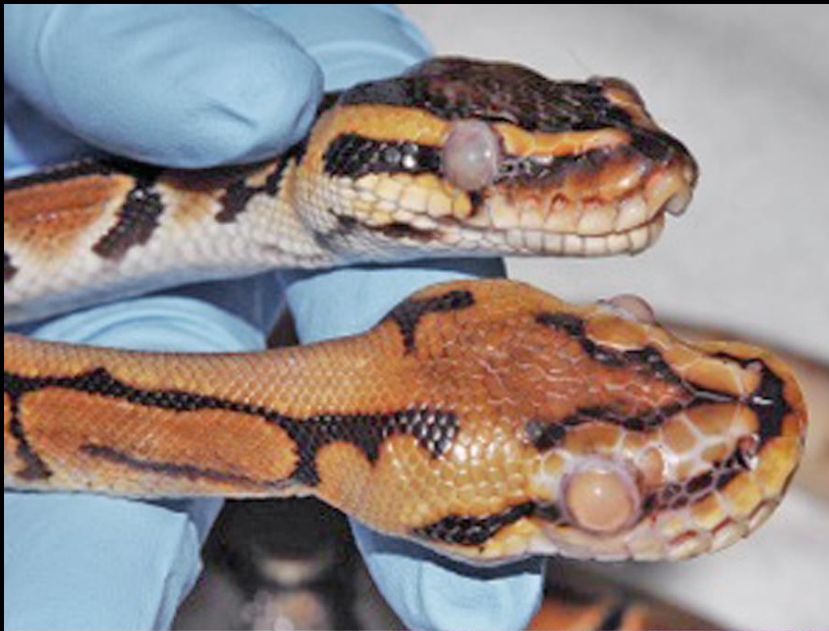
Snake Ecdysis



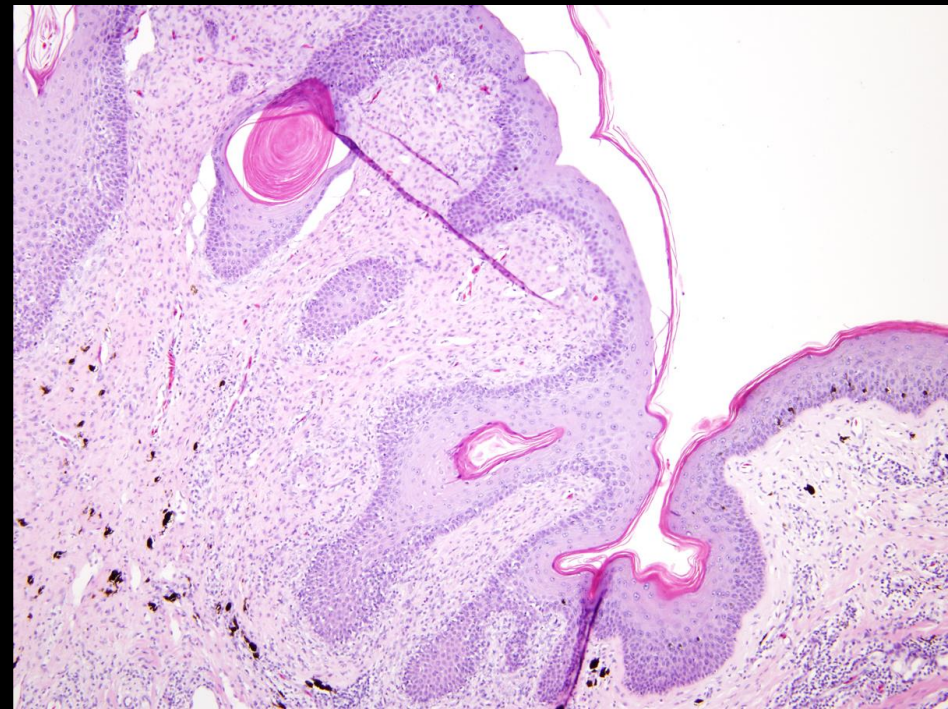
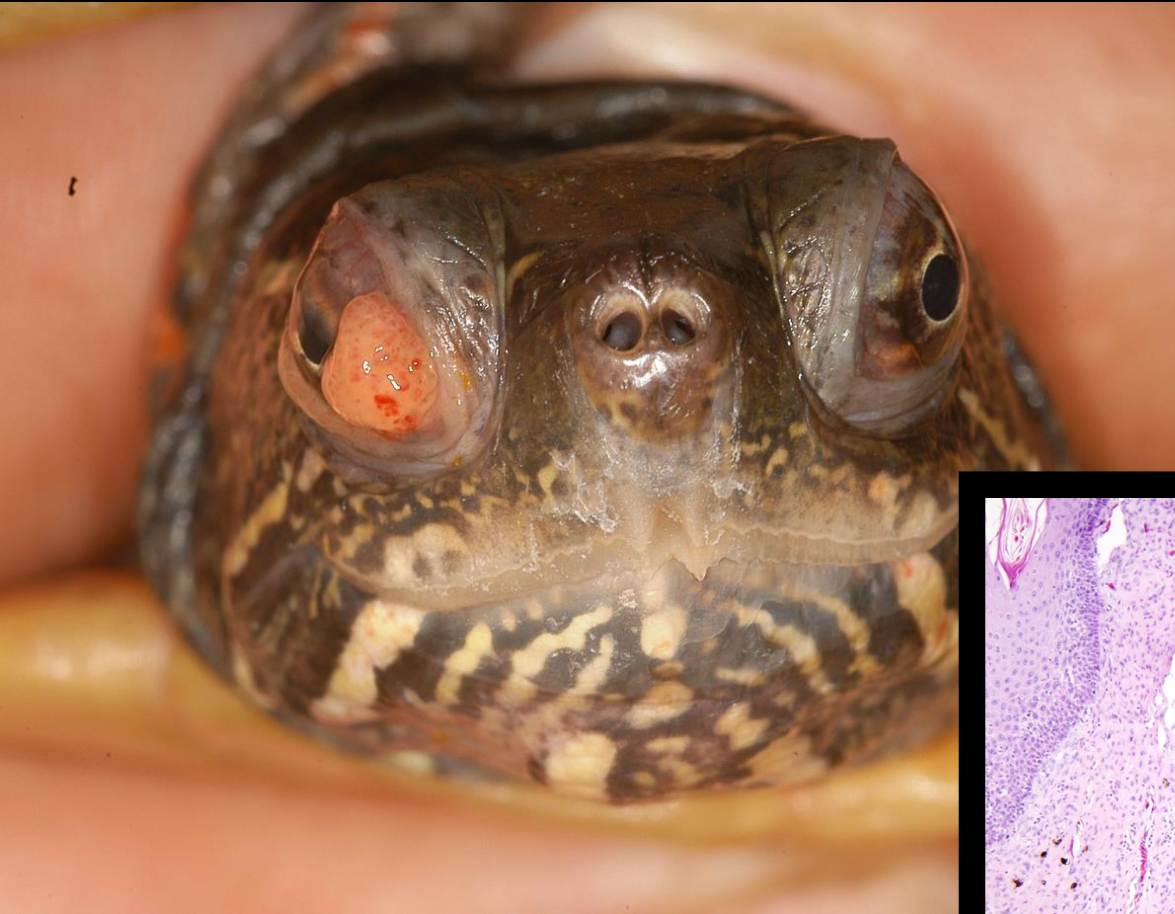Snake Ecdysis



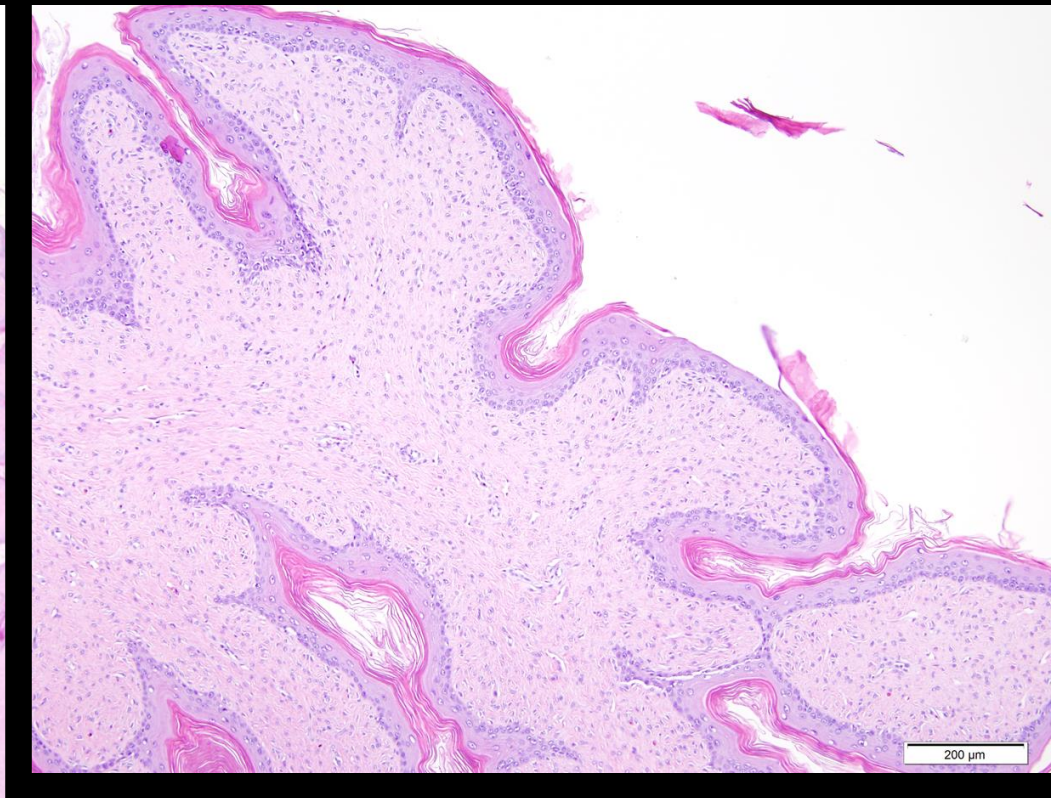
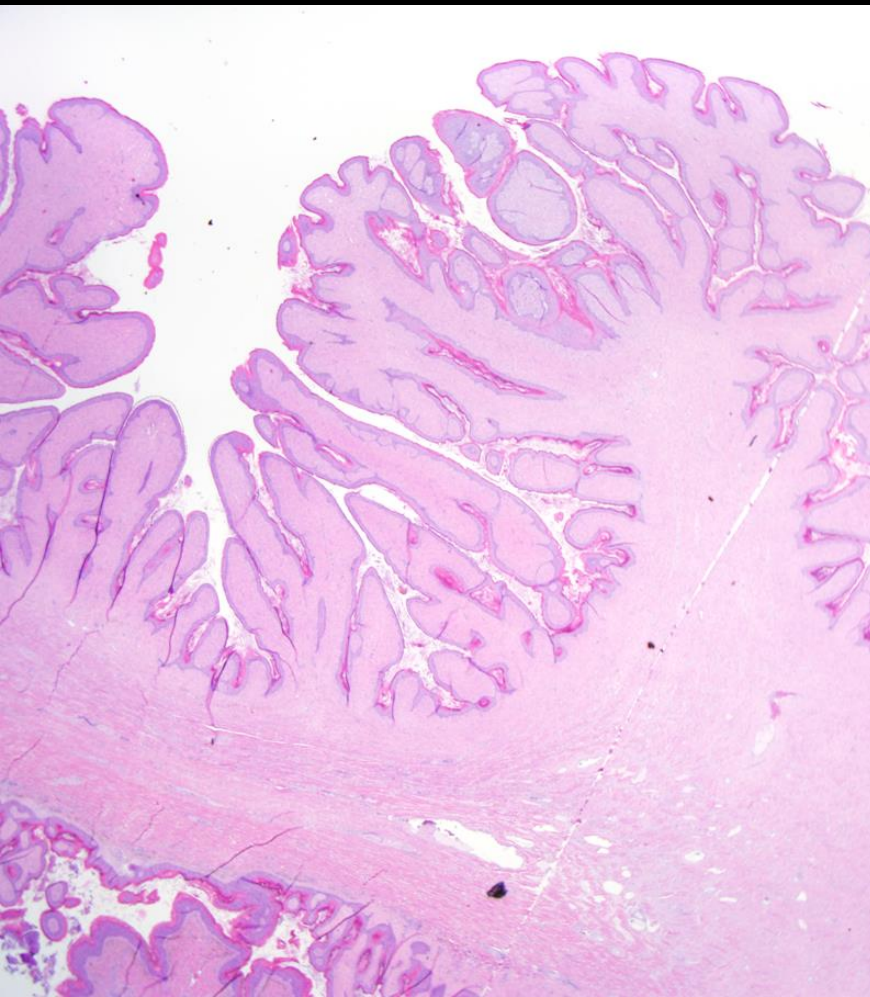


Rhabdias dubielzigi

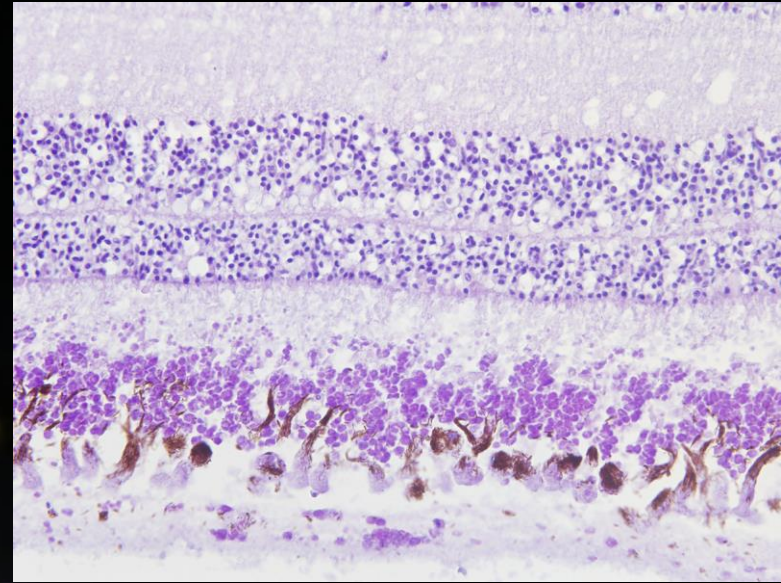
Turtle Fibropapilloma



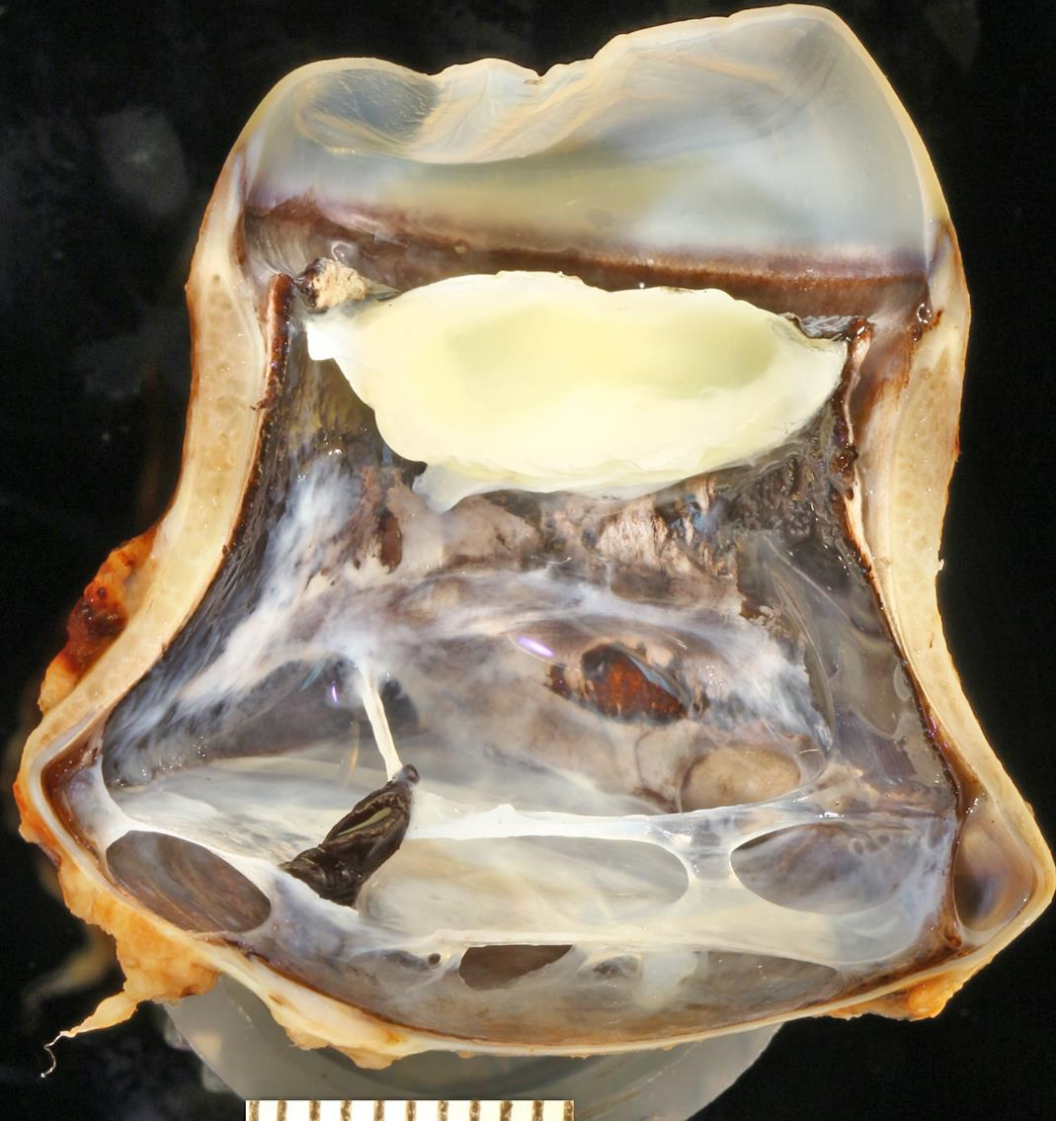
Green Sea Turtle



Bird Eyes and Trauma

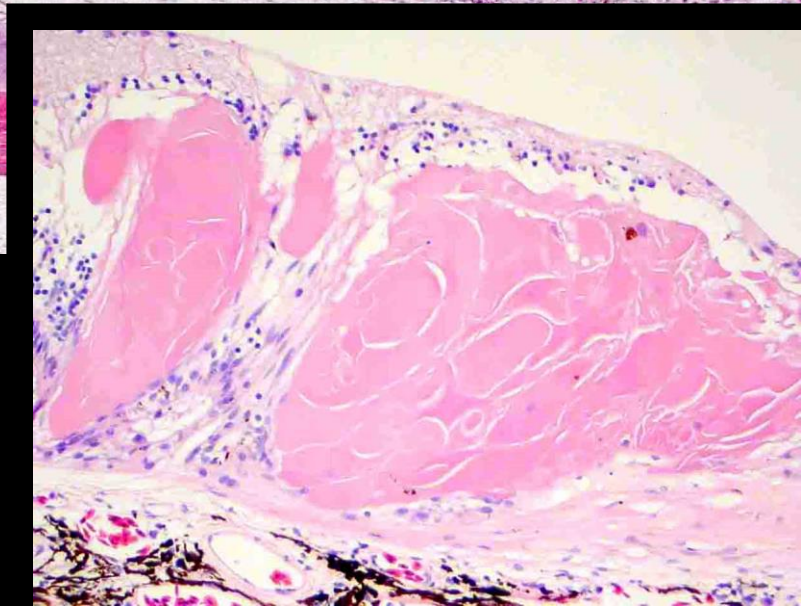
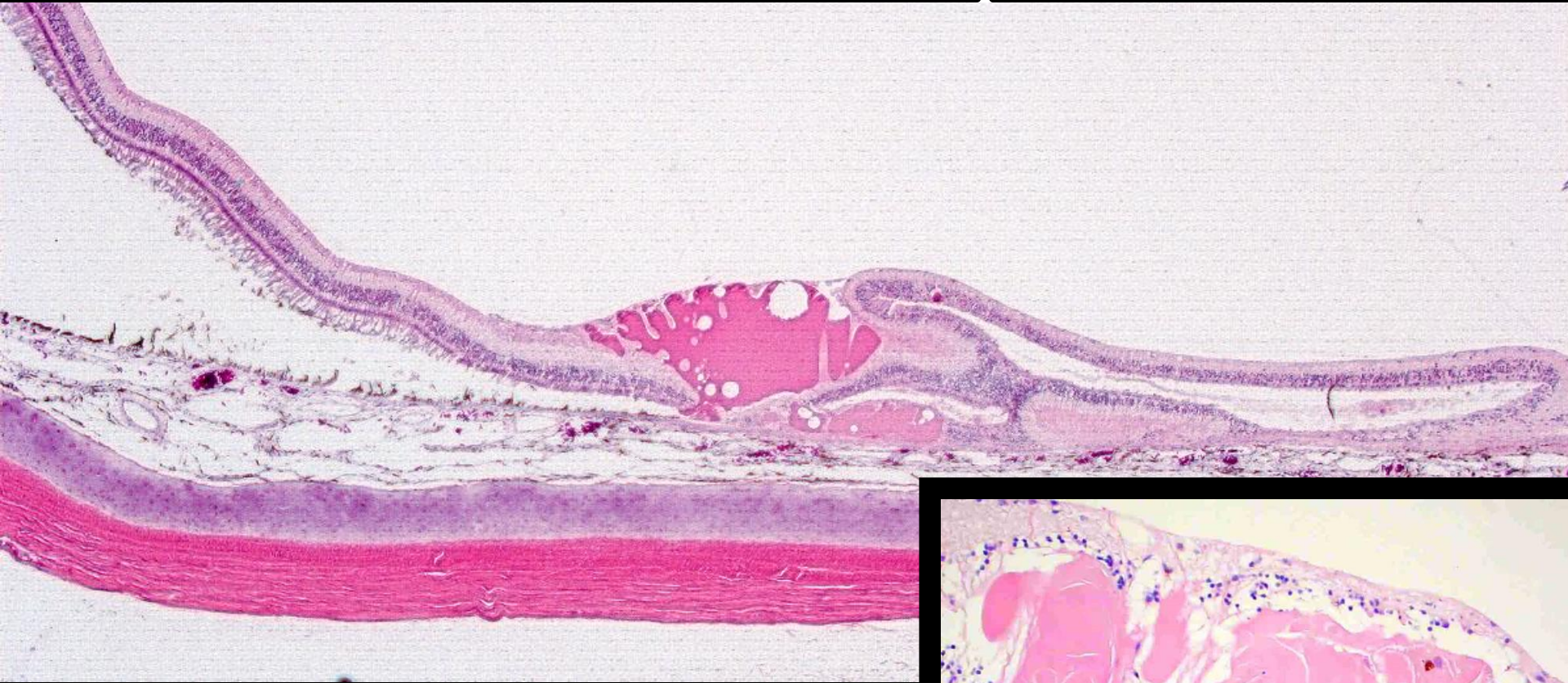


Bird Eyes and Trauma

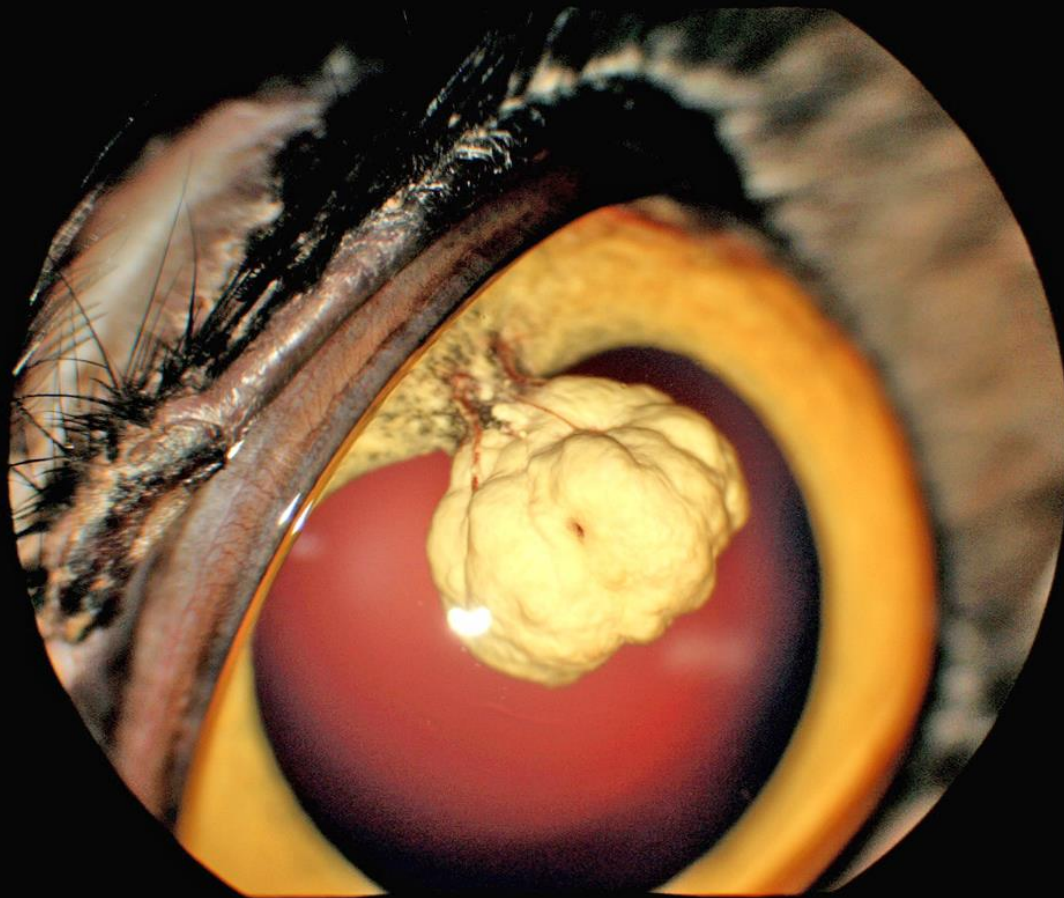


Bird Eyes and Trauma

Lenticular metaplasia

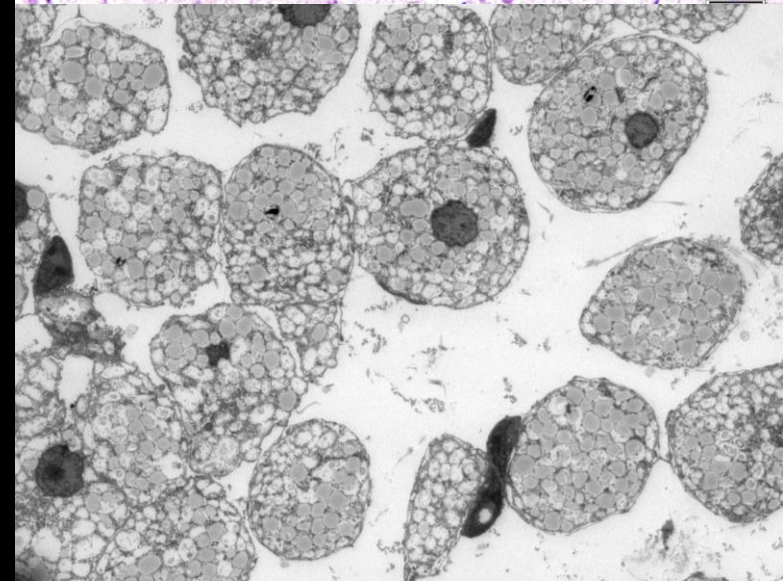
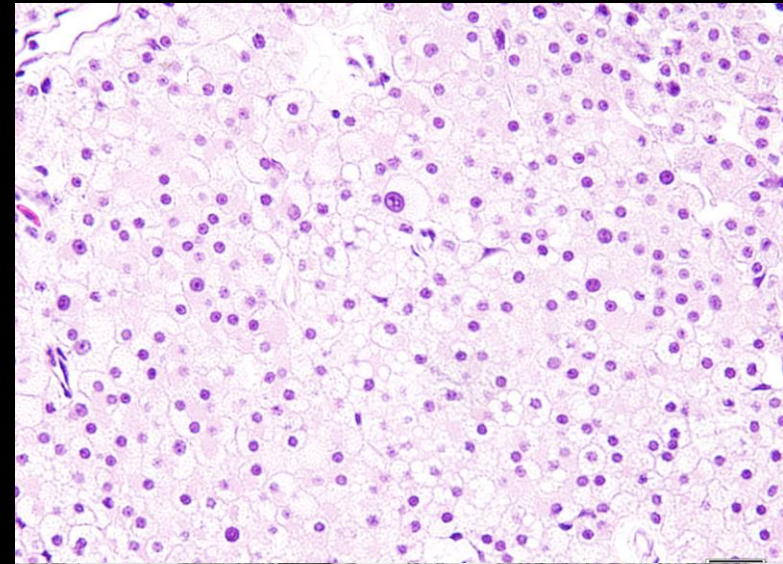


Great Horned Owl Iridal Pigment Cell Tumor



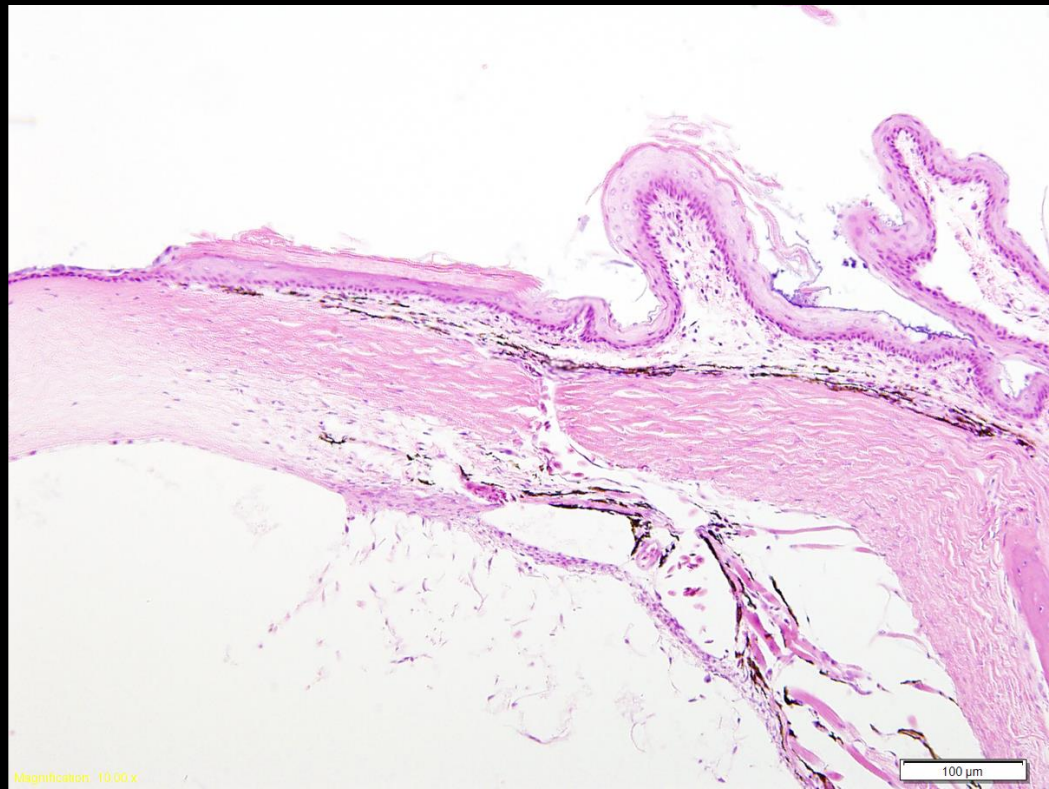
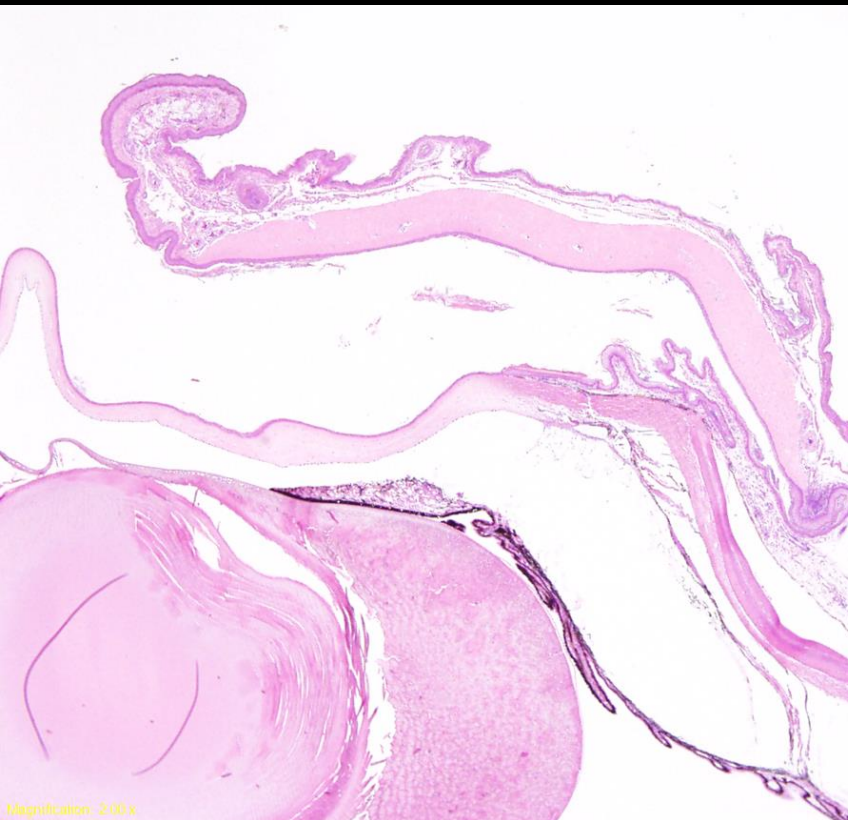Great Horned Owl

Iridal Pigment Cell Tumor



Barn Swallow

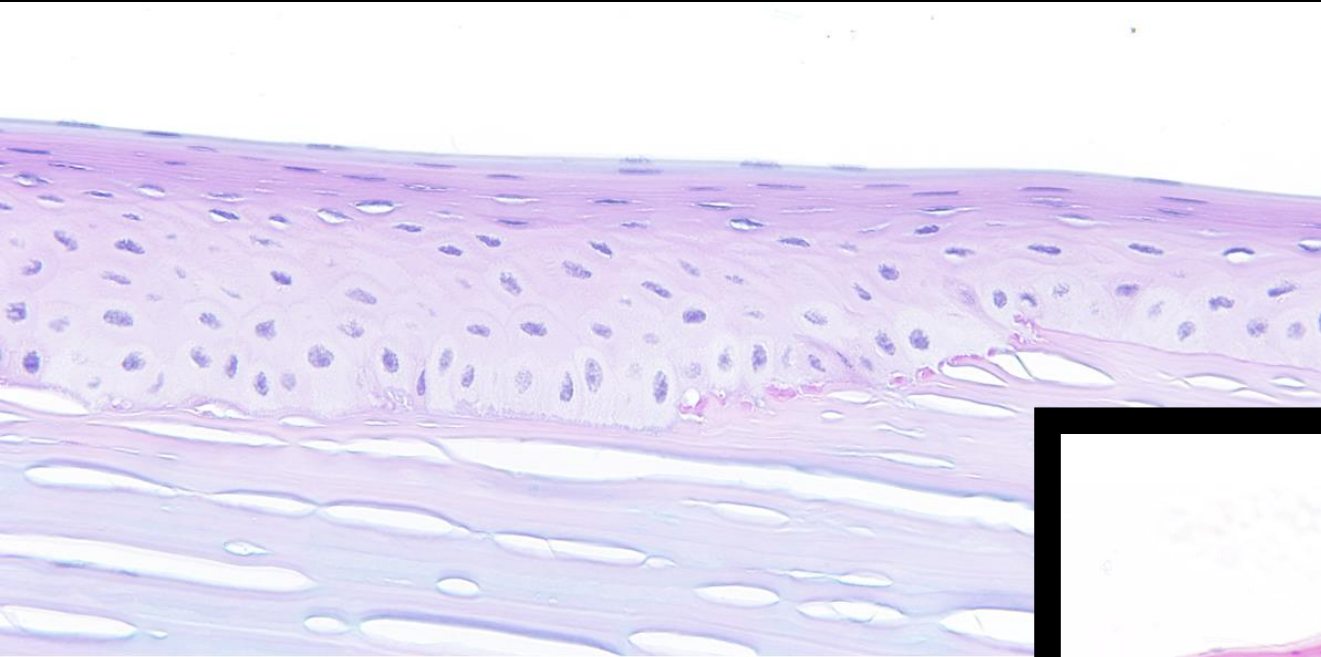
Vitamin A Deficiency



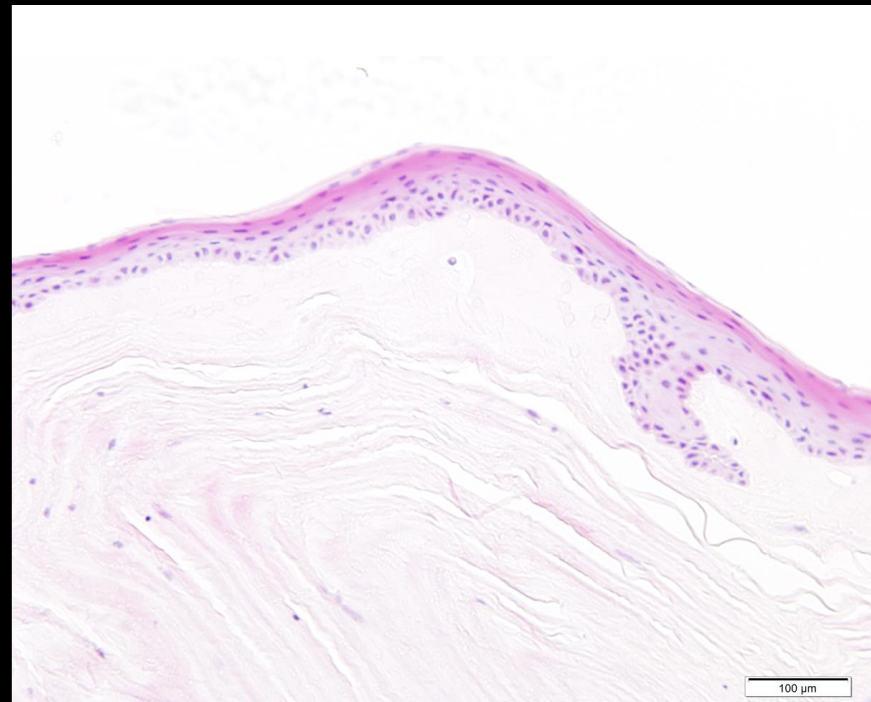
Otariid Keratopathy



Otariid Keratopathy


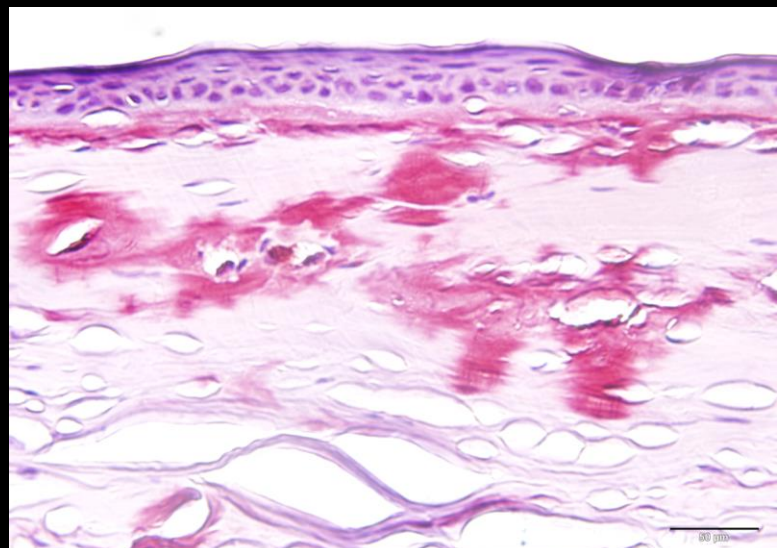
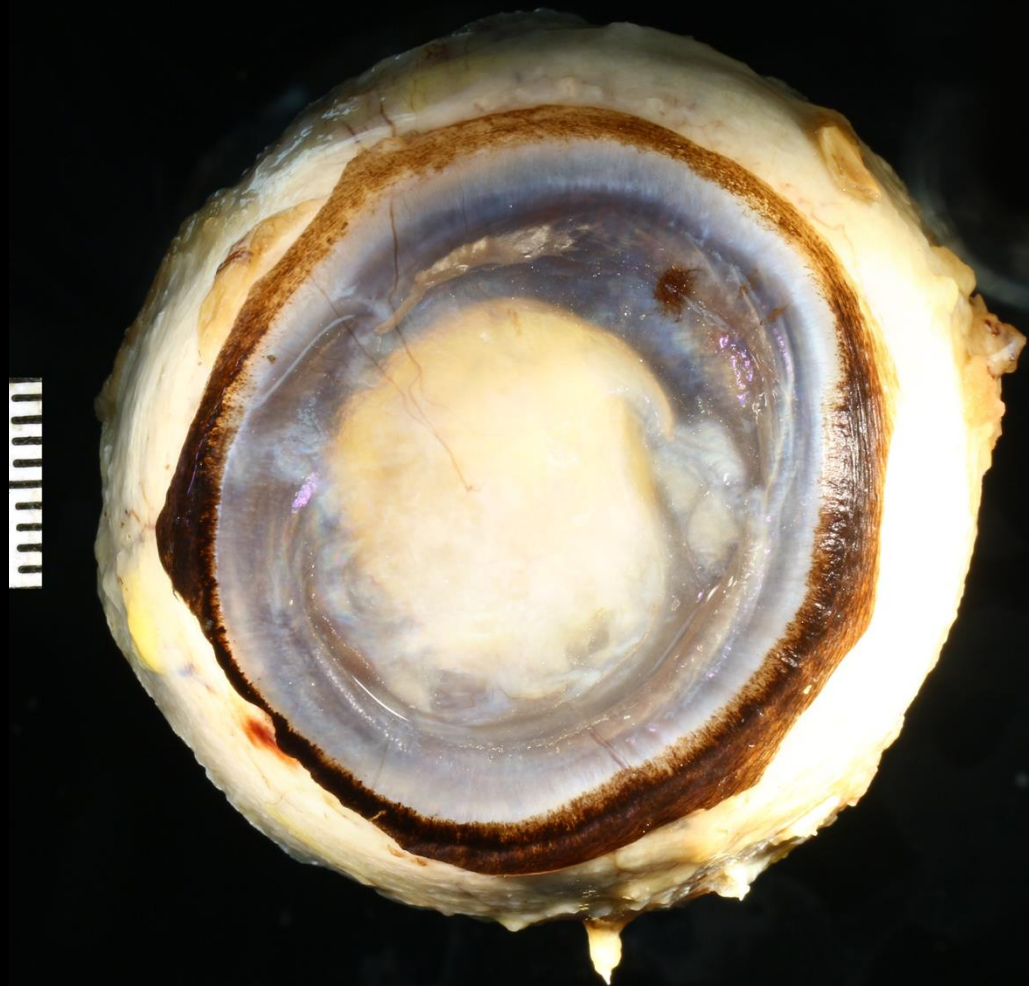


OS: Anterior stromal remodeling



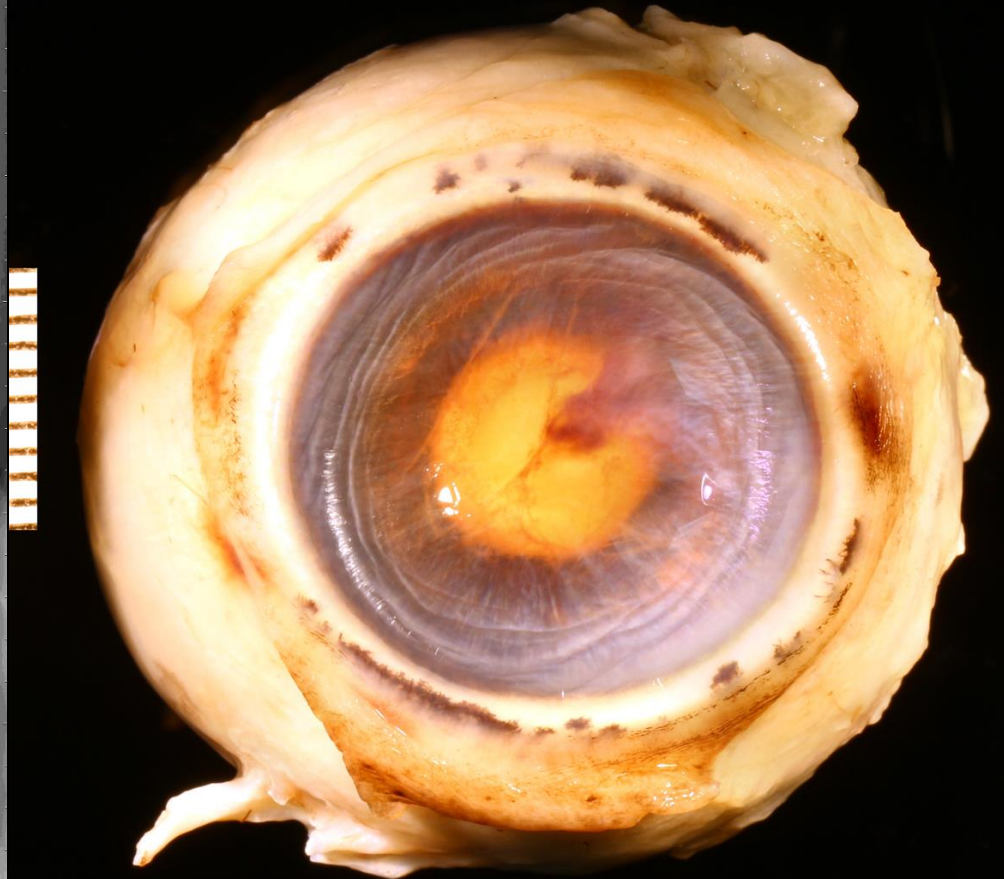
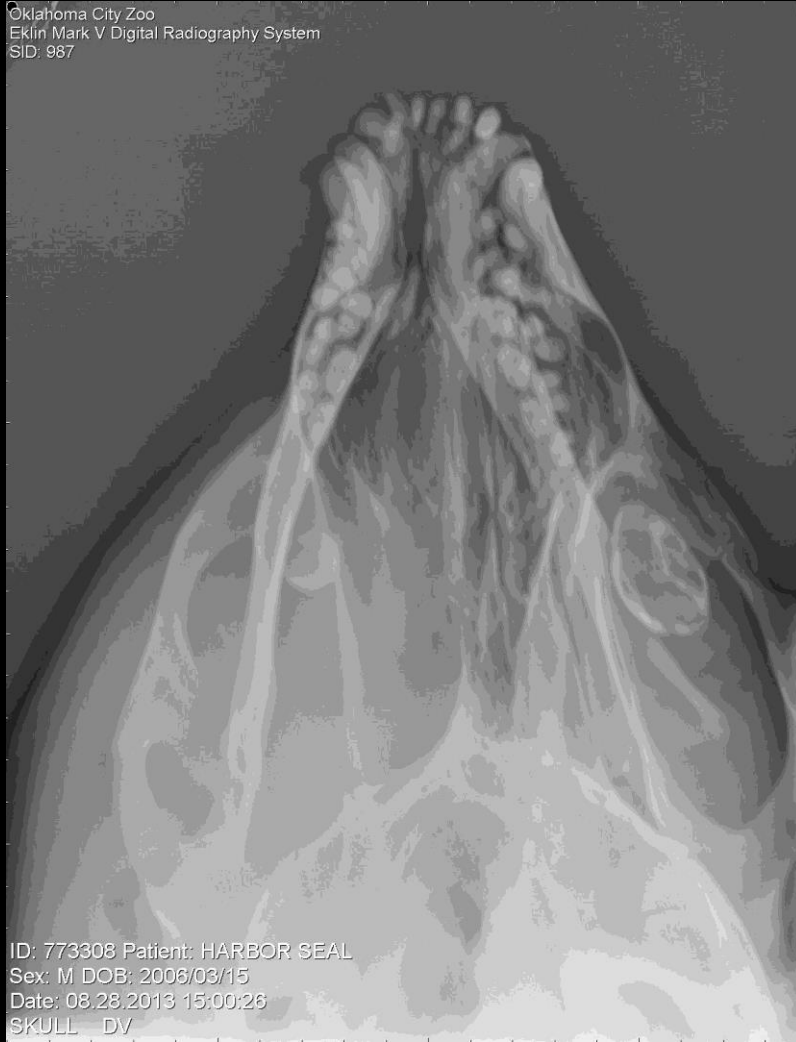
OD: Epithelial dysplasia and non-lamellar collagen

Amyloid Keratopathy



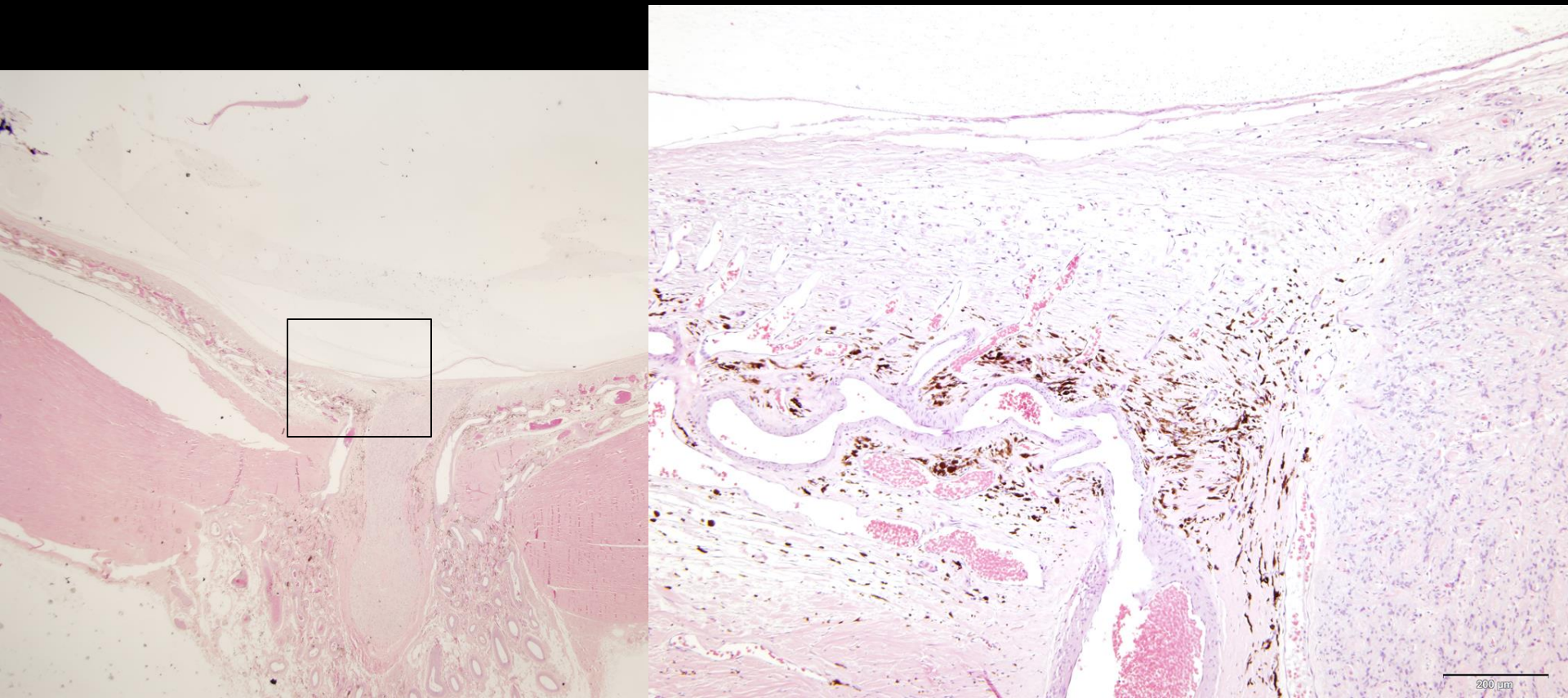
7 year-old male Harbor Seal

Born blind to a mother with Domoic acid exposure

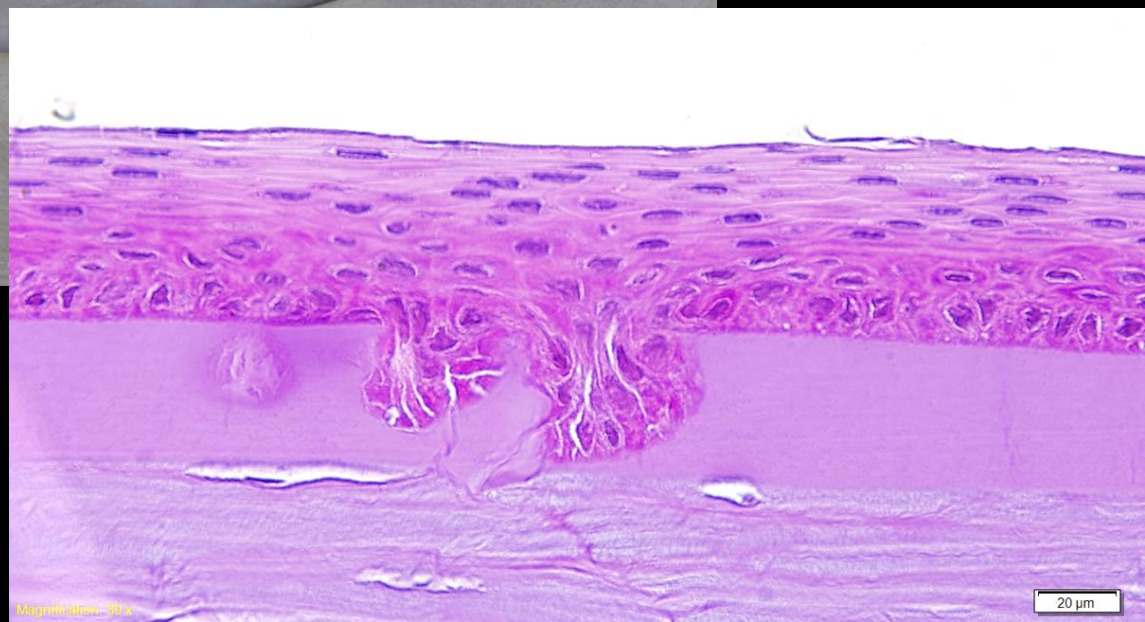
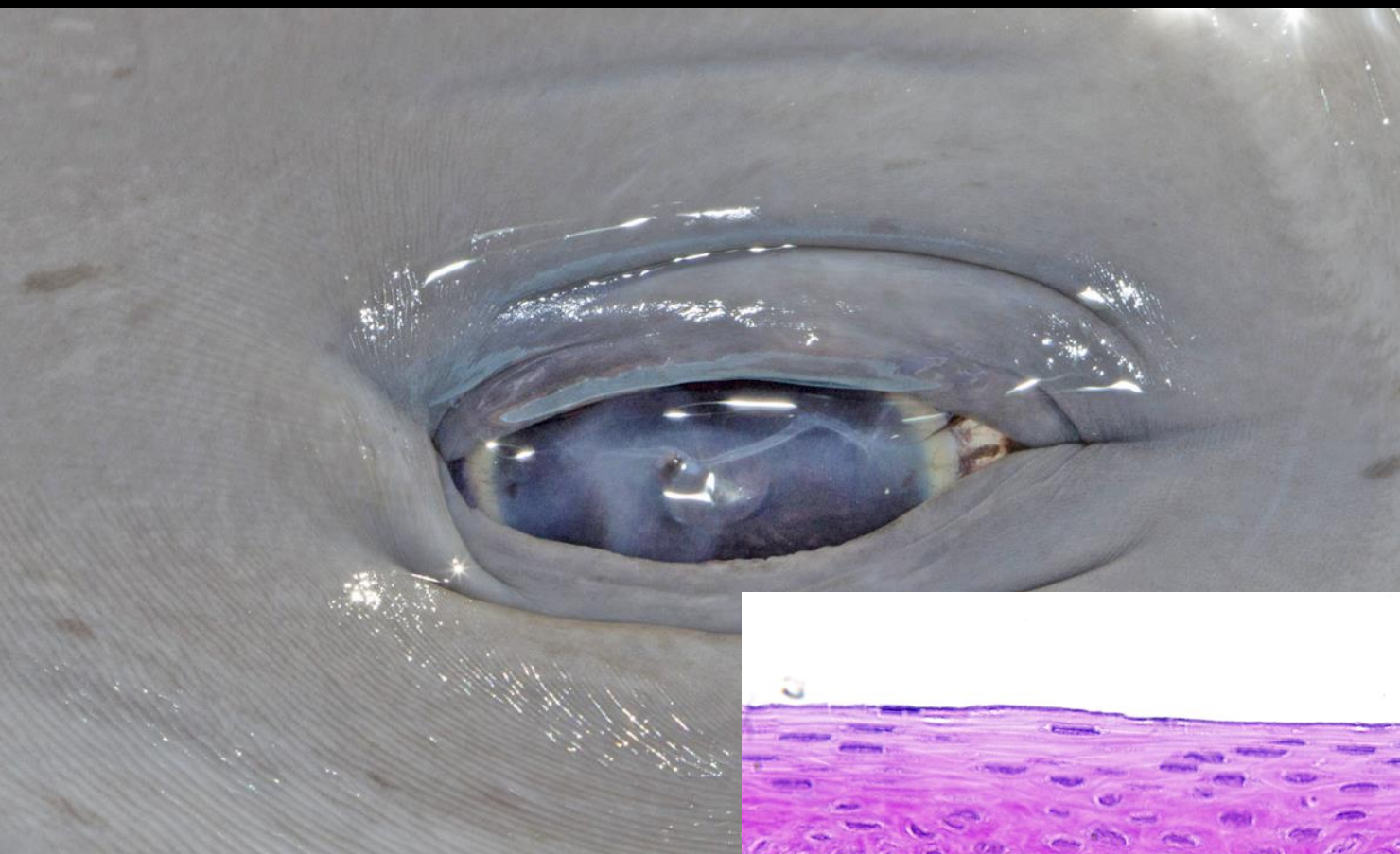


7 year-old male Harbor Seal

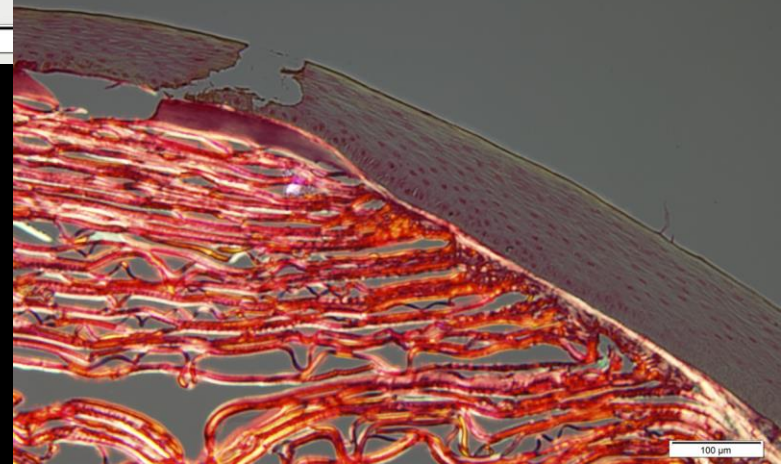
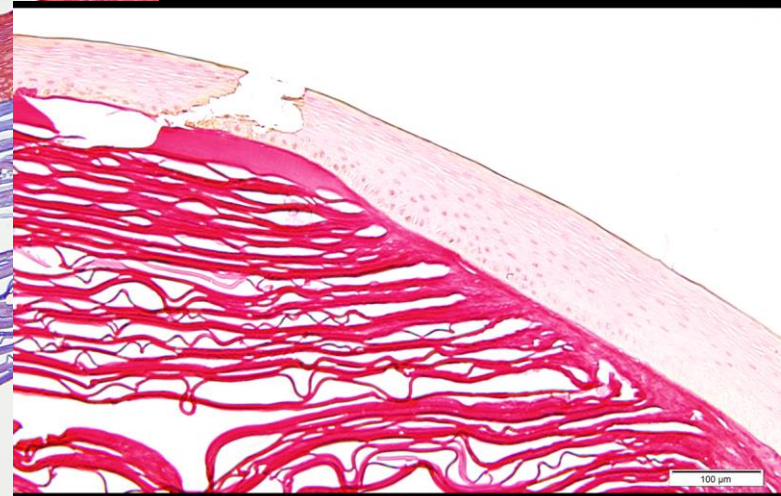
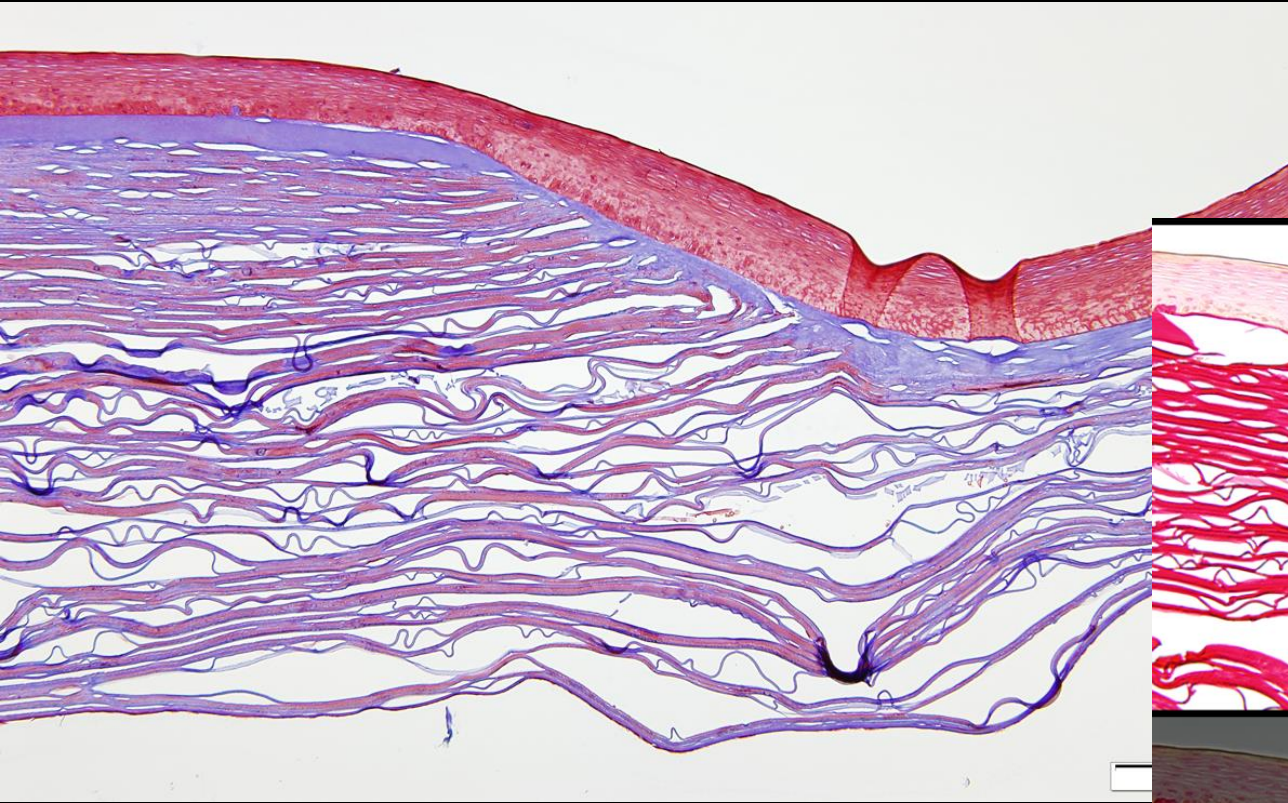Born blind to a mother with Domoic acid exposure



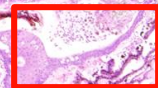
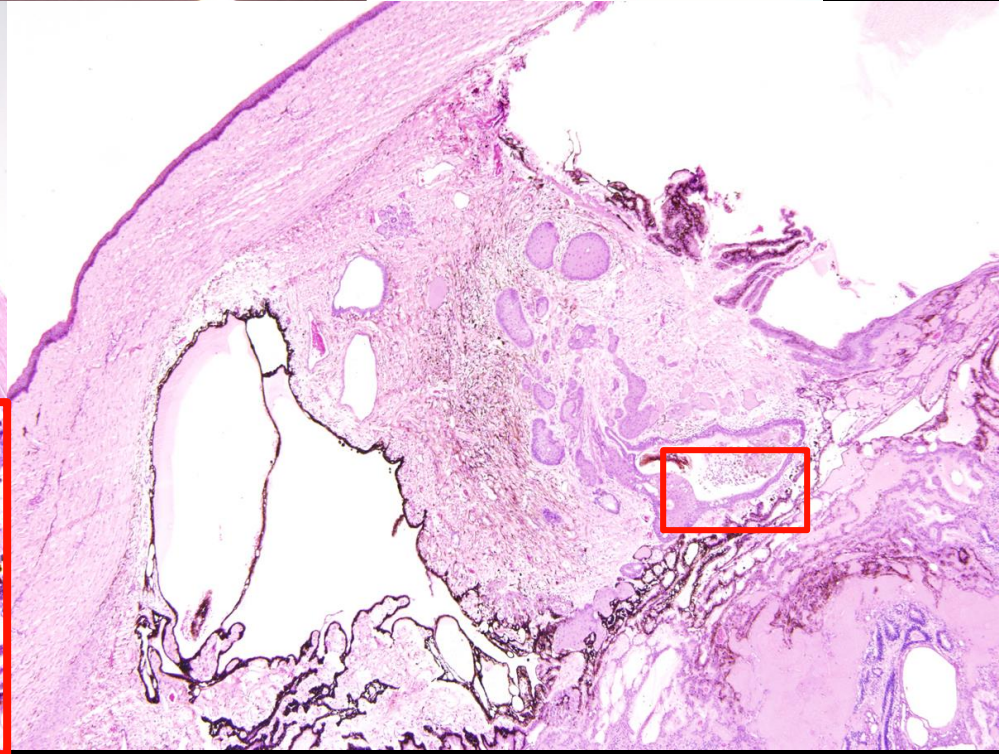
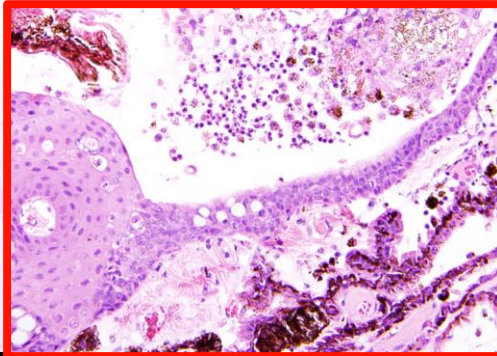
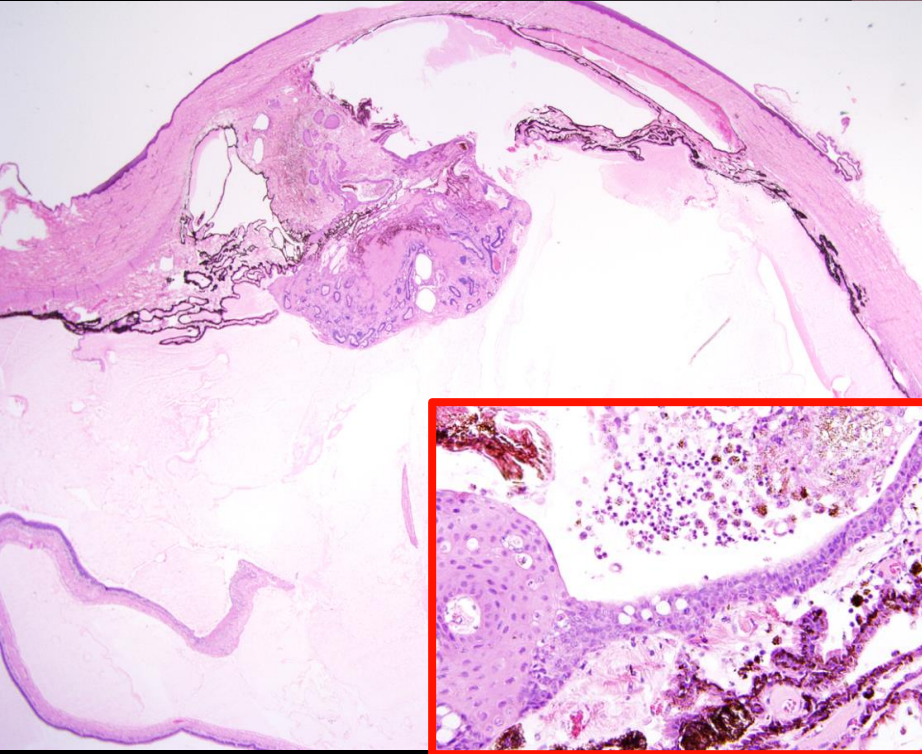
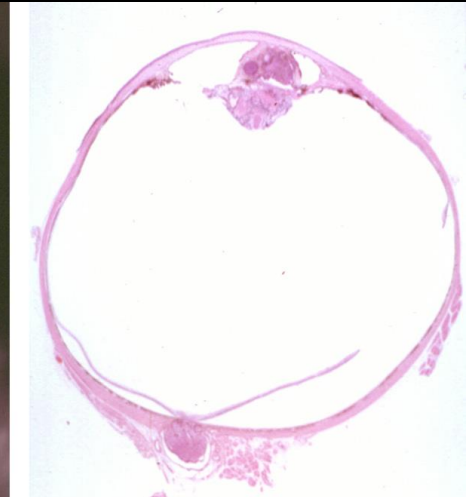
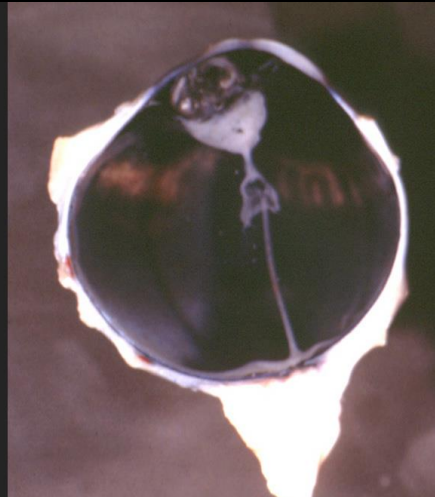
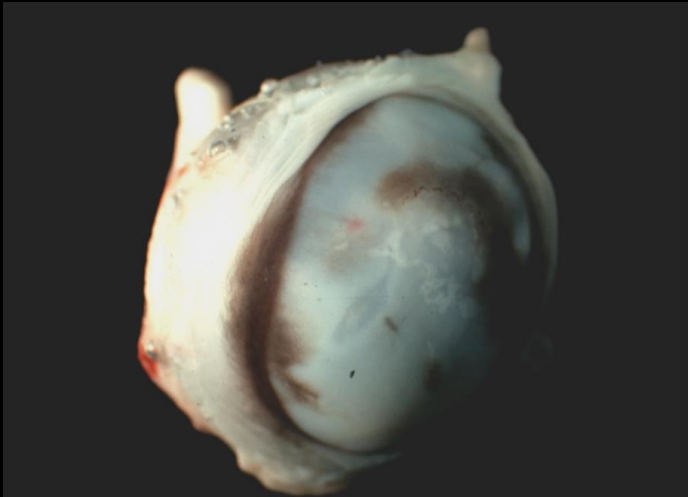
Cetacean Horizontal Keratopathy



Cetacean Horizontal Keratopathy


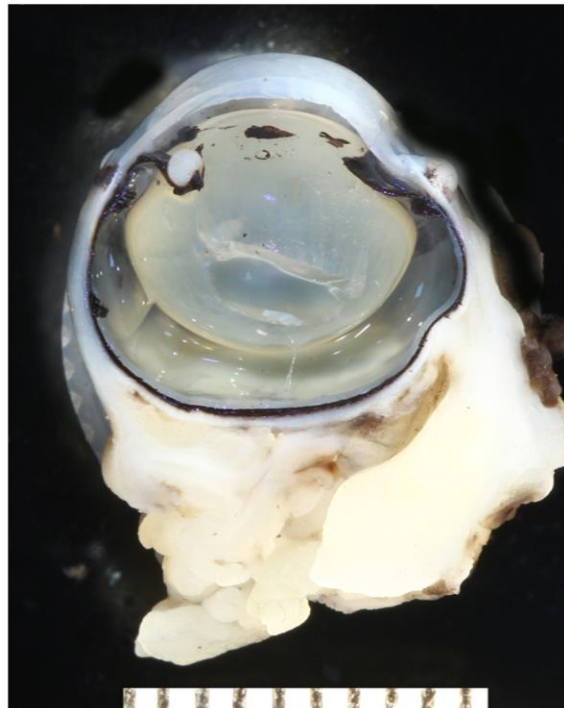
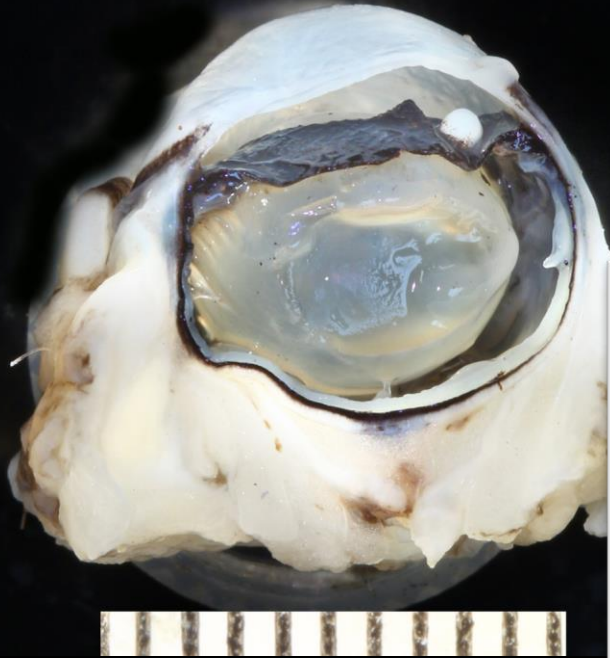


Microphthalmos in White-tailed Deer



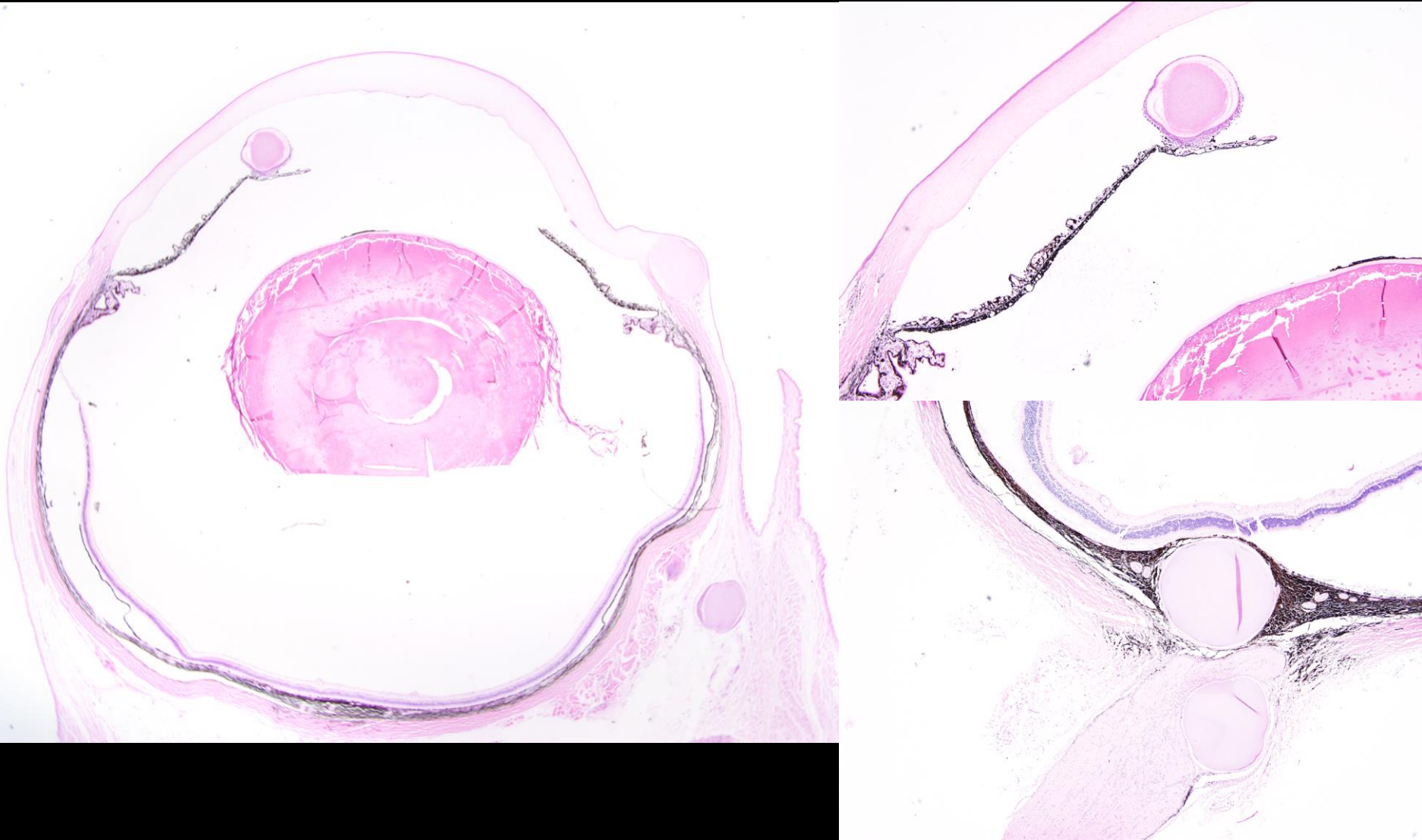
Virginia Opossum

Besnoitia darlingi

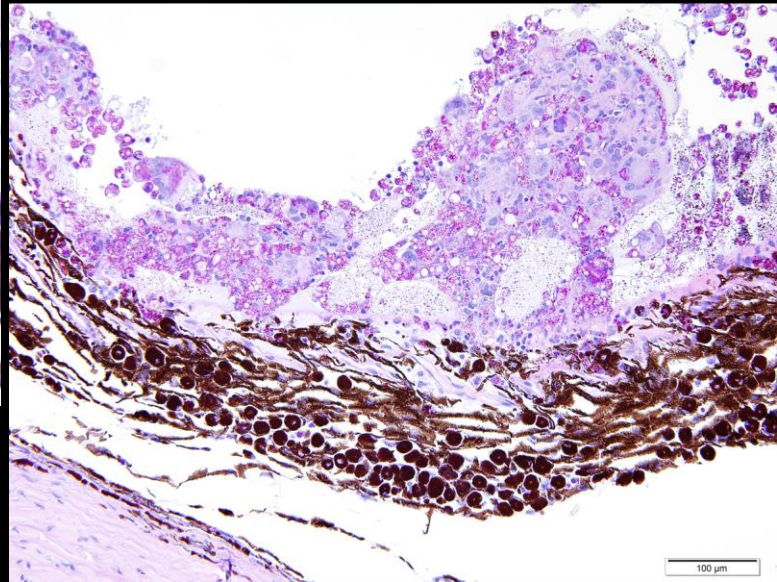
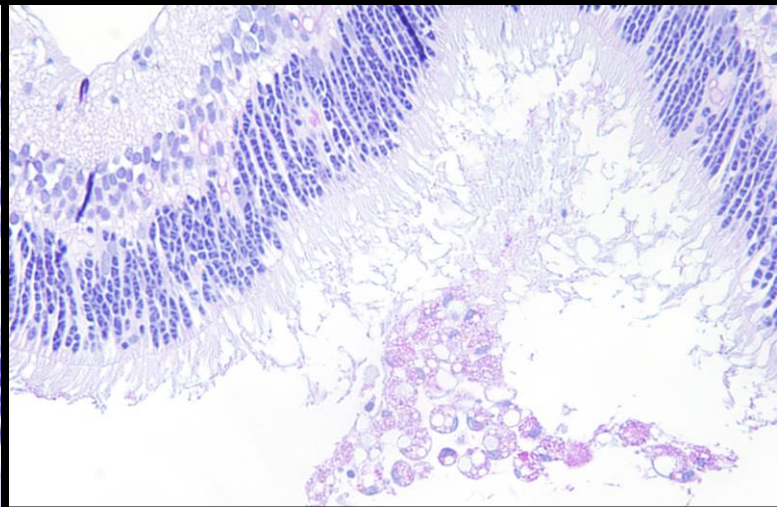
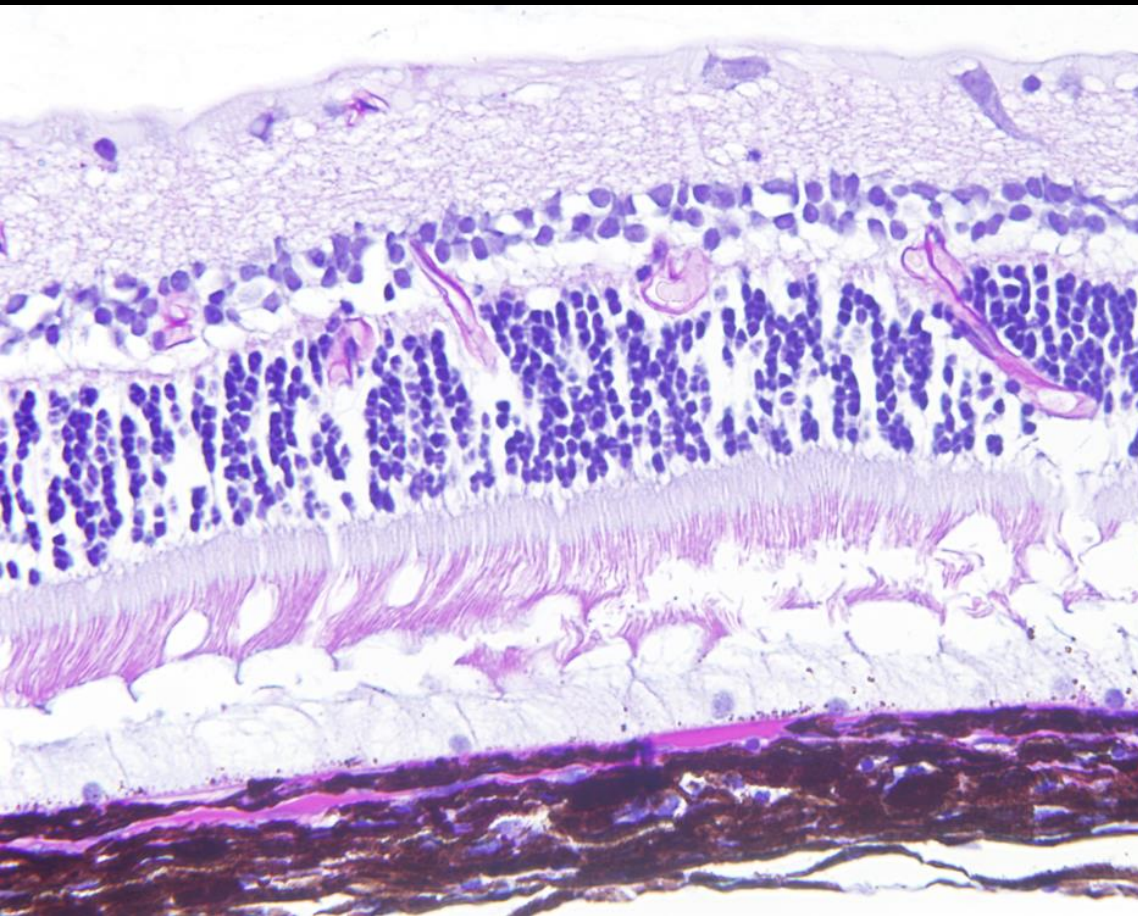


Virginia Opossum

Besnoitia darlingi



Virginia Opossum Retinal Tapetum



Retinal Lipofuscinosis

